

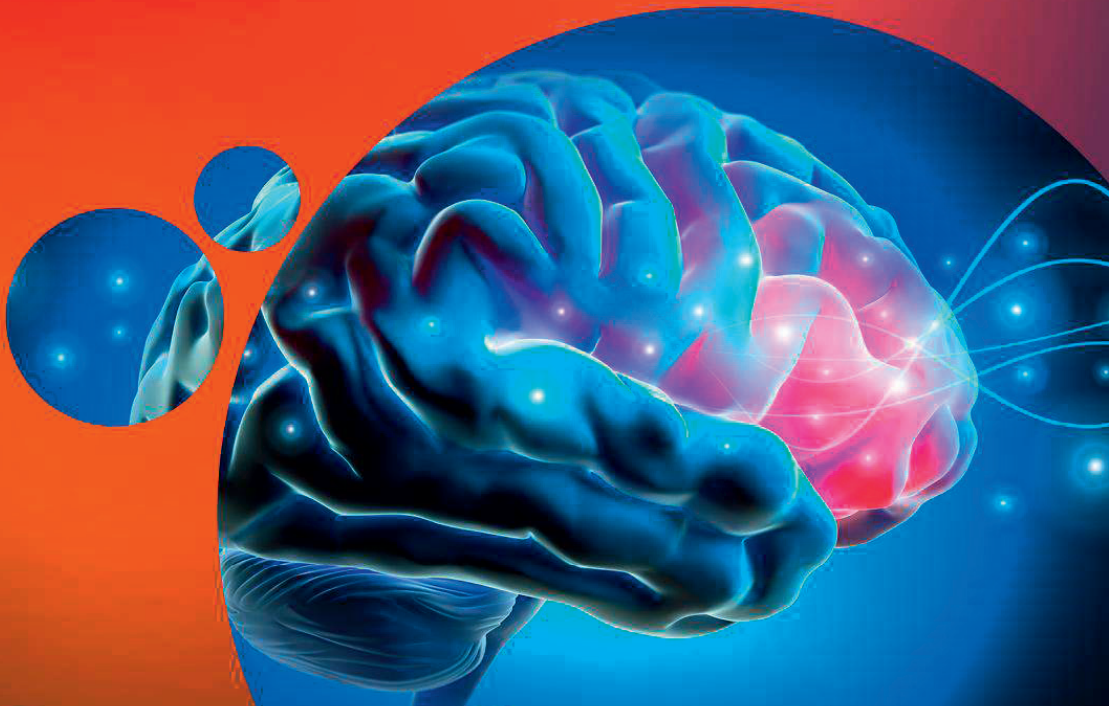Abstracts from the 17th World Congress on Controversies in Neurology,  
March 23-25, 2023, in Dubrovnik, Croatia



The 17<sup>th</sup> World Congress on  
**CONTROVERSIES IN NEUROLOGY**

March 23-25, 2023 | Dubrovnik, Croatia

**BOOK OF ABSTRACTS**



✉ [cony@comtecint.com](mailto:cony@comtecint.com) 🌐 [cony.comtecmed.com](http://cony.comtecmed.com)



## CONTENTS

Alzheimer's Disease and Dementia	3
Amyotrophic Lateral Sclerosis (ALS)	7
Epilepsy	9
Headache	19
Multiple Sclerosis	25
Neurodegenerative Diseases	34
Neuroimmunology	39
Neuromyelitis Optica Spectrum Diseases (NMOSD)	45
Other	49
Parkinson's Disease	62
Stroke	68



## **Alzheimer's Disease and Dementia**

## IS THE HEAD TURNING SIGN IN NON-NEUROLOGICAL AMBULANCES SENSITIVE FOR UNRECOGNISED EARLY COGNITIVE IMPAIRMENT?

**J. Dragičević**, S. Popović - Kostić, R. Raičević, M. Nikolić, M. Vučić, K. Iklozan, M. Danilović  
*Clinic of Neurology, Medical Military Academy, Serbia*

Head turning sign is phenomenon which is observed in cognitive ambulances in population with cognitive impairment and dementia. Yet, turning the head back to the caregiver for help is frequently seen in other ambulances in adult population without confirmed dementia.

We have observed adult patients who came accompanied by a family member or caregiver to a regular examination in intern medicine ambulance. None of the patients in this research have had previous neurological disorders and did not perform neurocognitive assessment earlier. We have requested from intern medicine physician to take note if the patient turns their head to their caregiver and to note if they have memory complains and then to refer the patient for neurocognitive testing. For this purpose, we have performed Montreal Cognitive Assessment on all patient who came to intern medicine doctor with their family member to determine cognitive impairment.

In this cohort we have confirmed that head turning sign is sensitive for early diagnosis of mild to moderate cognitive impairment and that can be easily observed in ambulances by other physician. Head turning sign also showed high correlation with patient personal remarks on some cognitive decline when physician asked about cognition.

Due to the increased incidence of cognitive decline in this research, this is valuable observation for non-neurology physicians because it is easy-to-apply and any physician can refer the patient for cognitive testing when he notice this sign. This can be helpful in identification of early cognitive impairment before patient developed difficulties in daily functioning.

## POTENTIAL PERIODONTAL MICROBE EFFECT ON ENDOTHELIAL TRANSCRIPTOME CHANGES IN PATIENTS WITH ALZHEIMER'S DISEASE

**Kamelija Horvatović**<sup>1</sup>, A Gelemanović<sup>2</sup>  
<sup>1</sup>*Molecular Biology, Faculty of Science, University of Zagreb, Croatia*  
<sup>2</sup>*Bioinformatics Department, Mediterranean Institute for Life Sciences, Croatia*

Introduction: Among various familiar etiopathology of Alzheimer's disease (AD), periodontitis is one of the most recent factors suspected to be affecting the onset of this disorder. This in silico study is testing whether the transcriptomic changes in endothelial cells (EC) induced by common periodontal pathogens such as *Fusobacterium nucleatum* (FN) or *Porphyromonas gingivalis* (PG) match changes detected in the EC of AD patients.

Methods: RNA-seq datasets GSE222136 and GSE125050 were acquired from the NCBI GEO database. Differentially expressed genes (DEGs) between different pathologies (FN, PG or AD) and untreated or healthy controls were identified following the DESeq2 pipeline, while the weighted gene co-expression network analysis (WGCNA) pipeline was used to identify highly correlated gene modules. Functional enrichment analysis was performed on DEGs and modules of interest.

Results: In total 15 gene modules were identified of which six modules with 89 key genes were significantly correlated with PG treatment, and four modules with 352 key genes with FN treatment, with most notable change being interferon signaling. 553 and 834 DEGs were identified in PG- and FN-treated ECs, respectively, while 1384 were significantly altered in ECs of AD patients. After comparing all the results, MIRHG1, SLC24A40, and ABHD13 were detected as shared significantly upregulated DEGs in all three pathologies indicating altered RNA interference mechanisms, affected ion channels, and cell adhesion.

Conclusions: This integrated study identified several potential gene candidates of underlying microbe-driven pathological changes in EC physiology that might be key players in AD onset and/or progression.

**EFFICACY OF DUAL THERAPY WITH CHOLINOMIMETIC AND NMDA ANTAGONIST MEDICATIONS IN PATIENTS WITH VASCULAR DEMENTIA COMPARED TO ALZHEIMER'S DEMENTIA**

**O. Koniashvili**

*Department of Neurology, Central Republic Hospital, Named After Acad. N.Kipshidze., Georgia*

**Introduction:** Vascular dementia (VaD) and Alzheimer's disease (AD) are the two most common causes of dementia overall. While they share some clinical features, key eliciting pathological events are different, and so does the therapeutic response to specific medications. The presented study aimed to compare the progression of cognitive deterioration in patients with AD and VaD while being treated with cholinomimetic and NMDA antagonists.

**Methods:** Histories of 100 patients were selected and analyzed retrospectively. Cognitive functions were assessed using the MoCA test in the outpatient setting. The observational period was determined by the researchers to be 3 years.

**Results:** The mean age of 50 patients diagnosed with AD was 71.4 years and 73 years for the remaining 50 patients with VaD. The mean MoCA score for the patients with AD at the initial consultation was 12.4 (SD +/- 3.5), and the same value for VaD - 10.1 (SD +/- 6.1), at the end of 1st, the 2nd, and 3rd years - 12.2 (SD=4.1), 12 (SD=4.5), 10.3 (SD=3.2) for AD, and 9.5 (SD=5.5), 8 (SD=4.3), 6.2 (SD=7.1) for VaD respectively.

**Conclusion:** The relative decline of the MoCA test for VaD was 3 times more prominent during 1st year, 5.25 during 2nd year, and 1.85 during 3rd year compared to AD, indicating that the patients with moderate to severe AD remained relatively unchanged in terms of cognitive decline, while the latter was steeper for VaD. This underlies the need to develop new strategies aimed at cognitive deterioration for patients with VaD.

**COOKING AS AN ACTIVITY OF DAILY LIVING IN SUBJECTS WITH NORMAL COGNITION, MILD COGNITIVE IMPAIRMENT, AND DEMENTIA DUE TO ALZHEIMER'S DISEASE**

**Vuk Milošević<sup>1,2</sup>**, Marina Malobabić<sup>1</sup>, Eva Antić<sup>1</sup>, Radomir Damjanović<sup>1</sup>, Jelena Bašić<sup>2</sup>

*<sup>1</sup>Clinic of Neurology, University Clinical Center Niš, Serbia*

*<sup>2</sup>Faculty of Medicine, University of Niš, Serbia*

**Introduction:** Cooking is one of the instrumental activities of daily living (IADL) that is universally present in all cultures. There are differences between the sexes in performing this activity. The aim of this study is to analyze cooking activities in patients with normal cognition, mild cognitive impairment (MCI), and dementia.

**Method:** Our study includes 160 patients (92 females) with memory complaints divided into three diagnostic groups: normal cognition/subjective cognitive impairment (71 subjects), mild cognitive impairment (36 patients), and dementia due to Alzheimer's disease (53 patients). Patients were diagnosed and assessed at the outpatient department of the Clinic of Neurology – University Clinical Center Niš, Serbia. Cooking activities were analyzed using the Amsterdam-IADL Questionnaire (A-IADL-Q), and the Mini-Mental State Examination (MMSE) test measured cognitive status. Statistical differences between groups were analyzed by the Chi-squared test.

**Results:** The cooking activity was performed by 90.2% of female and 25.6% of male subjects (p0.01). In the group with normal cognition, cooking was performed by 94.7% of female and 45.5% of male patients. In the group of patients with MCI, cooking was executed by 85.7% of female and 6.7% of male patients (p0.01), while in the group of patients with dementia, cooking was performed by 87.9% of females and 10% of males (p0.05). The degree of difficulty in performing this activity was analyzed in each diagnostic group.

**Conclusion:** Cooking activity in the Serbian sample of patients with memory complaints represents an indicator of cognitive decline in male patients.

### WHAT HAS CANCER TAUGHT US ABOUT ALZHEIMER'S DISEASE-NEW INSIGHTS AND POTENTIAL APPLICATION OF microRNA-101

Isidora Rovčanin Dragović<sup>1</sup>, N. Popović<sup>1</sup>, M. Ždravević<sup>1</sup>, Lj. Radulović<sup>2</sup>, Lj. Vučković<sup>2</sup>, A. Tullo<sup>3</sup>, J. Raonić<sup>2</sup>, B. Vukčević<sup>2</sup>, T. Vuković<sup>2</sup>, F. Marzano<sup>3</sup>, N. Guaragnella<sup>4</sup>, S. Giannattasio<sup>3</sup>, M. Radunović<sup>1</sup>

<sup>1</sup>University of Montenegro, Faculty of Medicine, Montenegro

<sup>2</sup>Clinical Center of Montenegro, Clinic for Neurology, Montenegro

<sup>3</sup>Institute of Biomembranes, Bioenergetics and Molecular Biotechnologies, CNR, Italy

<sup>4</sup>Department of Biosciences, Biotechnologies and Environment, University of Bari "Aldo Moro", Italy

To explore molecular basis of inverse incidences of Alzheimer's Disease (AD) and colorectal cancer (CRC), expression levels of circulatory microRNAs (miRs) deregulated in both diseases, were determined in the AD (n=12), cognitively unimpaired CRC (n=15) and control-CTRL (n=18) groups.

In agreement with the inverse relationship between these diseases, miR-101 was significantly down-regulated in CRC compared to AD group (p0.05). Although there were no significant differences compared to control subjects, mean expression values of miR-101 demonstrated opposite trends for AD and CRC in respect to CTRL group (AD-1.569, CTRL-1.171 and CRC-0.8340). In addition, we found that miR-101 expression levels showed decreasing trend in advanced AD cases (mean=1.354), compared to those in early disease stages (mean=1.722). Consequently, no significant difference in miR-101 regulation between advanced AD and CRC patients was found.

MiR-101 negatively regulates amyloid-beta precursor protein (APP) metabolism, therefore, its

down-regulation, mainly found in AD, is understood as a disease-contributing factor. However, up-regulating trend of miR-101 in early AD and its decline with disease progression detected in our study, suggests that miR-101 might act within the negative feedback mechanism, related to APP metabolism. Such a regulatory circuit has been already shown for amyloid proteins and other microRNA in AD and miR-101 in cancer.

Given that miR-101 potentially reflects progression of amyloid accumulation, it could serve to monitor the effects of aducanumab-amyloid lowering therapy, indicated in early AD population.

Eventually, considering miR-101 oncosuppressive role, potentially increased miR-101 expression in long-lasting preclinical and early AD, might protect AD patients from cancer.

### POTENTIAL NEUROPROTECTIVE EFFECT OF NICOTINAMIDE, A PARP INHIBITOR AGAINST STREPTOZOTOCIN-INDUCED EXPERIMENTAL DEMENTIA OF ALZHEIMER'S TYPE IN RATS

Piyush Vatsha, Madhu Kaundal, Rahul Deshmukh  
Department of Pharmacology, Maharaja Ranjit Singh Punjab Technical University, India

Dysregulation in PARP activity has been considered to play important role in the Neurodegenerative process associated with various CNS disorders. In the present study, we have investigated the therapeutic potential of PARP inhibition by nicotinamide against streptozotocin (STZ) induced neurocognitive deficit and biochemical abnormalities in rats. STZ was administered ICV (3mg/kg) bilaterally on 1-day and 3-day in Wistar rats. for one week following 1st STZ infusion up to the 21st day. Morris water maze and object recognition tasks were used to assess memory and Learning.



## **Amyotrophic Lateral Sclerosis (ALS)**

### **CAN BIOINFORMATIC VARIANT ANALYSIS HELP DISTINGUISH PATHOGENIC OPTN MUTATIONS IN ALS AND GLAUCOMA?**

**Toni Franjkić<sup>1</sup>**, Benedetta Leoni<sup>2</sup>, Gordana Apic<sup>2</sup>, Rob B. Russell<sup>3</sup>, Ivana Munitic<sup>4</sup>

<sup>1</sup>*Department of Biotechnology, Metisox, Cambridge, UK and University of Rijeka, Croatia*

<sup>2</sup>*Department of Biotechnology, Metisox, Cambridge, UK, UK*

<sup>3</sup>*Department of Biotechnology, University of Heidelberg, Cell Networks, Germany*

<sup>4</sup>*Department of Biotechnology, University of Rijeka, Croatia*

The OPTN gene encodes for optineurin, a multi-functional protein whose mutations are linked with two dissimilar neurodegenerative diseases - amyotrophic lateral sclerosis (ALS) and glaucoma. Its exact role of disease pathogenesis is still unclear. Here we compared optineurin variants present in ALS and glaucoma with naturally occurring variants through different in silico programs, and analyzed how its mutations would affect optineurin protein interactions with its key partners by AlphaFold2. The consensus on optineurin protein domains was made by

using UniProt and InterPro databases, complemented by expert literature curation. Up-to-date list of optineurin variants was assembled from UniProt, OMIM, ClinVar and gnomAD databases, and relevant literature. We show that optineurin variants in ALS and glaucoma predominantly affect coiled-coil 1 and zinc finger domains. The pathogenicity of optineurin missense mutations by PolyPhen-2, SIFT, SNP3D, Mutation Assessor, PANTHER, SNAP2, FATHMM, Meta-SNP, Predict-SNP and Align GVGD program was consistent in assigning Q467P, E478G, K557T, D564H and L568S as damaging protein changes present in ALS, whereas there were no common damaging changes in glaucoma. Eight different species representing major vertebrate genera were aligned to analyze the impact of optineurin conservation on the mutation occurrence. Species alignment showed that each of the five common pathogenic optineurin protein changes present in ALS mapped to the fully conserved regions of the optineurin protein, suggesting importance of protein conservation through evolution. These findings could help direct future experimental procedures for studying optineurin function in neurodegenerative diseases.





## Epilepsy

### IMPAIRMENTS OF ATTENTION AND EXECUTIVE FUNCTIONS IN PATIENTS WITH TEMPORAL LOBE EPILEPSY (TLE)

A. Bala<sup>1</sup>, A. Rysz<sup>2</sup>, A. Marchel<sup>2</sup>

<sup>1</sup>*Faculty of Psychology, University of Warsaw, Poland*

<sup>2</sup>*Department of Neurosurgery, Medical University of Warsaw, Poland*

**Objective:** Epilepsy is a chronic neurological disorder characterized by a predisposition to recurrent epileptic seizures that can affect all spheres of patients' lives, including their cognitive functioning. TLE is the most common type of focal epilepsy. In recent years, studies of attention and executive functions in patients with TLE have gained increasing interest, taking into account the effects of seizures on the entire brain network, which was also the aim of this study.

**Participants and Methods:** Twenty-seven patients with TLE and twenty-seven demographically matched healthy volunteers were examined with a set of neuropsychological tests (MoCA, CTT, Symbol Span-WMS-IV, Visual Elevator-TEA, TOL, VST, WCST) to assess general cognitive functioning, attention and executive function.

**Results:** Compared with controls, TLE patients exhibited significantly lower scores in the MoCA test ( $p=0.000$ ) and needed significantly more time ( $p=0.000$ ) in CTT-2. Moreover, differences were also found in the Symbol Span scores ( $p=0.002$ ) and Visual Elevator accuracy scores ( $p=0.009$ ) and also in almost all WCST and TOL indicators. A negative correlation was found between the time of suffering from epilepsy and the results of Symbol Span ( $p=0.015$ ) and Visual Elevator ( $p=0.047$ ). Additionally, age of epilepsy onset positively correlated with the number of errors in CTT-2 ( $p=0.009$ ). In contrast, the average number of seizures had no clear effect on the tests results.

**Conclusions:** Clinicians with TLE exhibit wide ranges of executive and attention deficits. Physicians should take these impairments into account to improve communication with patients with epilepsy.

### AWAKE SURGERY WITH INTRAOPERATIVE BRAIN MAPPING HELPS TO LOCATE AND SPARE BRAIN AREAS CRITICAL TO MUSICAL ABILITIES - A CASE STUDY OF A PIANIST WITH EPILEPSY

Aleksandra Bala<sup>1</sup>, A. Olejnik<sup>1</sup>, T. Dziedzic<sup>2</sup>, A. Marchel<sup>2</sup>

<sup>1</sup>*Faculty of Psychology, University of Warsaw, Poland*

<sup>2</sup>*Department of Neurosurgery, Medical University of Warsaw, Poland*

Awake craniotomies with intraoperative brain mapping are increasingly used because they improve the safety of a surgery. Neurosurgeon stimulates the individual areas of the brain and the conscious patient performs various tasks following the neuropsychologist's instructions. This is to determine which areas of the brain are crucial for individual functions, to spare them. Most often, this type of examination is used to assess the location of language and motor functions, but it is increasingly used to determine the location of other functions as well. This study evaluated the location of brain areas responsible for musical abilities.

We present the case of a 38-year-old pianist who reported to the hospital because of the several episodes of epileptic seizures, in the form of speech disorders and auditory paresthesia. MRI revealed a supratentorial cavernoma in the temporal region of the left hemisphere.

In the intraoperative examination, cortical and subcortical structures were mapped for language functions and musical abilities (reading notes and playing the piano). Stimulation of the posterior part of the superior temporal gyrus and supramarginal gyrus has been shown to cause note reading disturbances (separate from words and numbers) and piano note and memory disturbances (separate from motor disturbances and hand apraxia).

Stimulation of the specific brain areas can disturb the whole network responsible for high-level cognitive performance, and thus show which areas of the brain are crucial for the implementation of complex processes, such as playing instruments. This case report shows that musicians may benefit from awake craniotomy procedures.

**INSULAR EPILEPSY OR SOMETHING ELSE?****Boban Bisevac**<sup>1</sup>, S. Lukic<sup>1</sup>, V. Stokanovic<sup>2</sup><sup>1</sup>*Clinic of Neurology, University Clinical Center Nis, Serbia*<sup>2</sup>*Department of Radiology, University Clinical Center Nis, Serbia*

Patient, age 23, has suffered different health issues for a few years. At first there were mood changes in the form of depression, anxiety. A psychiatrist diagnosed the patient with depression. However, there were no improvements to patient's condition even after the psychiatric therapy. A few months later the patient began to feel sensitive manifestations in the form of tingling and pain in one half and later in both halves of the body. After the neurosurgical examination, further analyses had been done including NMR of the neck and lumbar part of the spine which were all normal. Although the patient was examined by different medical specialist (neurologist, psychiatrist, neurosurgeon) and treated with different therapies there were no significant improvements in the patient's health condition. The patient developed new symptoms such as contractions and myospasm of the throat, which caused swallowing and speaking difficulties followed by an unpleasant feeling in the mouth during the past six months. NMR examination showed a focal cortical dysplasia in the right insular cortex while EEG examination showed the right parietal-temporal focal electrocortical dysfunction. Therefore, the patient was given an antiepileptic medicine, Lacosamide. The patient's health condition has improved after a month of the Lacosamide consumption.

Based on the conducted analyses and examinations we can conclude that the patient is diagnosed with insular epilepsy. Seizures with specific characteristics, including unpleasant somatosensory feelings, laryngeal constriction, or dysarthric symptoms are the most important manifestations of insular pathology.

**EFFICACY AND SAFETY FOLLOWING TWO OR MORE YEARS OF VAGUS NERVE STIMULATION (VNS THERAPY) IN PEDIATRIC PATIENTS WITH DRUG-RESISTANT EPILEPSY ENROLLED IN A RUSSIAN VNS REGISTRY****Anna Feygina**<sup>1</sup>, Y. Koshelyaevskaya<sup>2</sup>, M. Dibue<sup>1</sup>, K. Voronkova<sup>3</sup>, M. Klochkov<sup>4</sup>, N. Koroleva<sup>5</sup>, S. Ivanov<sup>6</sup>, E. Bolshakova<sup>7</sup>, E. Fatykhova<sup>8</sup><sup>1</sup>*Medical Affairs International, Neuromodulation, LivaNova PLC, UK*<sup>2</sup>*Department of Biostatistics, Regional United System of Medical Informatization, LLC, Russia*<sup>3</sup>*Faculty of Additional Professional Education, Pirogov Russian National Research Medical University, Russia*<sup>4</sup>*Neurology Department, V M Bekhterev National Research Medical Center for Psychiatry and Neurology of the Russian Federation Ministry of Health, Russia*<sup>5</sup>*Center for Epileptology, Neurology, and Video-EEG monitoring, N P Bechtereva Institute of the Human Brain of the Russian Academy of Sciences, Russia*<sup>6</sup>*Neurosurgery Department, Republican Children's Clinical Hospital Bashkortostan, Russia*<sup>7</sup>*Neurology Department, Voyno-Yasenetskiy Scientific and Practical Center of Specialized Medical Care for Children, Russia*<sup>8</sup>*Neurosurgery Department, Children Republican Clinical Hospital Tatarstan, Russia*

**Introduction:** Following approval in 2009 of vagus nerve stimulation (VNS Therapy) for drug-resistant epilepsy (DRE) in the Russian Federation, this is the first multicenter study across Russia to evaluate the safety and efficacy of adjunctive VNS Therapy.

**Methods:** The retrospective, observational registry included 58 pediatric patients with DRE (5-17 years old at implantation) who had  $\geq 2$  years of VNS. To ensure a robust evaluation process, changes in seizure frequency were evaluated for all seizure types as well as most disabling seizures (ie, seizures accompanied by falls, physical trauma, and/or incontinence).

**Results:** With 2 years of VNS Therapy, 37 of 49 patients experiencing the most disabling epileptic seizures (76%) had a 50% decrease in frequency of such seizures. In addition, based on the McHugh Outcome scale, VNS Therapy had a positive out-

come on both frequency and severity of all epileptic seizure types, with a 50% decrease in frequency of all epileptic seizure types noted in 37 of 58 patients (64%); and 33% of patients had a Class I outcome, including 6 patients (10%) who achieved seizure freedom. VNS Therapy also had a positive effect on the frequency of status epilepticus: 13 patients (22%) had status epilepticus prior to implantation with a mean rate of  $9.4 \pm 17.7$  events per year (range, 0-52) and after VNS Therapy, only 1 patient continued to experience status epilepticus (at 1 event per 4-6 months). Using analysis of variance, significant differences in mean pulse width ( $p=0.043$ ) and ON time ( $p=0.004$ ) were found among groups with different seizure frequency outcomes after more than 24 months following implantation. VNS Therapy had an acceptable safety profile and no adverse events leading to VNS discontinuation were reported.

**Conclusions:** The results demonstrate that VNS Therapy is being safely and effectively applied to pediatric patients in the Russian healthcare system.

#### **SEIZURE FREEDOM WITH VNS IN NEUROFIBROMATOSIS TYPE 1: A CASE REPORT**

**Asja Hodzic<sup>1</sup>**, Andreja Bujan Kovac<sup>2</sup>, Biljana Dapic Ivancic<sup>2</sup>, Amila Brkic<sup>1</sup>, Andrej Desnica<sup>3</sup>, Goran Mrak<sup>3</sup>, David Ozretic<sup>4</sup>, Zeljka Petelin Gadze<sup>2</sup>

<sup>1</sup>*Department of Internal Medicine, Tesanj General Hospital, Tesanj, Bosnia and Herzegovina*

<sup>2</sup>*Department of Neurology, University Hospital Centre Zagreb and School of Medicine, University of Zagreb, Referral Centre of the Ministry of Health of the Republic of Croatia for Epilepsy, Affiliated Partner of the ERN EpiCARE, Zagreb, Croatia*

<sup>3</sup>*Department of Neurosurgery, University Hospital Centre Zagreb and School of Medicine, University of Zagreb, Affiliated Partner of EUROCAN, Zagreb, Croatia*

<sup>4</sup>*Clinical Department for Diagnostic and Interventional Neuroradiology, University Hospital Centre Zagreb and School of Medicine, University of Zagreb, Zagreb, Croatia*

**Background:** Neurofibromatosis type 1 (NF1) is an autosomal dominantly inherited disorder characterized by multiple café-au-lait macules, Lisch nodules, axillary or inguinal freckling, neurofibromas, distinctive bone abnormalities, and optic pathway gliomas. Seizures occur in 4-7% of individuals with

NF1, mostly due to associated brain tumors or cortical malformations. Epilepsy associated with NF1 is usually well controlled with anti-epileptic drugs. However, in some pharmaco-resistant patients vagus nerve stimulation (VNS) presents a complementary treatment option.

**Case presentation:** We present a 24-year-old male patient with NF1 who had focal autonomic seizures with impaired awareness, as well as focal motor seizures with retained awareness, in addition to moderate intellectual disability. MRI abnormalities included infiltrative changes of medulla oblongata, pons and cerebellum, as well as signal intensity changes with mild compression in the apex of the temporal lobes, insular cortex, putamen and medial part of the frontal lobe, all more prominent on the right, along with right mesial temporal sclerosis. Also, increased signal intensity with signs of left hippocampal enlargement was found. Since the patient had been diagnosed with a pharmaco-resistant form of multifocal epilepsy, after an extensive pre-operative evaluation VNS implantation was performed. In the 3.5-year follow up period, complete seizure freedom was achieved.

**Conclusion:** This case illustrates that NF1 may be associated with refractory epilepsy and suggests that, in such cases, vagus nerve stimulation therapy should be considered as a treatment option for better seizure control. Further carefully designed studies are needed.

**Keywords:** Neurofibromatosis, Pharmaco-resistant epilepsy, Vagus nerve stimulation, Seizure freedom

**Declaration of patient consent:** The patient has given his consent for his images and other clinical data to be reported in this case presentation.

## THE EEG STUDY IN PATIENTS WITH CNS DYSFUNCTION USING “EEGHUB.GE” DATABASE

**Irma Khachidze**<sup>1,2</sup>, Q Aptsiauri<sup>1</sup>, M Advadze<sup>2</sup>

<sup>1</sup>*Human Psychophysiology, Beritashvili Centre of Experimental Biomedicine, Georgian National University (SEU), Georgia*

<sup>2</sup>*Medicine, Georgian National University, Georgia*

**Background:** EU Project NI4OS is funded by the European Commission's Horizon 2020 program. The first online EEG database “EEGHUB.GE” in Georgia was funded and selected as a thematic service. EEG data of patients with NS dysfunction is uploaded to the European Open Science Cloud(EOSC).

**Methods:** “EEGHUB.GE” is used to study EEG characteristics in Patients with different CNS-disorder. First study revealed EEG biomarkers in 39epileptic children aged(6-10 years) during the AED-treatment. Second Study is aimed to determine the EEG pattern to functional trials based on time and age of patients.

**Results:** The presence rhythmic monomorphic theta waves tempo-parietal region is predicting factor for seizures recurrence. The pathological EEG reaction to hyperventilation was revealed in 985, into the 3-50age groups. Three types of EEG reaction to hyperventilation were revealed of disorganization of the basic rhythm(than paroxysmal & epileptiform discharges) in all minutes. In the first minute was revealed ratio between all types of EEG and age, compare to second/third minutes.

**Conclusions:** Reduction of low-frequency waves, suppression of epileptiform EEG pattern simultaneously with clinical improvement serve as biomarker. EEG-response to functional trials is informative for scientific and clinical study. Extension of functional test is not recommendable, especially in patients with CNS-disorders and in children. EEG dataset in patients with various CNS dysfunctions have a wide range of practical/theoretical interest in fields of neuroscience, neuropharmacology, neurology.

## SLEEP QUALITY AND ITS ASSOCIATION WITH SELF-REPORTED IMPULSIVITY IN PATIENTS WITH EPILEPSY

**Sang-Ahm Lee**<sup>1</sup>, JY. Jeon<sup>2</sup>, SH. Han<sup>3</sup>, HW. Kim<sup>4</sup>, GH. Lee<sup>4</sup>, HU. Ryu<sup>5</sup>

<sup>1</sup>*Department of Neurology, Asan Medical Center, University of Ulsan College of Medicine, South Korea*

<sup>2</sup>*Department of Neurology, Kyungpook National University Chilgok Hospital, South Korea*

<sup>3</sup>*Department of Neurology, Chung-Ang University College of Medicine, South Korea*

<sup>4</sup>*Department of Neurology, Pusan National University School of Medicine, South Korea*

<sup>5</sup>*Department of Neurology, Jeonbuk National University School of Medicine, South Korea*

**Purpose:** We assessed sleep quality and its association with self-reported impulsivity in patients with epilepsy.

**Methods:** This was a cross-sectional multicenter study that used the Pittsburgh Sleep Quality Index (PSQI), the Patient Health Questionnaire-9 (PHQ-9), and the Barratt Impulsiveness Scale Version 11 (BIS-11). We performed stepwise linear regression analysis and analysis of covariance with interaction terms.

**Results:** Of the 164 subjects (62.2% men) included, 101 (61.6%) had a PSQI score 5, which indicated poor sleep quality. The drug load of antiseizure medication and the composite score of epilepsy severity were positively correlated with the PSQI score; however, these correlations did not reach significance after controlling for age, sex, psychiatric history, and PHQ-9 score. In the stepwise linear regression analysis, the PSQI score, the PHQ-9 score, and the composite score of epilepsy severity were associated with the BIS-11 score. The coefficient of determination for the model was 0.380. After adjusting for epilepsy severity and PHQ-9 score, men, but not women, showed a significant association between poor sleep quality and impulsivity. In addition, poor sleep quality tended to be associated with impulsivity in the older (aged 40 years) age group than in the younger (aged ≤40 years) age group.

**Conclusions:** More than half of patients with epilepsy have poor sleep quality; however, epilepsys-

related factors may not be independently associated with poor sleep quality. Poor sleep quality was a significant and independent correlate of self-reported impulsivity, and this relationship was more evident in men and those aged older than 40 years.

#### **IRAK-M DEFICIENCY PROMOTES M1 POLARIZATION OF MICROGLIA AND EXACERBATES SEIZURES IN EPILEPSY**

**Xiaoshan Liang**, Xiaoyu Zhu, Xiaotao Liang, YunLv Li, Weipeng Li, Wei Xie

*School of Traditional Chinese Medicine, Southern Medical University, China*

**Background:** Epilepsy is one of the most common neurological disorders. The proepileptic and antiepileptic roles of microglia in epilepsy have recently garnered significant attention. As an important pattern recognition receptor in the innate immune response, interleukin-1 receptor-associated kinase (IRAK)-M mainly express in microglia, which act as a negative regulator of TLR4 signaling pathway that mediated the anti-inflammatory effect. However, whether IRAK-M exerts its protective role in the epileptogenesis, and the molecular and cellular mechanism underlying these processes remain unknown.

**Methods:** An epilepsy mouse model induced by pilocarpine was used in this study. Real-time quantitative polymerase chain reaction (RT-qPCR) and western blot (WB) analysis were used to analyze mRNA and protein expression levels, respectively. Whole-cell voltage-clamp recordings were used to evaluate the glutamatergic synaptic transmission in hippocampal neurons. Immunofluorescence was used to show the glial cell activation and neuronal loss. The proportion of microglia was analyzed using flow cytometry.

**Results:** We firstly demonstrated that seizure dynamics influenced the expression of IRAK-M. IRAK-M knockout dramatically exacerbated seizures and pathology in epilepsy and increased the NMDAR expression, leading to the enhancement of glutamatergic synaptic transmission in hippocampal CA1 pyramidal neurons in mice. Furthermore, IRAK-M deficiency increased hippocampal neuronal loss through a possible mechanism of NMDARs-mediated excitotoxicity. IRAK-M deletion drive microglia towards M1 phenotype, which produces high levels of pro-

inflammatory cytokines and is accompanied by a visible increase in the expression of key microglia polarization-related proteins including p-STAT1, TRAF6 and SOCS1.

**Conclusions:** Our findings demonstrated that dysfunction of IRAK-M contribute to the progression of epilepsy through increasing M1 microglia polarization and glutamatergic synaptic transmission, which is possibly related to NMDARs, particularly Grin2A and Grin2B, suggesting that IRAK-M might be a novel target for the treatment of epilepsy.

#### **HIPPOCAMPAL AND ITS ADJACENT REGIONAL ATROPHY IN MESIAL TEMPORAL LOBE EPILEPSY: MANUAL VS. AUTOMATIC SEGMENTATION**

**Sung Chul Lim<sup>1</sup>**

*Department of Neurology, St. Vincent's Hospital, The Catholic University of Korea, South Korea*

**Background:** Hippocampal (HP) and its related structural (amygdala; AMG, entorhinal cortex; EC, thalamus; TH) volumetry is a widely used clinical tool for the detection and lateralization of mTLE. Traditionally, the volume of these structures is measured by manually segmenting on serial sections of a T1-weighted MRI. The manual approach requires a trained operator in a reliable and consistent manner. Automated software-based segmentation now allow us to use MRI to obtain estimates of these structural volume without requiring manual input. However, few of these studies explicitly compared automated volume estimates with the corresponding manual estimate in the same subject. In the studies in which a direct comparison of manual and automated techniques was made, an automated segmentation technique was used Freesurfer. The aim of this study is to determine if automated volumetric methods are suitable for detection of hippocampal and its adjacent regional atrophy in a mTLE cohort with unilateral hippocampal sclerosis. The outcomes of this study will help determine whether automated techniques should replace the manual technique as the standard volumetric methodology for the detection and lateralization of hippocampal atrophy in a clinical setting.

**Methods:** Volumetric MRIs were measured on 26 patients with mTLE (16 left, 10 right) and 20 age- and

gender-matched healthy controls. Volumes of hippocampus, subcortical regions (thalamus, amygdala) and entorhinal cortex were measured manually, and using the automated reconstruction software (FreeSurfer). The sensitivities of two techniques were compared by determining the effect size for average volume reduction in patients with mTLE compared to controls.

**Results:** Significant volume reduction in affected hippocampi in mTLE compared to controls was detected by manual hippocampal volume measurement ( $p=1.0 \times 10^{-6}$ , effect size 16.0%), FreeSurfer ( $p=0.05$ , effect size 5.5%) after correction for brain volume. FreeSurfer correlated reasonably with this manual segmentation on pathological HP in left ( $r=0.69$ ,  $p=0.01$ ) and right ( $r=0.63$ ,  $p=0.01$ ) mTLE patients. Contrary to previous reports, the spatial correlation between manual and automated segmentation was reduced in affected hippocampi, suggesting the accuracy of automated segmentation was increased in pathologic brains. The discriminant function analysis revealed that patients with mTLE were best distinguished from one another using a combination of its hippocampus and amygdala volumes by manual volumetry, but not by FreeSurfer.

**Conclusions:** Expert manual volumetry is more sensitive than automated methods for the detection of hippocampal atrophy associated with mTLE. Volumetric data obtained with automated segmentation of HP and AMG approximate data from manual tracings. Our data suggest that automated segmentation may suggest to be clinically useful for evaluating the nature and extent of structural damage in patients with mTLE and may increase diagnostic classification of patients. Further studies with more patients should be warranted.

## HOW TO DISTINGUISH PAROXYSMAL KINESIGENIC DYSKINESIA FROM EPILEPSY – A CASE REPORT

Vladimir Miletic<sup>1</sup>, Andreja Bujan Kovac<sup>1</sup>,

Petra Nimac Kozina<sup>1</sup>, Gordana Mustac<sup>2</sup>

Zeljka Petelin Gadze<sup>1</sup>, **Biljana Dapic Ivancic<sup>1</sup>**

<sup>1</sup>*Department of Neurology, University Hospital Centre Zagreb and School of Medicine, University of Zagreb, Referral Centre of the Ministry of Health of the Republic of Croatia for Epilepsy, Partner of the ERN EpiCARE, Croatia*

<sup>2</sup>*Department for Pediatrics, General Hospital Zadar, Croatia*

Paroxysmal dyskinesias are a group of neurological diseases characterized by intermittent episodes of involuntary movements (dystonia, chorea, ballism). It is divided into the most common type paroxysmal kinesigenic dyskinesia (PKD), paroxysmal nonkinesigenic dyskinesia, and paroxysmal exercise-induced dyskinesia. PKD is characterized by recurrent and transient episodes of involuntary movements precipitated by a sudden voluntary action. PKD is mainly an autosomal-dominant inherited condition. Proline-rich transmembrane protein 2 was the first identified causative gene in 2011, accounting for the majority of PKD patients. Even though PKD attacks are stereotypical, precipitated mainly by certain factors, and not accompanied by loss of consciousness, it is difficult to distinguish them from epileptic seizures, especially from frontal lobe epilepsy. Some patients with frontal lobe epilepsy can present with recurrent and stereotypic chorea and dystonia with disturbance of consciousness during the attack. Unlike frontal lobe epilepsy, PKD attacks have a clear kinesigenic trigger and don't have a disturbance of consciousness, which can be used to distinguish the two disorders. We present 22 years old patient with diagnosed generalized epilepsy from early childhood. Patient was with antiepileptic therapy (valproic acid) for many years seizure-free. At age 16 she started to have seizures that she described as forced involuntary movements provoked by stressful situations and antiepileptic drugs were again introduced, this time valproic acid and levetiracetam. Due to pharmacoresistance genetic testing was performed and the heterozygotic missense variant in gene PRRT2 was revealed. After this finding and prolonged video EEG monitoring, we introduced oxcarbazepine into therapy with excellent clinical response.

### MAIN ISSUES IN CREATING OF UKRANIAN REGISTER PATIENTS, WHICH HAD SURGERY TREATMENT DUE PHARMACORESISTANCE EPILEPSY

**Maryna Naboka**, Andriy Dubenko

*Department of Child Psychoneurology and Pparoxysmal Conditions, State Institution "Institute of Neurology, Psychiatry and Narcology of the National Academy of Medical Sciences of Ukraine" INPN of NAMS of Ukraine SI, Ukraine*

During analyzing the surgical treatment of epilepsy in Ukraine tendency to increasing was observed. It was impossible to assess pre-surgical evaluation, antiseizure medication before and after surgery, long-term results of treatment. We created a register of patients which were operated due pharmacoresistance.

We analyzed our difficulties. No programs in Ukraine for financial support, assistance for such projects. The period of fixation of patients began in 2021, when the COVID19 pandemic unfolded in Ukraine.

The material side of the planned register was the first conditional obstacle. After all, there are no programs in Ukraine that could provide financial assistance for such projects. Cooperation with neurosurgeons became another problem, the lack of full-fledged contact with specialists, often insufficiently coordinated work due to neurosurgeons' lack of understanding of the importance of collecting such information.

Most significant and difficult obstacle was Russia's aggression against Ukraine. This terrible event stopped the work of all structures, including the work of medical institutions. The institutions that provided medical aid completely or partially stopped their work or were reoriented to the treatment of the wounded and injured as a result of hostilities. Patients who needed surgery treatment of epilepsy were forced to cancel planned operations. Contact was lost with some patients who had already been operated on. And that's why we lost the ability to update data in the register.

Despite all the problems and difficulties described above, we continue to work on filling the register as planned in order to obtain objective data on this issue.

### PITFALLS ON THE WAY FROM PROBABLE TO DEFINITIVE DIAGNOSIS OF SELF-LIMITED EPILEPSY WITH CENTROTEMPORAL SPIKES

**Emil Vlajic**<sup>1</sup>, J. Dragicevic<sup>2</sup>

*<sup>1</sup>Neurology Department, Community Health Centre Bormedic, Serbia*

*<sup>2</sup>Neurology Clinic, Medical Military Academy, Serbia*

Three mandatory conditions define self-limited epilepsy with centrotemporal spikes (SeLECTS): characteristic semiology of the seizures, specific focal EEG findings and age-related benign outcome. When seizure semiology in pediatric populations suggests to possible of SeLECTS, the first step is to perform an EEG. If high-amplitude centrotemporal complexes of sharp and slow waves are found, the first two conditions are met and a diagnosis of SeLECTS becomes probable. Such a patient remains for follow-up and a decision is made on additional tests and possible therapy. A final diagnosis can only be made at the end of a sufficiently long follow-up, if the third condition is also met. We have evaluated 63 children with epileptic seizures and focal epileptic discharges on EEG. Follow-up and additional testing of children with probable SeLECTS revealed that 23 (36.5%) patients had some other type of epilepsy. Five patients had positive findings on brain imaging. Three of five had symptomatic epilepsy, but remaining two had typical clinical and EEG findings for SeLECTS and benign outcome. One patient developed electrical status epilepticus in slow waves sleep during follow-up. Five patients had Panayiotopoulos syndrome, two had Gastaut syndrome and two patients had Landau-Kleffner syndrome. Four patients didn't have normal neurology findings. Three had specific cognitive deficits, and three patients had atypical pattern or description of epileptic seizures. Based on our study, more attention is necessary when making a diagnosis of SeLECTS at the beginning of the follow up, due to the increased incidence of misdiagnosis.



### **H3-HISTAMINE BLOCKADE STRENGTHENED RAPAMYCYN ABOLISHING OF SEIZURES AND COMORBIDITIES IN PENTYLENETETRAZOL (PTZ)-KINDLED RATS**

**Ksenia Prybolovets**<sup>1</sup>, Olha Yehorenko<sup>1</sup>, Olesya Poshyvak<sup>2</sup>, Oleh Pinyazhko<sup>2</sup>, Leonid Godlevsky<sup>1</sup>

<sup>1</sup>*Biophysics, Informatics and Medical Equipment, Odesa National Medical University, Ukraine*

<sup>2</sup>*Danylo Halytsky Lviv National Medical University, Danylo Halytsky Lviv National Medical University, Ukraine*

The investigation aimed to investigate behavioral manifestations in PTZ-kindled rats treated with the H3 histamine receptor blocker thioperamid and rapamycin.

**Methods:** Kindling was produced in Wistar rats by three-week PTZ administration (Sigma Aldrich, USA, 35.0 mg/kg, i.p.). Treatment with rapamycin (Pfizer, USA, 0.5 mg/kg, i.p.) and thioperamid (Sigma-Aldrich, USA, 2.5 mg/kg, i.p.) was performed for ten days in fully kindled rats. Depression was investigated in the forced swimming test, and aggression was estimated as a value of threshold current intensity for inducing fights in pairs of rats on the electrode floor.

**Results:** Combined administration of rapamycin (0.5 mg/kg) and thioperamid (2.5 mg/kg) prevented generalized seizure fits in 7 out of 8 rats (P0.025). Separate administration of drugs failed to reduce seizure severity. In the Porsolt forced swimming test, immobility response in kindled rats was higher by 38.1% (P0.001) than in intact rats. After treatment with rapamycin, the immobility duration remained higher by 32.0% (P0.001) and by 25.8% (P0.05) in rats treated with thioperamid when compared with intact rats. After combined treatment the immobility duration in kindled animals was significantly shorter in comparison with kindled rats by 30.2% (P0.01) and exceeded such one in the intact rats by 12.3% (P0.05). Combined drug administration elevated the threshold of fights in kindled rats by 52.6% compared to kindled animals (P0.001) and significantly exceeded values in groups with separate drug treatment.

**Conclusions:** the synergy of antiseizure, antidepressant and antiaggressive action of rapamycin and antagonist of H3histamin receptors thioperamid is observed in PTZ-induced kindled rats.

Source of research support: Research were supported by the Ministry of Health Care of Ukraine (grant N0121U114510)

Ethical Committee Approval: The experiments were approved by the Odesa National Medical University Bioethics Committee (UBC) (approval No. 3 dated 17/03/2020) before the study.

### **THE COMORBIDITY BETWEEN MIGRAINE AND EPILEPSY IN YOUNG MEN**

**A. Voitiuk**<sup>1,2</sup>, T. Litovchenko<sup>1</sup>

<sup>1</sup>*Department of Neurology and Child Neurology, Kharkiv Medical Academy of Postgraduate Education, Ukraine*

<sup>2</sup>*Department of Neurology, Medical Centre «Neuron», Ukraine*

**Introduction:** It is known that patients with epilepsy are 2-5 times more likely to have comorbid disorders such as migraine. Epilepsy and migraine are common chronic neurological disorders presenting with paroxysmal attacks of transient cerebral dysfunction, followed by subsequent return to baseline between episodes. The migraine aura-triggered seizures are not the only option for combining migraine and epilepsy. The postictal headache and hemicrania epileptica are also isolated according to ICHD-III.

The purpose of this study is to establish the relationship between headache and epilepsy in young men.

**Materials and methods:** The study were conducted on the basis of the analysis of clinical symptoms and instrumental methods. EEG, EEG-video monitoring and MRI were used as the screening methods. The intensity of headache was assessed using a visual analogue scale (VAS).

**Results:** Analysis of the data of 80 patients showed that the migraine aura-triggered seizures were observed in 28 men (35%), hemicrania epileptica in 22 (27.5%) and postictal headache in 30 patients (37.5%). In the first type, the EEG recorded spike-slow-wave complexes mainly in the left temporal leads, in the second - bilateral continuous spike-and-slow-wave discharges, and in the third - high voltage theta activity intermingled with sharp waves over occipital region. The brain MRI showed secondary brain lesions in the temporo-parieto-occipital region with a restricted diffusion in the occipital region or enlarged sulci in the parietal region.

Conclusion: The comorbidity of migraine and epilepsy has been known for more than a century. Migraine and epilepsy are both complex brain diseases

that cause periodic seizures and impair the performance. However, these conditions require further study in young men with epilepsy.



## Headache

### LONG-TERM RECURRENCE OF PRIMARY STABBING HEADACHE AND ITS ASSOCIATION FACTORS

**Soo Hyun Cho**<sup>1</sup>, Byung-Kun Kim<sup>2</sup>

<sup>1</sup>Neurology, Uijeongbu Eulji Medical Center, Eulji University School of Medicine, South Korea

<sup>2</sup>Neurology, Nowon Eulji Medical Center, Eulji University School of Medicine, South Korea

**Background:** Primary stabbing headache (PSH) is the third most common complaint in headache clinics, following migraine and tension-type headache in Korea. Despite its high prevalence, the risk factors and long-term prognosis of PSH have not yet been studied. This study explored the recurrence rate of PSH during a two-year period following a patient's initial diagnosis and investigated the association factors leading to its recurrence.

**Methods:** Among 1,756 patients presenting with a headache who visited a single headache clinic during a select period, 106 patients with recurrent brief stabbing headaches not attributed to another disorder were recruited consecutively. We collected demographics, clinical features, and time required to enter complete remission after treatment. To evaluate long-term prognosis, we interviewed 106 patients by telephone at least two years after their first visit. Overall PSH recurrence rate and its association factors were investigated.

**Results:** A two-year follow-up interview was successfully conducted in 80 patients (median age 45, IQR 33.3–58.8, 67.5% women). All patients showed a benign disease course and made a full recovery (median time to recovery was 8 days). The overall PSH recurrence rate was 36.3%. Multivariable analysis revealed that a history of PSH (OR=1.90, p=0.033) and severe intensity of stabbing pain (OR=1.92, p=0.015) were associated with a recurrence of PSH.

**Conclusion:** Our study demonstrated that more than one-third of patients with PSH experience a recurrence of PSH within two years of their initial diagnosis. A history of PSH and severe intensity of stabbing pain during an episode were associated with a recurrence of PSH.

### POST COVID HEADACHE, IN 510 CASES PRESENTED IN REGIONAL HOSPITAL DURRES, ALBANIA IN PERIOD NOVEMBER 2020 – MAY 2022

**Edlira Harizi**<sup>1</sup>, Ferid Domi<sup>2</sup>, Erind Shemsi<sup>3</sup>, Kledisa Shemsi<sup>4</sup>

<sup>1</sup>Neurology, Regional Hospital Durres, Albania

<sup>2</sup>Emergency, Regional Hospital Durres, Albania

<sup>3</sup>Student of Medicine, University of ZKM, Albania

<sup>4</sup>Internal Division, Rotkreuzklinik, Germany

**Background:** SARSCoV2 the virus responsible for the COVID19 pandemic had not only respiratory symptoms, but also neurological symptoms, and headache is a frequent complaint. Pathophysiology of headache in the context of COVID 19 has some mechanisms that can be involved in persistence of headache after acute stage of the disease. These mechanisms include systemic inflammation that can stimulate cytokine storm, can activate trigeminovascular system at the meninges, and in some patients this inflammatory response may be sustained after infection and can play role at post Covid headache.

**Methods:** We have seen 510 patients that have been presented at emergency department and neurology consult at SRD with headache after covid 19 (2-10 months after infections). 15% of patients had severe covid infections with respiratory insufficiency and have been recovered in hospital (76 patients) and 85% (434 patients) have been treated ambulatory. The most of patients had bilateral frontal headache (52%) and holocranic headache (22%), and hemicranic migraine type (26%). Most of patients had oppressive pain, 72% (367 patients) had moderate headache and 28% (143 patients) had severe continuous headache. Middle age of patients was 52 years old and 65% were female (331) and 35% male (179) and mean time of headache was 3.6 months from all patients. 30% (153 patients) have been known with primary headache, and 76% had migraine (116 patients, 78 female, 38 male), 22% tension type headache (34 patients, 20 female and 14 male) and 2% had cluster headache (3 patients were men). From all 510 of patients 45% (230) had also other post covid symptoms like dizziness, memory problems, insomnia, brain fog, depression and anxious state etc.

**Conclusions:** The mechanisms of persistent headache for months after covid 19 infections means to be stimulated by inflammatory mechanisms with

stimulation of the trigeminovascular system, and CGRP (calcitonin gene-related peptide) released by pulmonary endings nerve during viral infections may stimulate migraine.

#### **INVOLVEMENT OF MEDULLA OBLONGATA AND CERVICAL SPINE IN A PATIENT WITH POSTERIOR REVERSIBLE ENCEPHALOPATHY SYNDROME**

**H.S Jeong<sup>2</sup>, E.S Oh<sup>2</sup>, D.H Kim<sup>3</sup>**

<sup>1</sup>Neurology, Chungnam National University Sejong Hospital, South Korea

<sup>2</sup>Neurology, Chungnam National University Hospital, South Korea

<sup>3</sup>Neurology, Dong-A University Hospital, South Korea

**Background:** Reversible lesions in subcortical white matter in the occipital and temporal lobe is a characteristic anatomical involvement of PRES. PRES rarely involves the cervical spine or medulla oblongata. Herein, we report a case of PRES with an unusual radiologic finding involving medulla oblongata and upper cervical spine.

**Case:** A 21-year-old female complained of bilateral visual loss with a severe headache. Her headache was insidiously getting worsened over five days. Initial vital signs show high blood pressure (236/163mmHg) with elevated heart rate (118/min). She could perceive light and finger movement. Fundus photography showed bilateral papilledema. In brain MRI, there were patch-like confluent high signal intensity in the bilateral occipital lobe, medulla oblongata, and upper cervical spine (C1-2) with gadolinium enhancement sparing other brainstem structures. With a continuous injection of nicardipine, her blood pressure normalized, and visual symptoms began to recover. Within the secondary hypertension evaluation, plasma metanephrine and normetanephrine were elevated, 0.76 and 16.61, respectively. 24-hour urine showed the elevation of dopamine, epinephrine, and norepinephrine. We found an adrenal cyst sized 4.5cm in the abdominal CT. Laparoscopic adrenalectomy was performed and she was diagnosed with pheochromocytoma.

**Conclusion:** Here, we showed a rare involvement of the medulla oblongata and cervical spine in PRES.

The PRES lesions, in this case, were neither continuous nor apart from each other. This case suggests the possibility of PRES lesions in atypical anatomy with sparing of connecting structures. The atypical lesions remained with no neurological sequelae implying complete reversibility with the normalization of blood pressure.

#### **REAL-WORLD EFFICACY AND SAFETY OF GALCANEZUMAB IN PATIENTS WITH CHRONIC MIGRAINE; A PROSPECTIVE STUDY**

**ByungKun Kim<sup>1</sup>, SH Cho<sup>2</sup>, HC Lee<sup>1</sup>**

<sup>1</sup>Neurology, Nowon Eulji Medical Center, Eulji University School of Medicine, South Korea

<sup>2</sup>Neurology, Uijeongbu Eulji Medical Center, Eulji University School of Medicine, South Korea

**Introduction:** Galcanezumab is a novel migraine-specific preventive medication whose efficacy and safety were proved in clinical trials. But real-world data were limited, especially in Asian population.

**Methods:** We prospectively recruited patients with CM who underwent galcanezumab injection. Treatment response was determined after 12 weeks of follow-up. The primary outcome was defined as proportion of patients who achieved  $\geq 50\%$  reduction in monthly headache days (MHDs) from baseline to weeks 9-12.

**Results:** 222 patients with CM (83.8% female,  $44.2 \pm 12.5$  years, 60.3% medication overuse) completed 12 weeks treatment. Baseline mean MHDs were  $24.8 \pm 6.1$  days. A total of 146 patients (65.8%) achieved  $\geq 50\%$  reduction in MDs. More than one-third (36.5%) had a 75% response. A complete remission was observed in 5%. MHDs decreased by  $13.08 \pm 9.2$  days. Conversion from CM to EM was observed in 65.8% of patients (146/222). Mean headache intensity decreased from  $7.8 \pm 1.3$  to  $4.46 \pm 2.0$ . Days of acute medication intake per month were reduced by  $9.80 \pm 9.7$  days, 68.8% of patients with medication overuse had resolution of medication overuse. Vast majority of patients (80.2%) reported a noticeable change on the PGIC. Adverse events were reported by 31 (14.0%) of 222 patients. The most common side effect was constipation (11.7%) and skin reaction (2.3%). No patient discontinued treatment due to adverse events.

Conclusions: Our real-world data confirms efficacy and safety of galcanezumab shown in clinical trials. Galcanezumab in real life was well tolerated and seemed more effective than in RCTs.

#### **HOW STRESS REDUCES THE NEGATIVE IMPACTS OF ANXIETY AND DEPRESSION ON PATIENTS' ACTIVENESS**

**J. Kim<sup>1</sup>, Y. Kim<sup>2</sup>**

<sup>1</sup>*Department of Communication, Yonsei University, South Korea*

<sup>2</sup>*Department of Neurology, Hallym University Medical Center, Kangdong Sacred Heart Hospital, South Korea*

Objectives: Stress is often reported as related with various mental and somatic symptoms. However, there is a lack of understanding specifically how stress influences neurological illness. Mental health such as depression or anxiety are known to increase dizziness and headache, further deterring individuals' activeness. In this study, we examined how the influences of mental health on subsequent illnesses and activeness depend on stress levels.

Methods: A cross-sectional survey with 282 patients who visited neurology clinic was conducted. Depression, anxiety, dizziness, headache, stress, and activeness were measured. The data were analyzed using the PROCESS macro model 8. Age and sex were controlled.

Results: Depression increased dizziness ( $\beta = 0.5775$ ,  $p = .0248$ ) and headache ( $\beta = 2.4992$ ,  $p = .0001$ ). Anxiety increased dizziness ( $\beta = 0.5454$ ,  $p = .0244$ ) and headache ( $\beta = 2.1012$ ,  $p = .0003$ ). Stress moderated the effects that depression ( $\beta = -0.7711$ ,  $p = .0073$ ) and anxiety ( $\beta = -0.6399$ ,  $p = .0126$ ) had on headache. It also moderated the effect of depression on activeness ( $\beta = 1.7840$ ,  $p = .0365$ ). Both depression (Effect =  $-0.8149$ , SE =  $.3570$ , 95% CI =  $[-1.6237, -0.2403]$ ) and anxiety (Effect =  $-0.7288$ , SE =  $.3078$ , 95% CI =  $[-1.3319, -0.1073]$ ) moderated by stress influenced patients' activeness via headache.

Conclusion: This study revealed the importance of stress, as it directly affects headache, and also intensifies the influences that depression and anxiety have on headache and activeness. In addition, headache was a major venue that deters patients' activeness.

#### **EFFECTIVENESS OF MIGRAINE TREATMENT AFTER SWITCHING BETWEEN CGRP RECEPTOR ANTIBODIES AFTER FAILED INITIAL ANTIBODY TREATMENT**

**Monika Remenčiūtė, D. Geštautaitė, G. Žemgulytė, A. Vaitkus**

*Department of Neurology, Lithuanian University of Health Sciences, Lithuania*

Background: Although studies have shown the efficacy of CGRP-(receptor) monoclonal antibodies (mAb) in treating patients with migraine, there is still insufficient data that examines a switch of medication in cases when the initial treatment is not well tolerated or lacks efficacy.

Methods: We analyzed retrospective medical data from the Headache center at Lithuanian Health Science University's Kaunas Clinics Neurology department from 2021.11 to 2022.09. We identified 20 patients who had switched between CGRP-mAbs classes due to the lack of efficacy or intolerable side effects. Initial medication was either erenumab (16 patients) or fremanezumab (4 patients). Efficacy was assessed 3 months after the switch.

Results: Of the 20 patients included, 85% were women and 15% were men, the mean age was  $46.75 \pm 8.69$  at the first treatment phase. In the CGRP-mAb switch group medication changes were made after a mean of  $7.4 \pm 3.9$  months of initial treatment, or following the increase in erenumab dosage if it was prescribed as the initial medication. Monthly headache days were reduced in month three compared to the baseline of the medication switch ( $12.15 \pm 5.04$  to  $7.25 \pm 4.92$ ;  $p < 0.001$ ). Five (25%) patients switched treatment due to side effects (skin rash, constipation, increase in blood pressure, stroke), after the switch 2 (10%) patients reported minor side effects but continued using the medication (increase in blood pressure, dry mouth).

Conclusion: Our findings demonstrate that a switch of CGRP-mAb can be beneficial in reducing monthly headache days in migraine patients and should be considered in cases when patients experience side effects.

**THE CLINICAL EXPERIENCE WITH THE QUATERLY AJOVY DOSING REGIMEN IN 19 SEVERLY CHRONIC MIGRAINE PATIENTS WITH AN OVERUSAGE OF TRIPTANS BEFORE GIVEN AJOVY**

**Christina Sundal**<sup>1,2,3</sup>, Christina Sundal<sup>1,3</sup>

<sup>1</sup>Neurology, NeuroClinic Norway, Norway

<sup>2</sup>Institute of Neuroscience and Physiology, the Sahlgrenska Academy, University of Gothenburg, Department of Clinical Neurology, Sweden

<sup>3</sup>Neurology, Neuroclinic Norway, Norway

**Objective:** To present the clinical experience with the quaterly Ajovy dosing regimen in 19 severely chronic migraine patients with an overusage of triptans before given Ajovy.

**Background:** Chronic migraine affects 1.4–2.2% of the general population worldwide.

**Design/Methods:** Retrospective study in 19 severely chronic migraine patients that had an overusage of triptans before starting on Ajovy 3 injections every 3rd months. They were followed in the clinic from 2018. They have previously used all possible p.o migraine preventive treatments without any benefits. Demographic, headache characteristics and disability were measured from the headache diary every 3rd months. All patients have been using Ajovy for 2 years.

**Results:** From 2020 they started on Ajovy given every 3rd months.

Patients characteristics were as follow; Female: 18. Average age: 42 years (y) (range 20-64 y) HIT 6 pre Ajovy: 68,6 (range 63-74) HIT 6 Post Ajovy: 58,2 (range 36-66 y) Total days of migraine per month Pre Ajovy; 21,2 (range 16-30) Total days of Migraine per month Post Ajovy; 9,9 (range 0-30) Average severe days of migraine Post Ajovy: 2,3 (0-6) Average moderate days of migraine Post Ajovy: 4,3 (0-10) Average use of triptans post Ajovy: 6,6 days (0-9) Side effects were all tolerable and as follows; Stomach pain: 2/19, Obstipation 2/19, Redness/numbness inj.site: 4/19, Loosing hair: 2/19, Gain Weight: 3/19.

**Conclusions:** Our study indicates that a chronic severe migraine patient with an overuse of triptans can have a beneficial effect of Ajovy given every 3rd months.

**HEADACHE AND OBESITY IN CHILDREN WITH IDIOPATHIC INTRACRANIAL HYPERTENSION**

**Y. Waksman**, R. Lubetzky, A. Fattal-Valevski

*Pediatric Neurology Institute, Pediatric*

*Department, Dana-Dwek Children's Hospital,*

*Tel-Aviv Medical Center, Sackler School of*

*Medicine, Tel Aviv University, Israel*

**Background:** Idiopathic intracranial hypertension (IIH) is a condition characterized by increased intracranial pressure without a detectable cause. The most common symptom of IIH is a severe headache which occurs in almost all cases. Risk factors include being overweight or a recent increase in weight.

We studied and compared the clinical symptoms and laboratory findings in children with IIH with and without obesity.

**Methods:** For this case-control study we collected demographic, clinical and laboratory data on 15 patients with BMI  $\geq 25$  (obesity group) and on 15 patients with BMI  $< 25$  (normal-weight group). All children were diagnosed with IIH and underwent routine workup. The data retrieved from the medical records of all participants included demographic, clinical and laboratory findings. A clinical questionnaire regarding headaches and clinical symptoms was administered to all patients.

**Results:** Significant intergroup differences were found in median age (obesity group 13 years (range 11-14) vs. normal-weight 11 years (range 6.5-13);  $p=0.022$ ), sex (87% females in obesity group vs. 47% in normal-weight;  $p=0.02$ ), and in laboratory findings: mean pH ( $p=0.048$ ), mean triglycerides ( $p=0.012$ ), mean vitamin D3 ( $p=0.013$ ) and median CRP ( $p=0.044$ ).

There was no significant intergroup difference in headaches intensity, frequency, awakening from sleep, nausea, vomiting, blurred vision, tinnitus and mean lumbar puncture opening pressure.

**Conclusions:** Obesity had no significant effect on the clinical picture and severity of symptoms in patients with IIH, including headaches. Age, gender and laboratory workup could serve as early screening criteria to identify patients with obesity who are at risk for IIH.

### CAN WE DISCRIMINATE MIGRAINE SUSCEPTIBLE TO CGRP ANTAGONISM?

**Marjan Zaletel**<sup>2</sup>, Gorazd Požlep<sup>2</sup>, Darja Visočnik<sup>1</sup>, Matija Zupan<sup>1</sup>, Bojana Žvan<sup>1</sup>

<sup>1</sup>*Vascular Neurology, University Clinical Centre of Ljubljana, Slovenia*

<sup>2</sup>*Pain Clinic, University Clinical Centre of Ljubljana, Slovenia*

Migraine is recognized as a disorder of calcitonin gene-related peptide (CGRP) pathway. CGRP test can discriminate migraine from non-migraine using CGRP-induced headache (CGRP-IH) and cerebral hemodynamic changes. We test the hypothesis that hemodynamic changes related to cerebral vascular responses could distinguish migraineurs prone to CGRP effects.

We included two groups of participants. Group A consisted of twenty healthy participants (nine females aged  $37.0 \pm 2.8$  years and 11 males aged  $41.8 \pm 7.6$  years). Group B consisted of twenty participants with migraine (15 females aged  $41.9 \pm 9.9$  years, five males aged  $38.2 \pm 9.2$  years). Responses in a middle cerebral artery (MCA) and posterior ce-

rebral artery (PCA) were determined by measuring mean arterial velocity (vm) during CGRP stimulation. CGRP-IH, migraine was detected according to the third edition of the International Classification of Headache Disorders. We calculated the responses (R) of vm MCA, vm PCA, Et-CO<sub>2</sub>, heart rate (HR), and mean arterial pressure (MAP) as differences between measuring points.

We found significant differences in the frequency of CGRP-IH between migraineurs and non-migraineurs ( $p=0.001$ ). We found a positive linear relationship between responses R2 vm MCA and R2 Et-CO<sub>2</sub> ( $r=0.477$ ,  $p=0.002$ ) and a significant difference between the product of R2 vm MCA-Et-CO<sub>2</sub> of migraineurs ( $30.3 \pm 8.7$  cms-1 mmHg) and controls ( $4.9 \pm 2.8$  cms-1 mmHg) ( $p=0.008$ ). The AUC for product R2 vm MCA-Et-CO<sub>2</sub> is 0.750 (95% CI 0.598-0.902  $p=0.007$ ).

CGRP- test might discriminate between migraine susceptible to CGRP from non-susceptible CGRP migraineurs and non-migraineurs. It could be used to predict response to anti-CGRP monoclonal antibodies.





## Multiple Sclerosis

### **FAMILY PLANNING PATIENT'S AWARENESS REPRESENT MAJOR LACK OF KNOWLEDGE IN MULTIPLE SCLEROSIS**

Olivera Tamas<sup>1,2</sup>, J Saranovic<sup>2</sup>, M Kovacevic<sup>2</sup>, N Veselinovic<sup>1,2</sup>, M Stefanovic Budimkic<sup>1,2</sup>, V Jovicevic<sup>1</sup>, J Ivanovic<sup>1</sup>, N Momcilovic<sup>1</sup>, M Andabaka<sup>1</sup>, J Vitkovic<sup>1</sup>, S Mesaros<sup>1,2</sup>, **J Drulovic<sup>1,2</sup>**

<sup>1</sup>*Department for Immune - Mediated Disorders of the Central Nervous System, Neurology Clinic, Serbia*

<sup>2</sup>*University of Belgrade, Faculty of Medicine, Serbia*

**Introduction:** Multiple sclerosis (MS) affects women of childbearing age. We investigated the extent of familiarity of female MS patients with effects of disease modifying therapy (DMT) on pregnancy and estimation of the type and frequency of contraception use.

**Materials and methods:** Demographic and clinical data were obtained from the official therapy registry of the Neurology Clinic, University Clinical Centre of Serbia. A telephone survey was conducted from October to December 2021 and containing 12 questions on current and previous pregnancies, methods of contraception used, knowledge of potential teratogenicity of DMT, its secretion into sperm and whether they possessed sufficient information regarding family planning and DMT. Females aged 18 to 45 receiving highly effective DMT were included.

**Results:** Out of 122 patents included in the cohort eight (6.6%) women used contraception, while 52 (42.6%) reported the use of condoms by partners, and only two (1.6%) used dual contraception. Ninety-one (74.6%) were adequately informed on risk of teratogenicity of DMT while 31 (25.4%) not. Over half (54.1%) of the participants felt they had sufficient information regarding respective therapy and family planning. Sixty (49.2%) thought secretion of DMT into semen could occur, 53 (43.4%) thought it could not, 9 (7.4%) were not certain. Sixty (49.2%) patients reported its neurologist to be the main source of information related to MS and pregnancy.

**Conclusion:** This survey demonstrated high levels of awareness regarding risk of teratogenicity of DMT, insufficient information regarding family planning and insufficient contraception use. More effort

should be invested in education and providing resources to women with MS.

**Key words:** multiple sclerosis, disease modifying therapy, family planning, teratogenicity, survey

### **RATES OF JC VIRUS SEROCONVERSION GREATLY REDUCED DURING COVID-19 RELATED LOCKDOWNS**

**Chris Dwyer<sup>1</sup>**, Sifat Sharmin<sup>1,2</sup>, Tomas Kalincik<sup>1,2</sup>

<sup>1</sup>*Neuroimmunology Centre, Department of Neurology, Royal Melbourne Hospital, Australia*

<sup>2</sup>*CORe, Department of Medicine, University of Melbourne, Australia*

**Aims:** To retrospectively compare rates of John Cunningham virus (JCV) seroconversion in natalizumab-treated patients before and during COVID-19-related community restrictions in Melbourne, Australia.

**Background:** Natalizumab is highly effective for relapsing-remitting multiple sclerosis. Its use is complicated by JCV colonisation. Prolonged exposure to natalizumab in JCV-positive patients can cause progressive multifocal leukoencephalopathy (PML), a potentially fatal brain infection. Serial assessment of JCV status is required for all patients receiving natalizumab.

**Methods:** Patients receiving natalizumab at the Royal Melbourne Hospital were assessed for change in JCV serostatus and duration of exposure to natalizumab in two discrete time periods: from March 2007 until February 2017 ("pre-COVID")(n=296) and from 1 April 2020 until 12 October 2022 ("COVID lockdown")(n=214). Sensitivity analyses examined whether sex or age affected time to seroconversion.

**Results:** We have previously published pre-COVID JCV seroconversion rates at the Royal Melbourne Hospital. The annualised seroconversion rate during this time period was 7.3%. Conversely, we found a precipitous decline in JCV seroconversion during COVID lockdown. The annualised seroconversion rate was 5.7 times higher during the pre-COVID-19 period (95%CI 5.31-6.09, p0.0001) compared to the annualised seroconversion rate of 1.3% during COVID lockdown. Sex and age did not affect time to seroconversion.

**Conclusion:** The rate of JCV seroconversion among natalizumab-treated patients was decreased during COVID-19-related community restrictions implemented in Melbourne, Australia between April 2020 and October 2021. These were among the longest and most comprehensive restrictions implemented worldwide. This suggests the presence of modifiable risk factors that could reduce JCV seroconversion among natalizumab-treated patients.

**MRI, EFFICACY, AND SAFETY OF TOLEBRUTINIB IN PATIENTS WITH HIGHLY ACTIVE DISEASE (HAD): 2-YEAR DATA FROM THE PHASE 2B LONG-TERM SAFETY (LTS) STUDY**

**R. Fox<sup>1</sup>, J. Oh<sup>2</sup>, D. Arnold<sup>3</sup>, S. Syed<sup>4</sup>, Z. Xu<sup>5</sup>, T. Turner<sup>4</sup>, A. Traboulsee<sup>6</sup>, D. Reich<sup>7</sup>**

<sup>1</sup>*Mellen Center for Multiple Sclerosis, Cleveland Clinic, USA*

<sup>2</sup>*Division of Neurology, St. Michael's Hospital, University of Toronto, Canada*

<sup>3</sup>*Montreal Neurological Institute, McGill University and NeuroRx Research, Canada*

<sup>4</sup>*Neurology Development, Sanofi, USA*

<sup>5</sup>*Biostatistics and Programming, Sanofi, USA*

<sup>6</sup>*Department of Medicine, University of British Columbia, Canada*

<sup>7</sup>*Translational Neuroradiology Section, National Institute of Neurological Disorders and Stroke, USA*

**Introduction:** In the phase 2b trial (NCT03889639), brain-penetrant Bruton's tyrosine kinase inhibitor, tolebrutinib, was well-tolerated with dose-dependent reductions in MRI-lesions.

**Objectives:** To report MRI, efficacy, and safety outcomes at Week (W) 96 (2 years) of the phase 2b long-term safety (LTS) extension (NCT03996291) in participants with relapsing multiple sclerosis and highly active disease (HAD).

**Methods:** In double-blind LTS Part-A, participants continued receiving tolebrutinib 5/15/30/60mg daily; in open-label Part-B, all received 60mg/day. Outcomes included gadolinium-enhancing T1- and new/enlarging T2-lesions, annualised relapse rate (ARR), and Expanded Disability Status Scale (EDSS) score.

**Results:** 61 participants met HAD criteria at baseline; 60 continued in Part-A and 59 transitioned to

Part-B. As of March 7<sup>th</sup>, 2022, 92% remained on study. New gadolinium-enhancing T1-lesions remained low in 60/60-mg arm through W96 and were reduced in other arms W48-W96, except for 5/60 (W96 mean±SD: 2.00±3.83, 0.56±1.04, 0.47±1.13, 0.23±0.44 in 5/60-, 15/60-, 30/60-, 60/60-mg arms, respectively). New/enlarging T2-lesions remained low for 15/60, 30/60, and 60/60-mg. T2-lesion volume remained unchanged for 60/60-mg. Most common treatment-emergent adverse events (TEAEs) were COVID-19 (20%), nasopharyngitis (16.7%), headache (13.3%), and upper respiratory tract infection (8.3%). There was no dose-relationship for TEAE/serious AE (Part-A) and no new safety findings upon switching to 60mg (Part-B). In participants receiving tolebrutinib 60mg/day for ≥8 weeks, ARR was 0.10 (95%CI: 0.02-0.66) and 92.9% remained relapse-free. Mean EDSS were stable through W96.

**Conclusions:** Through LTS W96, in HAD cohort, tolebrutinib 60mg demonstrated favourable safety, tolerability, and low ARR. MRI lesion counts remained low for 60/60-mg arm.

**Funding:** Sanofi.

**THE MS IMPLEMENTATION NETWORK: DEVELOPING A LEARNING HEALTH SYSTEM COLLABORATIVE AND COMMUNITY OF PRACTICE FOR IMPROVEMENT, INNOVATION AND IMPLEMENTATION RESEARCH TO IMPROVE OUTCOMES IN MS**

**Amanda Montague**

*Mission Department, Multiple Sclerosis Association of America, USA*

The MS Implementation Network (MSIN) is a learning health system collaborative and community of practice for improvement, innovation and implementation research to optimize health and outcomes for people living with multiple sclerosis (MS). Co-designed by the Multiple Sclerosis Association of America and Dartmouth University, MSIN seeks to establish the first implementation science research network for multiple sclerosis.

MS is a complex, chronic, and costly ("3C") condition that is among the most common and disabling neurological diseases in adults. MS affects nearly one million Americans with a prevalence of 309 per 100,000 adults and generates substantial burden on

people with MS (PwMS), the healthcare system, and society as a whole, with estimated annual individual cost to a PwMS of \$8528-\$54,244. While MS has been investigated at the basic science, individual and population levels of analysis, including large data registry initiatives, this study will establish the first multi-center implementation science research network for MS, evaluate system- and population-level variation in process and outcomes of care, evaluate implementation feasibility, acceptability, utility and effectiveness while also informing best practices in how patient advocacy organizations, healthcare centers and research institutes can work collaboratively to improve outcomes and quality of life for people with MS.

Implications for future research in MS and other chronic illnesses will be explored.

**SAFETY AND CLINICAL EFFICACY OUTCOMES FROM THE LONG-TERM EXTENSION STUDY OF TOLEBRUTINIB IN PARTICIPANTS WITH RELAPSING MULTIPLE SCLEROSIS: 2-YEAR RESULTS**

**J. Oh<sup>1</sup>, S. Syed<sup>2</sup>, L. Orogun<sup>2</sup>, Z. Xu<sup>3</sup>, T. Turner<sup>2</sup>, R. Fox<sup>4</sup>**

<sup>1</sup>*Division of Neurology, St. Michael's Hospital, University of Toronto, Canada*

<sup>2</sup>*Neurology Development, Sanofi, USA*

<sup>3</sup>*Biostatistics and Programming, Sanofi, USA*

<sup>4</sup>*Mellen Center for Multiple Sclerosis, Cleveland Clinic, USA*

**Introduction:** In the phase 2b trial (NCT03889639), brain-penetrant Bruton's tyrosine kinase inhibitor, tolebrutinib, was well-tolerated and elicited dose-dependent reductions in new gadolinium-enhancing T1 and new/enlarging T2 lesions in participants with relapsing multiple sclerosis.

**Objectives:** To report safety and efficacy at Week (W) 96 in a long-term safety (LTS) extension (NCT03996291) of the phase 2b trial.

**Methods:** In double-blind LTS Part-A, participants continued receiving tolebrutinib 5, 15, 30, or 60mg/day until phase 3 dose selection (60mg/day). In open-label Part-B, participants received tolebrutinib 60mg/day. Safety was assessed via adverse events (AEs). Efficacy outcomes included annualised relapse rate (ARR) and change in Expanded Disability Status Scale (EDSS) score from baseline.

**Results:** As of March 7<sup>th</sup>, 2022, 114 (90.5%) participants remained on study. One participant receiving tolebrutinib 5mg/day discontinued Part-A because of progressive disease and 10 discontinued Part-B because of AEs (n=3), perceived lack of efficacy (n=4), emigration (n=2), and participant decision (n=1). At W96, no new safety signals were observed. The most common treatment-emergent AEs (TEAEs) were COVID-19 (20.8% [26/125]), headache (13.6% [17/125]), nasopharyngitis and upper respiratory tract infection (both 11.2% [14/125]), bacterial cystitis (7.2% [9/125]), pharyngitis and arthralgia (each 5.6% [7/125]). No tolebrutinib dose effects for TEAEs/serious AEs were observed (Part-A) and no safety signals emerged for participants switching to 60mg/day (Part-B). In participants receiving tolebrutinib 60mg/day for ≥8 weeks, ARR was 0.17 (95%CI: 0.12-0.25) and 80.6% remained relapse-free. Mean EDSS remained stable to W96.

**Conclusions:** Through LTS W96, tolebrutinib 60mg/day continued demonstrating favourable safety, low ARR, and stable disability.

**Funding:** Sanofi.

**QUALITY OF LIFE DURING THE MENOPAUSE IN MULTIPLE SCLEROSIS PATIENTS**

**Celia Oreja-Guevara**, Lorena García-Vasco, Johnny Quezada-Sánchez, Irene Gómez-Estevez  
*Neurology, Hospital Universitario Clínico San Carlos, Spain*

**Background:** During menopause there is a reduction of sex hormones and it is not clear if this influences the evolution and progression of the disease .

**Objectives:** To analyse the quality of life of multiple sclerosis patients during menopause using the validated Cervantes-SF scale.

**Methods:** Prospective study.

MS patients with menopause (first 5 years) were recruited.

Demographic, gynecological and MS disease data were collected.

Quality of life was studied with the validated Cervantes-SF Scale with 16 items which is divided into 4 domains and 3 subdomains. We compared these result with the results of healthy menopausal women.

Results: 63 patients were included with a mean age of 53 years and a mean of 4.3 years of menopause. They were compared with 100 healthy women with a mean age of 49 and 4.5 years of menopause.

Regarding the Cervantes Scale data, the results of the following subdomains were: 37.46 in vasomotor; 26.15 in health; 52.78 in aging; 38.80 in menopause-health; 39.07 in psychic domain; 43.97 in sexuality and 13.27 in couple.

The quality of life measured was significant better for MS patients in sexuality and menopause-health. However, in the mood and elderly domain, MS patients score significant worse (difference of 2.36 points) compared to the control.

Conclusions: Despite the disease, quality of life during menopause in multiple sclerosis is similar to that of the healthy population with the exception of that related to multiple sclerosis symptoms and mood and aging.

#### **ANTICIPATION PHENOMENON IN MULTIPLE SCLEROSIS: EARLIER AGE OF SYMPTOM ONSET IN YOUNGER GENERATION OF FAMILIAL CASES**

**Tatjana Pekmezovic**<sup>2</sup>, A. Jovanovic<sup>2</sup>, S. Mesaros<sup>1</sup>, I. Novakovic<sup>3</sup>, B. Peterlin<sup>4</sup>, N. Veselinovic<sup>1</sup>, O. Tamas<sup>1</sup>, J. Ivanovic<sup>1</sup>, G. Maric<sup>2</sup>, M. Andabaka<sup>1</sup>, N. Momcilovic<sup>1</sup>, J. Drulovic<sup>1</sup>

<sup>1</sup>*Multiple Sclerosis, Clinic of Neurology, UCCS, Faculty of Medicine, University of Belgrade, Serbia*

<sup>2</sup>*Institute of Epidemiology, University of Belgrade, Faculty of Medicine, Serbia*

<sup>3</sup>*Institute of Genetics, University of Belgrade, Faculty of Medicine, Serbia*

<sup>4</sup>*Clinical Center Ljubljana, University of Ljubljana, Faculty of Medicine, Slovenia*

Aim: The aim of this study was to assess the prevalence of familial MS (fMS) in Belgrade MS population, discern the differences between the persons with fMS and sporadic MS, and to detect the presence of anticipation phenomenon in fMS patients.

Methods: The data on the demographic and clinical characteristics of MS patients was obtained from the Belgrade MS population Registry. In cases of vertical transmission of MS, the family members were divided into the younger and older generation, in order to assess the potential presence of anticipation phenomenon. To adjust for follow-up time bias, a secondary analysis including only patients who had

the onset of symptoms before 39 years (75. percentile), and those who were 39+ years, was performed.

Results: The prevalence of fMS in Belgrade MS population is 6.4%. FMS cases had earlier age at MS symptom onset (30.4 vs. 32.3 years) compared to sporadic MS cohort. When comparing fMS cases across generations, the younger generation had significantly lower age at onset compared with the older one (25.8 vs. 35.7 years, p0.001). After adjustment for the different length of the follow-up, the difference in age at symptom onset between the groups was reduced, but it still existed and was statistically significant (30.0 years in younger vs. 36.4 years in older generation, p=0.040).

Conclusion: In our study, the analysis of fMS cases across generations, showed an earlier age of symptom onset in the younger generation, even after adjustment. These results indicate the possibility of existence of anticipation phenomenon.

#### **MRI OUTCOMES FROM THE LONG-TERM EXTENSION STUDY OF TOLEBRUTINIB IN PATIENTS WITH RELAPSING MULTIPLE SCLEROSIS: 2-YEAR RESULTS**

**D. Reich**<sup>1</sup>, A. Traboulsee<sup>2</sup>, S. Syed<sup>3</sup>, Z. Xu<sup>4</sup>, T. Turner<sup>3</sup>, D. Arnold<sup>5</sup>

<sup>1</sup>*Translational Neuroradiology Section, National Institute of Neurological Disorders and Stroke, USA*

<sup>2</sup>*Department of Medicine, University of British Columbia, Canada*

<sup>3</sup>*Neurology Development, Sanofi, USA*

<sup>4</sup>*Biostatistics and Programming, Sanofi, USA*

<sup>5</sup>*Montreal Neurological Institute, McGill University and NeuroRx Research, Canada*

Introduction: In the phase 2b trial (NCT03889639), Bruton's tyrosine kinase inhibitor, tolebrutinib, was well-tolerated in participants with relapsing multiple sclerosis with dose-dependent reductions in MRI lesions. LTS16004 (NCT03996291) is the ongoing long-term safety (LTS) extension study.

Objectives: To report MRI outcomes at Week (W) 96 (2 years) in LTS16004.

Methods: In LTS Part-A, participants continued receiving tolebrutinib 5/15/30/60mg daily; in open-label Part-B, all received 60mg/day. MRI outcomes included numbers of new gadolinium-enhancing T1 and new/enlarging T2-lesions, T2-lesion volume

change, slowly evolving lesions (SELs), and paramagnetic rim lesions (PRLs).

Results: As of February 18<sup>th</sup>, 2022, 90.5% remained on study. Mean baseline age $\pm$ SD was 37.7 $\pm$ 9.6 years; 69% were women. New gadolinium-enhancing lesions remained low in 60/60-mg arm through W96 and were reduced in other arms W48-W96 (W96 mean $\pm$ SD: 0.85 $\pm$ 2.5, 0.41 $\pm$ 0.91, 0.90 $\pm$ 2.16, 0.31 $\pm$ 0.66 in 5/60-, 15/60-, 30/60-, 60/60-mg arms, respectively). New/enlarging T2-lesions remained low for 60/60-mg. T2-lesion volume change remained low for 60/60-mg (W96 vs baseline [mean $\pm$ SD]: +0.38 $\pm$ 2.11 cm<sup>3</sup>). Median (IQR) W96 SEL volume was 247.5 (84–420), 258 (66–906), 570 (133.5–1011), and 244.5 (87–939) mm<sup>3</sup> for 5/60-, 15/60-, 30/60-, and 60/60-mg arms, respectively. PRL count remained unchanged in 18 participants; 2 had 1 PRL at baseline but none at W96, and 3 had 1–3 additional PRLs at W96 vs baseline (none in the 60/60-mg arm).

Conclusions: New gadolinium-enhancing lesions remained low for tolebrutinib 60/60-mg and were reduced in lower dose arms W48-W96, when all participants had switched to 60mg.

Funding: Sanofi.

#### **COULD VISUAL FIELD ASSESSMENT BE USEFUL AS SCREENING METHOD FOR MULTIPLE SCLEROSIS PATIENTS?**

**Johnny Quezada Sánchez**<sup>1</sup>, I. Gómez-Estévez<sup>1</sup>, J. Rouco-Maseda<sup>2</sup>, E. Alba-Suárez<sup>1</sup>, C. Oreja-Guevara<sup>1</sup>

<sup>1</sup>Neurology. CSUR Multiple Sclerosis, Hospital Clínico San Carlos, Spain

<sup>2</sup>Computer Science Faculty, Coruña University, Spain

Introduction: Optic neuritis (ON) is often a common symptom at the onset of MS and can impair visual function. The presence of scotomas in the visual field is often a symptom of MS and it could be reduced the quality of life.

Objective: To analyse the visual field (VF) in MS patients with and without previous NO.

Methods: MS patients with more than six months of follow-up and clinically stable in the last six months were analysed.

VF was measured with the 24-2 SITA Fast protocol of the Humphrey campimeter and we compared eyes with and without prior ON.

The global indices are the average and the deviation of deficit values that summarise the state of the visual field.

Results: We analysed 43 patients (28 women) with a mean age of 45. Of the 86 eyes we examined, 26 had previous NO and 60.

The global indices (Mean Deviation (MD) and Model Standard Deviation (MSD)) showed significant alterations in MD (p-value=0.009) and MSD (p-value=0.04) with higher values for ON group.

We obtained a strong negative correlation ( $r=-0.54$ ) between the DSM with the visual acuity of 2.50% contrast in the ON group. When the VA of 2.50% contrast was reduced there was a greater presence of localised scotomas in the VF in ON.

Conclusion: Visual field determination is useful to detect the severity of visual disturbances in MS patients with optic neuritis and could therefore serve as a screening protocol in MS patients.

#### **PRELIMINARY RESULTS FROM A 3-YEAR LONGITUDINAL STUDY OF COGNITION IN HONG KONG CHINESE WITH MULTIPLE SCLEROSIS (MS)**

**Angel Ng**, Lin Zhao, Jill Abrigo, Cheryl Au, Vincent Mok, Adrian Wong, Alexander Lau  
*Department of Medicine and Therapeutics, The Chinese University of Hong Kong, Hong Kong*

Background: Cognitive dysfunctions are prevalent in multiple sclerosis (MS), however, longitudinal studies of cognition in Asian MS populations were scarce.

Objectives: This study aims 1) to evaluate the neuropsychological profile of Hong Kong Chinese with MS; 2) to monitor the disability progression and neuropsychological dysfunctions over time; 3) to identify which parameter(s) best predict future cognitive decline and disability progression.

**Methods:** Hong Kong Chinese with MS were recruited from Hong Kong MS Registry (CU-HKM-SR) and underwent a range of clinical evaluations at 12-month intervals over a 3-year follow-up period. Expanded Disability Status Scale (EDSS) and Multiple Sclerosis Functional Composite (MSFC) were used to assess MS severity and physical disability. Neuropsychological battery was performed to assess the cognitive abilities, including memory, attention, information processing, psychomotor speed, executive function, and visuospatial perception.

**Results:** A total of 68 MS patients (78% female, mean<sub>age</sub> 36.65±7.91) were recruited. At baseline, 52/68 (76%) patients with MS were found to have ≥1 impaired cognitive domain(s). In addition, MS patients performed significantly worse on 9-hole Peg Test (mean<sub>9HPT</sub> 23.22±6.36 vs. 18.37±1.79, p0.001), Symbol Digit Modalities Test (mean<sub>SDMT</sub> 51.38±14.30 vs. 58.88±12.01, p0.001), and Chinese Auditory Verbal Learning Test (mean<sub>CAVLT</sub> 9.61±3.49 vs. 10.75±2.77, p=0.036), compared to healthy controls. In longitudinal analyses, baseline performance on SDMT and 9HPT predicted the number of impaired cognitive domains ( $\beta$ =-0.863, p0.05) and the extent of physical disability ( $\beta$ =-0.777, p 0.05).

**Conclusion:** This study provided valuable information on neuropsychological profile in Asian MS populations. SDMT and 9HPT are useful in monitoring disease progression and assisting early detection of neurodegeneration in MS.

#### **INSIGHT IN miRNome OF SEVERE MULTIPLE SCLEROSIS: PILOT STUDY OF DISTINCTIVE RELAPSE-ONSET MS PHENOTYPES**

**Aleksandra Stankovic**<sup>1</sup>, I. Jovanovic<sup>1</sup>, E. Dincic<sup>2</sup>, S. Vojinovic<sup>3,4</sup>, Lj. Stojkovic<sup>1</sup>, A. Djordjevic<sup>1</sup>, J. Kuveljic<sup>1</sup>, M. Zivkovic<sup>1</sup>

<sup>1</sup>Laboratory for Radiobiology and Molecular Genetics, Vinca Institute for Nuclear Sciences, National Institute of the Republic of Serbia, University of Belgrade, Serbia

<sup>2</sup>Clinic for Neurology, Military Medical Academy, Serbia

<sup>3</sup>Clinic of Neurology, Clinical Center Nis, Serbia

<sup>4</sup>Medical Faculty, University of Nis, Serbia

Molecular background and biomarkers of highly heterogeneous and hardly predictable disease progression among relapse-onset MS patients are of high research interest. In the current pilot study, we aimed

to employ next-generation sequencing to investigate the expression of whole small non-coding microRNAs (miRNome) in two groups of MS patients with highly distinctive progression phenotype: one with fast progressing, severely disabling course vs. mild course of MS, longitudinally followed 10 years. Peripheral blood mononuclear cells (PBMC) miRNome data was obtained from mild phenotype MS (n=4 patients) and progressive phenotype MS (n=5 patients), using TakaraBio SMARTer smRNA-Seq Kit on iSeq100 (Illumina). Pre-processing of raw sequencing data, quality control and miRNA differential expression analysis was performed using sRNAtoolbox pipeline. Functional interpretation of differentially expressed miRNA target genes was done in DIANA-miRPathv3.0. Tarbase v8.0 served as a resource of miRNA:gene interactions. Achieved read depth was approximately 1 million raw reads/sample, allowing detection of up to 92 mature miRNAs after genome alignment and miRbase v22 annotation. Differential expression analysis identified the significant upregulation of hsa-miR-23c (log<sub>2</sub>FC=4.29, Padj= 0.03) in progressive phenotype. Top significantly enriched KEGG pathways in hsa-miR-23c targets suggested regulation of molecular pathways involved in autoimmunity (antigen presentation, Epstein-Barr virus infection) and cancer. In conclusion, this pilot study indicates phenotype-related differences in expression of miRNAs, molecules with high regulatory and biomarker properties. Although detected in PBMC, hsa-miR-23c is highly expressed in the brain and target MS relevant genes such as, HLA (A, B, C), transferrin receptor, Nrf2, recently proposed to play important role in neurodege

#### **COEXISTENCE OF MULTIPLE SCLEROSIS AND HUNTINGTON'S DISEASE**

**M. Vodopić**, M. Drobac

*Neurology, General Hospital Dubrovnik, Croatia*

This is a case report of Huntington's disease (HD) in a 26-year-old male with multiple sclerosis (MS). The diagnosis of MS met the McDonald criteria and was based on clinical attacks separated in space and time, cerebrospinal fluid, and MRI. The diagnosis of HD was established by DNA testing and family history. While a number of neurologic and autoimmune diseases have been reported with MS, this is the first co-occurrence of HD and MS in Croatia. Salient features of both disorders are reviewed as well as the importance of obtaining a thorough family history.

Case report: D.M., a 26-year-old male was diagnosed with MS in 2016. His first clinical presentation was left-sided incomplete transverse myelitis from the C3 level. We found positive oligoclonal bands in CSF. MRI showed typical MS lesions in the right parietal juckstacortical region and active leasion in the cervical spinal cord, C3 segment. This was proof of dissemination in time and after 3 months MRI showed new T2 hyperintense leasions in the right frontal periventricular white matter that showed dissemination in space. In 2018. within the family DNA testing for Huntington`s disease, he was positive. Until now he didn`t have any clinical events that can support the diagnosis of HD, but he can expect a clinical presentation later on.

Discussion: Expanded CAG repeats are unstable and may expand further over time and with successive generations. So it is very possible that this patient will develop symptoms of HD earlier than his father.

#### **THE RELATION BETWEEN WEIGHT AND IGG/ IGM CHANGES IN MULTIPLE SCLEROSIS PATIENTS DURING LONG TERM CD20 DEPLETING THERAPY**

**Galina Vorobeychik**<sup>1,3</sup>, Himali Bergeron-Vitez<sup>1,2</sup>, Jill Nelson<sup>1</sup>, Anna Kazimirchik<sup>1</sup>,

<sup>1</sup>*Multiple Sclerosis Clinic, Fraser Health Authority, Canada*

<sup>2</sup>*Anesthesiology, Pharmacology and Therapeutics, University of British Columbia, Canada*

<sup>3</sup>*Neurology, University of British Columbia, Canada*

In British Columbia, Ocrevus is covered only for primary progressive MS (PPMS) and Rituximab for relapsing-remitting MS (RRMS). This study`s purpose was to investigate differences in Immunoglobulin G/M (IgG, IgM) between PPMS and RRMS patients after long-term CD20-depleting therapy in terms of weight.

During a retrospective chart review, IgG and IgM concentrations of MS patients on CD20 depleting therapy for at least 3 years were analyzed. Fisher`s Exact tests were run to assess differences in abnormal IgG/IgM between PPMS patients (on Ocrevus) and RRMS patients (on Rituximab), and to analyze differences in weight between abnormal vs normal levels and between PPMS and RRMS patients.

12 PPMS and 12 RRMS patients who had been on therapy for an average of 3.5 years were selected. In

each group, 8 patients (66.7%) were females. 9 PPMS patients had abnormal (lower than normal) IgG or IgM compared to 3 RRMS patients, which was significantly different ( $p=0.039$ ). The average weight was slightly higher for the abnormal IgG/IgM group relative to the normal group, but it was not significant ( $p=0.36$ ). The average weight for PPMS and RRMS patients was not significantly different ( $p=0.7$ ).

This study raises the possibility of a progressive course of MS influencing IgG/IgM levels after long-term use of CD20-depleting therapy regardless of patient weight or BMI. Contrary to literature (Mokhtarzade et al. 2019), our findings suggest that weight remains similar, regardless of disease course and that it may not be predictive of hyperglobulinemia. Future multi-center studies in this field with greater sample size may provide insights to improve MS management.

#### **CHITOTIROSIDASE AS A BIOMARKER OF MS ACTIVITY**

**Ljiljana Zaninović**<sup>1</sup>, Ana Turčić<sup>1</sup>, Tereza Gabelić<sup>2</sup>, Željka Vogrinc<sup>1</sup>

<sup>1</sup>*Department of Laboratory Diagnostics, University School of Medicine and University Hospital Center Zagreb, Croatia*

<sup>2</sup>*Department of Neurology, University School of Medicine and University Hospital Center Zagreb, Croatia*

Introduction: Myelin-containing phagocytes are a pathological hallmark of MS and these phagocytes show great similarity to lipid-rich or foamy macrophages which strongly express cell markers such as chitotriosidase (CHIT). The concentration of CHIT in cerebrospinal fluid (CSF) and the CSF/serum CHIT activity quotient (QHITO) are markers that can predict a faster transition from clinically isolated syndrome (CIS) to actual MS. The aim of our study was to investigate whether there is a difference in the value of CHIT in the CSF or the QHITO between patients depending on the presence of active lesions on the first MR image, or during follow-up over the years.

Materials and Methods: The study included 170 relapse-remitting multiple sclerosis (RRMS) patients who were followed for a period of at least 2 years. Follow-up data for a maximum of 10 years was reviewed. CHIT activity was measured in CSF and



serum using fluorogenic 4-methylumbelliferyl (4MU)-chitotrioside as the substrate.

Results: At diagnosis, patients with active lesions on MRI (N=68,4%) had significantly higher QHITO (0.59, IQR=0.31-0.94, P=0.004) and percentage of intrathecal activity (CHITITA) (52%, IQR=15-71, P=0.006) compared to patients without active lesions. During the follow-up, only 44 patients (26%) had non-active RRMS. QHITO was significantly higher in active (0.50, IQR=0.24-0.90) compared to non-active (0.28, IQR=0.09-0.62) RRMS patients (P=0.008).

Conclusion: The values of CHIT in the CSF and/or the QHITO could be good markers for monitoring and evaluating disease activity in RRMS patients.

#### **LEPTIN SIGNALLING GENETIC VARIANTS AND INSULIN RESISTANCE IN MULTIPLE SCLEROSIS PATIENTS**

**Maja Zivkovic<sup>1</sup>**, S. Kostic<sup>2</sup>, L. Stojkovic<sup>1</sup>, I. Kolic<sup>1</sup>, A. Stankovic<sup>1</sup>, E. Dincic<sup>2</sup>

<sup>1</sup>Laboratory for Radiobiology and Molecular Genetics, "Vin a" Institute of Nuclear Sciences - National Institute of the Republic of Serbia, University of Belgrade, Serbia

<sup>2</sup>Clinic for Neurology, Military Medical Academy, Serbia

Last decade provided multiple evidence that link disturbances in metabolic processes and energy me-

tabolism with diseases of central nervous system and neurodegeneration. Initial phases of insulin resistance (IR) are present in natural course of multiple sclerosis (MS) and leptin was recognized as a player in MS pathophysiology and moreover cognitive decline. We aimed to investigate association of genetic variants in leptin (LEP) rs7799039, its receptor LEPR rs1137101 and proliferator-activated receptor gamma co-activator 1-alpha (PGC1A) rs8192678 with IR parameters (HOMA-IR index, area under the curve for insulin and glucose, Cederholm insulin sensitivity index (IS<sub>Iced</sub>), the insulinogenic index in the first 30 min of oral glucose tolerance test (OGTT) in patients with MS. Seventy eight relapsing-remitting patients in clinical remission, free of corticosteroids for at least three months, were included in the study. None of the 3 variants' genotypes were associated with HOMA-IR index, area under the curve for insulin and glucose and the insulinogenic index in the first 30 min of OGTT. PGC1A variant was significantly associated with IS<sub>Iced</sub> (Kruskal-Wallis ANOVA, p = 0.04). Leptin gene variant was significantly associated with impaired GT (p=0.029 adjusted for gender and other two variants). None of the variant showed association with IR. In conclusion, we found that genetic variants in leptin signalling pathway affect glucose tolerance and insulin sensitivity in patients with MS. As both, leptin and PGC1A have role in preventing neuronal death and reducing oxidative stress neuronal damage current results favour further investigation toward preserving cognitive status and neuroprotection in MS.



## Neurodegenerative Diseases

### COGNITIVE IMPAIRMENT AND ISCHEMIC VASCULAR LESIONS IN PATIENTS WITH MULTIPLE SYSTEM ATROPHY

**Alexandru-Octavian Centea**<sup>2</sup>, Orsolya Centea<sup>1</sup>, Lacramioara Perju-Dumbrava<sup>1,2</sup>

<sup>1</sup>Neurology, "Iuliu Hatieganu University of Medicine and Pharmacy Cluj-Napoca, Romania

<sup>2</sup>Neurology, Emergency County Hospital Cluj-Napoca, Romania

It is limited knowledge about the contribution of ischemic vascular lesions to the development of cognitive impairment in patients with multiple system atrophy.

We searched in the archive of the Emergency County Hospital of Cluj-Napoca patients diagnosed with multiple system atrophy, who had a neurocognitive evaluation (Mini Mental State examination) and a neuroimaging evaluation (brain CT scan or brain MRI).

We identified 16 patients diagnosed with multiple system atrophy in the period 2012-2022. 68% of the patients with multiple system atrophy (n=11) had small ischemic subcortical vascular lesions. Just 36% of the patients with ischemic vascular lesions (n=4) had MMSE=26. We found no association between the presence of small ischemic vascular lesions and cognitive dysfunction in patients with multiple system atrophy (rs=0,07).

There is no association between the presence of small ischemic vascular lesions and cognitive impairment in patients with multiple system atrophy, suggesting the cognitive impairment occurs due to the neurodegenerative processes, not due to the neurovascular lesions.

### EVOLVING ROLE OF PET-MRI BRAIN IN NEURODEGENERATIVE DISEASES

**Dinesh Chaudhari**<sup>1</sup>, Pushpendra Nath Renjen<sup>1</sup>, Amarnath Jena<sup>1</sup>, Prerana Rana<sup>1</sup>, Kamal Ahmad<sup>1</sup>, Anjali Mishra<sup>2</sup>

<sup>1</sup>Neurosciences and Nuclear Medicine, Indraprastha Apollo Hospital New Delhi, India

<sup>2</sup>Critical Care Medicine, Holy Family Hospital, New Delhi, India

PET in neurodegenerative diseases delivers early and sensitive readouts of neural tissue loss, and more specific PET tracers currently in use clinically target  $\beta$ -amyloid plaques or dopaminergic deficiency.

Case-1: 56-year-old female presented with the imbalance and an acute episode of vertigo three years back. She was clinically suspected of Atypical Parkinson's disease. The DOPA PET/MRI revealed reduced & patchy DOPA uptake in the bilateral striatum.

MRI study showed mild frontoparietal cortical atrophy and mildly prominent folia in the cerebellum. All of these features helped us to point it towards the MSA-C, which was further confirmed by the 18F-FDG study, which showed regional FDG hypometabolism in bilateral frontal, parietal & temporal lobes and bilateral cerebellum.

Case 2: 67-year-old male presented gait imbalance, slurring speech and dysdiadochokinesia for the last 2 years. He was clinically suspected of Atypical Parkinson's disease. The DOPA PET/MRI decreased DOPA uptake in bilateral putamen and caudate nucleus. MRI study showed bilateral temporal lobes, including the bilateral hippocampus, were symmetrical and had no apparent volume loss or focal abnormal signal intensity. The midbrain/pons ratio was noted (0.47) with a positive hummingbird sign. The bilateral cerebellum was unremarkable; the third ventricle appears mildly prominent. All of these features, when put together, help us to point it towards the PSP.

Conclusion: Combined brain PET/MRI can improve basic research of neurodegenerative diseases and anti-neurodegeneration drug testing.

### ANTI-NMDAR ENCEPHALITIS ASSOCIATED WITH TERATOMA REFRACTORY TO TREATMENT

**Dominika Horková**, G. Krastev, Z. Števková

Neurological Department, Faculty Hospital Trnava, Slovakia

Anti-NMDAR encephalitis is a rare autoimmune, sometimes also a paraneoplastic disorder occurring mostly amongst young women. Ovarial teratoma is the most common type of tumor associated with this disease. During the course of this illness, antibodies are produced as a reaction to presence of neuronal tissue and NMDA receptors in teratoma. These antibodies reacts with subunits of NMDA receptor, which are expressed primarily in hippocampus and forebrain. Clinical manifestations are rapidly progressive neuropsychiatric symptoms such as hallucinations, delusions, behavioural change, impaired

consciousness, motor disturbance, seizures and autonomic dysfunction. As a potentially life threatening and very rare disease, we would like to present a case of 25-years old patient refractory to treatment. Because the failure of first and also a second line treatment, based on isolated cases from foreign workplaces, we proceed to intratecal application of Methotrexate as “ultimum refugium” treatment with success resulting in recovery of our patient.

#### **PATHOGENIC VARIANT IN THE OPTN GENE IN A PATIENT WITH FRONTOTEMPORAL DEMENTIA WITHOUT ALS**

**I. Jacheva**<sup>5</sup>, Sh.Hasani<sup>2,5</sup>, S. Gjorgjieva<sup>3</sup>, A. Stojanoska Trajceska<sup>4,5</sup>, G. Novotni<sup>5</sup>, N. Tanovska<sup>5</sup>, F. Stojkova<sup>5</sup>, D. Plaseska Karanfilska

<sup>1</sup>*Department of Neurology, Public Health Centar-Vinica, Republic of North Macedonia*

<sup>2</sup>*Department of Neurology, Public Health Centar-Skopje, Republic of North Macedonia*

<sup>3</sup>*Department of Neurology, General Hospital-Veles, Republic of North Macedonia*

<sup>4</sup>*Department of Neurology, General Hospital-Prilep, Republic of North Macedonia*

<sup>5</sup>*University Clinic of Neurology, Clinical Centre “Mother Theresa”-Skopje, Republic of North Macedonia*

<sup>6</sup>*Research Center for Genetic Engineering and Biotechnology, Georgi D.Efremov” - Skopje, Macedonian Academy of Sciences and Arts, Republic of North Macedonia*

**Background:** Frontotemporal Dementia (FTD) is a heterogeneous progressive neurodegenerative syndrome with diverse clinical phenotypes associated with multiple neuropathological entities. Behavioral (bv) FTD variant is the most common phenotype.

**Methods:** A case study discussing on the pathogenic variant in the optineurin gene in a 54-year-old male with bv frontotemporal dementia, presented.

**Case study:** We present the disease history of a 54 yo male, with progressive cognitive decline and behavioral changes for the past two years. He experienced difficulties in interpreting a clock, handling money, sweet food cravings, talking to one’s own image in the mirror, difficulty in finding words and pronunciation, followed by emotional reaction and inappropriate content.. Based on the clinical feature, the diagnosis of bv FTD, was suspected. Following the

diagnostic work-up (brain MRI, laboratory analyses, neurocognitive examination, CSF biomarkers for dementia and brain SPECT) the diagnosis was confirmed. WES (Whole genome sequencing) was performed, revealing a pathogenic variant in the optineurin gene (c.403GT,p(Glu135Ter). At this stage of the disease, the patient has no signs that would imply a diagnosis of ALS. No similar cases have been reported in the family.

**Conclusion:** Mutations in MAPT, GRN and C9orf72 are found in 60% of familial FTD cases, and other genes such as optineurin (OPTN) have rarely been reported. Mutations in OPTN mostly have been reported in familial and sporadic cases of ALS, or in rare cases of FTD-ALS, but not in association with pure or predominant FTD and/or parkinsonian phenotype. Even though, in near future, there might not be a cure for most of them, disclosing the correct diagnose and offering genetic counseling is of no less importance

**Keywords:** FTD, optineurin (OPTN), ALS

#### **BOTULINUM TOXIN TREATMENT OF JAW OPENING DYSTONIA USING ULTRASONOGRAPHY IN PROGRESSIVE SUPRANUCLEAR PALSY**

**Hyojung Kang**, E An, H Kim

*Department of Physical Medicine and Rehabilitation, Veterans Health Service Medical Center, South Korea*

**Purpose:** Oromandibular dystonia (OMD) is an infrequent condition in progressive supranuclear palsy (PSP), which may results in dysfunctional movements of facial muscles and temporomandibular joint. Whereas medical treatment usually showed a little effect on dystonia, botulinum toxin injection has been focused on an alternative treatment for OMD. In this case, we aim to report the treatment of jaw opening dystonia with botulinum toxin A in PSP using ultrasonography

**Methods:** A 64-year-old man presented with tonic, extended dystonia of axial and OMD, open jaw type. He was diagnosed as PSP in 2014, and prescribed many medicines for spasticity and dystonia since then. He was suffering from constant opened jaw, which results in poor mastication, dry mouth and impaired communication. However, there was no re-

sponse on medications. Then, the patient was treated with injection of botulinum A toxin (BOTOX®) at the lateral pterygoids and the anterior digastric muscles involved in jaw opening dystonia using ultrasonography (Accuvix XQ, Medison, Seoul, Korea) (Fig. 1). Botulinum A toxin was injected at two points in each lateral pterygoid and digastric muscle, total 50 units in both sides.

**Results:** Before the procedure, the patient showed constant open jaw state (Fig. 2-A). After the injection, the patient showed much improved jaw movement with a voluntary jaw movement, and even full closed jaw (Fig. 2-B).

**Conclusion:** Botulinum A toxin injection at dystonia muscles can be susceptible treatment in cases with poor response in oral medications.

#### **CONDITIONING AGAINST COGNITIVE IMPAIRMENT: PRESENT EVIDENCE AND FUTURE DIRECTIONS**

**H Kim**, B Choi, D Back

*Dept of Neurology, Konkuk University Hospital, South Korea*

Conditioning medicine is an emerging field of therapeutics. Remote ischemic conditioning, initially developed to protect the heart, is now being applied to the brain and other solid organ transplantations, such as those of the heart, kidney, liver, and lungs. As sublethal ischemic injury could act as a beneficial stimulus to activate ischemia-associated diverse protective mechanisms, ischemic preconditioning may be ideal for diseases with vascular compromised conditions, such as stroke, coronary heart disease, or peripheral vascular disease. Vascular dementia, Alzheimer's disease, and mixed dementia are the most common types of cognitive impairment. Considering the insidious onset and chronic progressive nature of the cognitive impairment, conditioning methods for cognitive impairment should be safe, feasible, cost-effective, and long-term applicable. Here, we reviewed current experimental evidence on the effects of remote ischemic conditioning, intermittent brain ischemic conditioning, exercise-induced conditioning, pharmacological (chemical) conditioning, and hypoxic conditioning against cognitive impairment. The results of clinical studies and trials focusing on conditioning as a cognitive therapeutic option have also been included in this review.

The effects of conditioning against cognitive impairment can be better understood with more experimental evidence and clinical applications. In addition to the effects of conditioning on the vascular aspect of cognitive impairment, further studies focusing on various conditioning effects on the chronic neurodegenerative aspect of cognitive impairment are needed.

#### **ADULT ONSET NEURONAL INTRANUCLEAR INCLUSION DISEASE (NIID) THAT PRESENTED WITH GAIT DISTURBANCE**

**Eungseok Oh**

*Neurology, Chungnam National University Hospital and School of Medicine, South Korea*

62-years old patient visited the movement disorder clinic for her gait disturbance. She fell in her home 2 years ago and then she thought that her gait disturbance occurred at that time. Recently, she had dysarthria and clumsiness of right hand. She had no familial history of neurodegenerative and psychiatric diseases. She denied any medical diseases. She showed bradykinesia, mild dysmetria of the left hand, and decreased finger tapping on both hands. Her gait showed imbalance, mild wide based gait and abnormal Tandem gait. And resting and postural tremor of all limbs and any dystonia were not observed. She admitted and evaluated for the gait imbalance and mild parkinsonism. The UPDRS part III score were 19, Copper, ceruloplasmin, vitamin B12, E levels and tumor markers were normal. Paraneoplastic antibody, chest CT, abdominal pelvic CT and FP-CIT PET were normal. Autonomic function test was normal however memory, visuospatial function, language and frontal executive function were severely decreased. We evaluated brain MRI and found out high signal intensities in corticomedullary junctions in DWI. We had further evaluation for the adult onset neuronal intranuclear inclusion disease with skin biopsy and genetic test. We obtained patient's skin at the thigh, calf and shin and done the immunostaining of P62, ubiquitin and SUMO1. There were a few ubiquitin and SUMO1 immunopositive inclusions were observed. In the NOTCH2NLC gene, GGC expansion was 107 repeats. She is managing with donepezil and amantadine for the cognitive impairment and gait imbalance. Her symptoms are not severely aggravated till now.

### CASE REPORT: A CASE REPORT OF SPORADIC CREUTZFELDT-JAKOB DISEASE (SCJD)

**Meri Papajani**<sup>1</sup>, B. Qazimllari<sup>2</sup>, E. Spaho<sup>4</sup>, A. Kuqo<sup>1</sup>, S. Grabova<sup>1</sup>, A. Rroji<sup>3</sup>, F. Elezi<sup>2,4</sup>, J. Kruja<sup>1,2</sup>

<sup>1</sup>Neurology Service, UHC “Mother Teresa”, Albania

<sup>2</sup>Neurology Service, University of Medicine, Faculty of Medicine, Albania

<sup>3</sup>Neuroimaging Service, UHC “Mother Teresa”, Albania

<sup>4</sup>Psychiatry Service, UHC “Mother Teresa”, Albania

**Introduction:** CJD is a rare neurodegenerative disease with a fatal prognosis. It can present with a myriad of clinical signs and symptoms, predominantly rapidly progressive dementia, visual disturbance, pyramidal, and extrapyramidal signs. Here we present the case of a 57-year-old Albanian female, resident in the USA, who presented to “Mother Teresa” Hospital with psychiatric symptoms. Rapid progression to akinetic mutism, brain magnetic resonance imaging (MRI), and cerebrospinal fluid (CSF) findings lead us to the diagnosis of CJD. **Case report:** A 57-year patient presented with a 4-month history of color perception disturbance, boredom, anxiety, depression, inability to concentrate, difficulty speaking and walking, and involuntary movements of superior limbs with progressive worsening. Her first MRI was performed in the USA and ophthalmologic examinations were normal. Her past medical history was significant for well-controlled hypertension, diabetes mellitus type 1, hypothyroidism. She presented to our hospital with akinetic mutism. MRI performed during hospitalization showed increased signal in lateral caudate nuclei bilaterally. 14-3-3 protein on CSF examination was positive. Anti-NMDA receptor, anti-GAD – antibodies resulted negative. Blood neuron-specific enolase was increased. Tumor markers, copper metabolism tests, serology for COVID-19, HIV, and *Borrelia burgdorferi* were also negative. EEG showed nonspecific disorganized rhythm. She developed multiple infectious complications and died 60 days after her admission. **Conclusion:** Initial clinical presentation of sCJD can mimic psychiatric disorders, autoimmune encephalitis, Lyme encephalopathy, or Wilson disease. Initial workup can be nonspecific. It is important to repeat examinations in patients with a progressive decline of neurologic status to confirm the diagnosis and to exclude other treatable conditions.

### AUTONOMIC NERVOUS SYSTEM DISORDERS IN PATIENTS WITH NEURODEGENERATION WITH BRAIN ACCUMULATION ASSOCIATED WITH C19ORF12 GENE MUTATION.

**Marcel Rydzewski**, M. Rydzewski, M. Skowrońska, T. Litwin, A. Antos<sup>1</sup>, A. Członkowska, I. Kurkowska-Jastrzębska, J. Bembenek

<sup>2</sup>2nd Department of Neurology, Institute of Psychiatry and Neurology, Poland

**Introduction:** Mitochondrial protein-associated neurodegeneration (MPAN) is a sub-type of neurodegeneration with brain accumulation and is associated with C19orf12 gene mutation. Patients present with numerous symptoms, including dystonia, parkinsonism, optic nerve atrophy or dementia. Recent scientific reports suggest presence of abnormalities in R-R interval variation (RRIV) in patients monitored through electrophysiological tests.

**Methods:** 25 MPAN patients (8 women, 17 men) with confirmed C19orf12 mutation were included in this study of early signs of dysautonomia. Electrophysiologic tests were performed in all cases and included measurement of skin sympathetic response (SSR) and RRIV during normal breathing and hyperventilation. Additionally, 24-hour monitoring of blood pressure was performed in terms of presence of dysregulations in physiological night BP drop.

**Results:** Among all patients, in 23 cases (92%) aberrations in the functioning of autonomic nervous system (ANS) were noticed. The results of SSR were abnormal in 22 patients, while results of RRIV during normal breathing and hyperventilation were decreased in 10 patients. One person was diagnosed with night hypertension, while 9 patients showed no physiological night BP drop during sleep (“non-dippers”).

**Conclusions:** The abnormalities in ANS were noted in most MPAN patients. There is no sufficient data to determine the level of damage of ANS, which might affect both central nervous system and peripheral ganglia too. Stratification of cardiovascular risk in MPAN patients based on early damage of ANS needs further research, as it might reveal predispositions to severe heart arrhythmias and risk of sudden cardiac death in the future among patients.



## Neuroimmunology

### **IMMUNOGENICITY OF BOTULINUM TOXIN FORMULATIONS: POTENTIAL THERAPEUTIC IMPLICATIONS**

**W. Carr**<sup>1</sup>, Josh Bytheway<sup>1</sup>, N. Jain<sup>2</sup>, J. W. Sublett<sup>3</sup>

<sup>1</sup>*Southern California Research, Allergy and Asthma Associates of Southern California, USA*

<sup>2</sup>*Allergy, Arizona Allergy & Immunology Research LLC, USA*

<sup>3</sup>*Allergy, Family Allergy and Asthma, USA*

Background: Botulinum neurotoxins (BoNT) are proteins produced by bacteria of the Clostridium family. Upon oral ingestion, BoNT causes the neuro-paralytic syndrome botulism. There are seven serotypes of BoNT (A-G); BoNT-A and BoNT-B are the serotypes utilized for therapeutic applications. BoNT injections are used to manage chronic medical conditions across multiple indications. As with other biologic drugs, immunogenicity after long-term treatment with BoNT formulations may occur, and repeated use may elicit antibody production leading to reduced efficacy. Thus, approaching BoNT treatment of chronic conditions with therapeutic formulations that minimize immunogenicity while balancing patient responsiveness to therapy is ideal. Reduction in immunogenicity and anti-biologic antibody production has been achieved through engineering smaller protein constructs and reducing unnecessary formulation components. A similar approach has influenced the evolution of BoNT formulations.

Objective: To describe the basic science of immunogenicity as a potential clinical barrier to the efficacy of biologic therapies and the evolution of BoNT formulations.

Methods: Three BoNT-A products and one BoNT-B product have been approved by the Food and Drug Administration for therapeutic use: onabotulinumtoxinA, abobotulinumtoxinA, incobotulinumtoxinA, and rimabotulinumtoxinB. Additionally, daxibotulinumtoxinA and prabotulinumtoxinA are BoNT-A products that have been approved for aesthetic indications but not therapeutic use.

Results: Available nonclinical and clinical evidence of immunogenicity and clinical nonresponsiveness associated with different BoNT formulations are summarized and the potential lower risk of immunogenicity with a second-generation BoNT formulation, incobotulinumtoxinA, is discussed.

Conclusions: We provide an immunological perspective for considering immunogenicity as a factor in choosing a BoNT formulation.

### **MILD ENCEPHALOPATHY WITH REVERSIBLE LESION IN THE SPLENIUM OF CORPUS CALLOSUM AND BILATERAL FRONTAL WHITE MATTER**

**Jeong Ho Han**<sup>1</sup>, Eun Joo Choi<sup>2</sup>

<sup>1</sup>*Neurology, Veterans Health Service Medical Center, South Korea*

<sup>2</sup>*Neuropsychiatry, Evergreen Neuropsychiatry clinic, South Korea*

Background Reversible lesions in splenium of corpus callosum (SCC) with transiently reduced diffusion MR imaging is reported in epilepsy receiving antiepileptic drugs, trauma, high altitude disease, encephalitis and encephalopathy. Sometimes the lesions are company with white matter changes. Case A 59-years old man was admitted with sudden onset severe dysarthria. He had no neurological disorders except severe dysarthria. He fully understood questions, answered them using letters. He stated that he was not using any other drugs or alcohol, nor had toxin exposure or experience of weight loss. The brain MR diffusion weighted image (DWI) showed high signals in the SCC and bilateral fronto-parietal white matter. His symptom was disappeared in 3 hours and the lesions on MRI were disappeared in 7 days. He was admitted with sudden onset central type right facial palsy and dizziness. The brain DWI showed high signals in the SCC and both middle cerebellar peduncle. At this time, he also had no other drugs, alcohol, toxin or infection. His symptom was completely improved in 1 day and the lesions on DWI were also disappeared in 7 days. He had no abnormalities in CBC, blood chemistry, CSF study, and autoimmune markers. Conclusions Some reports presented transient lesions in SCC with many conditions. This case had same changes in SCC with white matters on DWI. But there are some differences in this case. His symptoms were completely recovered in very short times. There is no report about that the recurrent attack in SCC with white matter changes. We can't find out the reasons of his recurrent attack.



**COMBINATION OF TWO NEUROLOGICAL PARANEOPLASTIC SYNDROMES IN A HODGKIN'S LYMPHOMA PATIENT – OPHELIA SYNDROME AND AXONAL LESION OF THE PERONEAL NERVE**

**Ivana Kezic**

*Department of Neurology, General Hospital Pljevlja, Montenegro*

Paraneoplastic syndromes are a group of disorders that can affect any organ systems including central, peripheral and autonomic nervous system. Paraneoplastic neurological syndromes (PNS), as a rare conditions, are not directly caused by tumor itself, but by products of tumor immunological reactions. The most common neurological paraneoplastic form associated with Hodgkin's lymphoma is the cerebellar degeneration, and in fewer cases of limbic encephalitis, dermatomyositis and subacute sensorimotor neuropathies.

We present a case of 72 year old man with the clinical presentation of two different paraneoplastic neurological syndromes associated with Hodgkin's lymphoma - limbic encephalitis and subacute muscle weakness of the right foot caused by an axonal lesion of the right peroneal nerve. The patient tested negative for the most of anti-paraneoplastic antibodies in CSF – NMDA, CASPR2, LGI1, GABA<sub>A</sub>, GABA<sub>B</sub>, AMPA 1,2, DPPX, Hu, Yo, Ri, CV2-CRMP5, Ma2-Ta, GAD and amififizin (unfortunately, our laboratory panel of tested antibodies did not include a test for mGluR5 receptors as highly specific for Hodgkin's lymphoma). The patient showed significant improvement and regression of symptoms and signs of both the central and peripheral nervous system after admission of corticosteroid therapy and specific lymphoma combined chemotherapy.

**MYASTHENIA GRAVIS A THIRD AUTOIMMUNE DISEASE OR JUST A FATIGUE IN A PATIENT WITH MULTIPLE SCLEROSIS?**

**V. Kosta, I. Bilic, K. Caljkusic**

*Department of Neurology, University Hospital Center of Split, Croatia*

A 55-year-old woman with ankylosing spondylitis was diagnosed with relapsing-remitting multiple sclerosis (MS) two years ago. On her regular check-up she was complaining on severe fatigue, especially pronounced in the afternoon. Her EDSS was 3 (mild right sided hemiparesis, truncal ataxia, hemi-

hypesthesia and urinary incontinence). Besides fatigue she did not have any additional muscle weakness. A test for acetylcholine receptor antibodies was positive. Piridostigmin was introduced and her fatigue was less pronounced. The question was it really a third autoimmune disease – a multiple autoimmune syndrome or is it just a false positive result in the patient with MS. Around 40 to 95 percent of individuals suffering from MS are experiencing fatigue. Anti-AChR-binding antibodies are relatively specific for myasthenia gravis, but rarely can be found in patients with other autoimmune diseases as well as neurological disease like dementia, myelitis, epilepsy, stroke, MS, stiff-person syndrome, encephalitis or vasculitis. The situation is a bit more complicated with the fact that about 25 percent of patients with autoimmune diseases tend to develop additional autoimmune diseases. We have to keep in our minds that having one confirmed autoimmune disease increases the probability of having other autoimmune diseases, but also, we must be very careful not to overdiagnose or overtreat our patients.

**GUILLAIN-BARRÉ SYNDROME WITH FACIAL NERVE INVOLVEMENT; AN ATYPICAL PRESENTATION OF COVID-19**

**N. Mitrollari<sup>2</sup>, G. Vyshka<sup>2,3</sup>, A. Rama<sup>2</sup>, B. Qazimllari<sup>2</sup>, A. Kuqo<sup>1</sup>, I. Alushi<sup>2</sup>, S. Dodaj<sup>2</sup>, J. Kruja<sup>1,2</sup>**

*<sup>1</sup>Neurology Service, UHC Mother Teresa, Albania*

*<sup>2</sup>Neurology Service, University of Medicine Tirana, Albania*

*<sup>3</sup>Neurophysiology, UHC Mother Teresa, Albania*

Guillain-Barré syndrome (GBS) is an acute inflammatory polyneuropathy characterized by rapidly progressing symmetrical muscle weakness and loss of deep tendon reflexes which follows a precedent infection. Cranial nerve involvement is seen in 45-75% of patients with GBS. we present a series of five different cases of GBS, all of them sharing two common fetures: bilateral asymmetrical facial neuropathy and a positive Sars-CoV-2 serology. We emphasize the fact that the seventh cranial nerve was the only cranial nerve affected while the other one were spared.

Preliminary studies suggest that GBS when accompanied by facial neuropathy, might have a better final outcome. The small number of cases could be a limitation of our study; however all of the five patients had facial nerve palsy with electrical data sup-

porting GBS in the lower/upper limbs, and the time of recovery was shorter compared to other patients with GBS. This also might have been a peculiarity of COVID-related neural inflammation, with a certain predilection for the facial nerve, showing thereafter a more rapid functional improvement and a better response to conventional therapies.

#### **LONG-TERM SAFETY, TOLERABILITY, AND EFFICACY OF EFGARTIGIMOD IN PATIENTS WITH GENERALIZED MYASTHENIA GRAVIS: INTERIM RESULTS OF THE ADAPT+ STUDY**

James F. Howard, Jr<sup>1</sup>, Vera Bril<sup>2,3</sup>, Tuan Vu<sup>4</sup>, Chafic Karam<sup>5</sup>, **Stojan Peric**<sup>6</sup>, Jan L. De Bleecker<sup>7</sup>, Hiroyuki Murai<sup>8</sup>, Andreas Meisel<sup>9</sup>, Said Beydoun<sup>10</sup>, Mamatha Pasnoor<sup>11</sup>, Antonio Guglietta<sup>12</sup>, Caroline T'joen<sup>14</sup>, Kimiaki Utsugisawa<sup>13</sup>, Renato Mantegazza<sup>15</sup>

<sup>1</sup>*Department of Neurology, the University of North Carolina, USA*

<sup>2</sup>*Ellen & Martin Prosserman Centre for Neuromuscular Diseases, University Health Network, Canada*

<sup>3</sup>*University of Toronto, Toronto, Canada*

<sup>4</sup>*Department of Neurology, University of South Florida Morsani College of Medicine, USA*

<sup>5</sup>*Penn Neuroscience Center, University of Pennsylvania, USA*

<sup>6</sup>*Neurology Clinic, Clinical Center of Serbia, University of Belgrade, USA*

<sup>7</sup>*Ghent, University Hospital, Belgium*

<sup>8</sup>*Department of Neurology, School of Medicine, International University of Health and Welfare, Japan*

<sup>9</sup>*Department of Neurology and NeuroCure Clinical Research Center, Charité – Universitätsmedizin Berlin, Germany*

<sup>10</sup>*Keck School of Medicine, University of Southern California, USA*

<sup>11</sup>*The University of Kansas, Medical Center, USA*

<sup>12</sup>*argenx, Ghent, Belgium*

<sup>13</sup>*Department of Neurology, Hanamaki General Hospital, Japan*

<sup>14</sup>*Argenx, Ghent, Belgium*

<sup>15</sup>*Department of Neuroimmunology and Neuromuscular Diseases, Fondazione IRCCS Istituto Neurologico Carlo Besta, Italy*

Purpose: Efgartigimod, a human IgG1 antibody Fc-fragment, reduces pathogenic IgG autoantibody levels through neonatal Fc receptor blockade. Positive

efficacy results were reported in the phase 3 ADAPT study. Patients completing ADAPT were eligible to enroll in the 3-year, open-label extension, ADAPT+. Objective: evaluate safety and efficacy of efgartigimod in patients with generalized Myasthenia Gravis (MG) enrolled in ADAPT+.

Methods: Efgartigimod (10 mg/kg IV) was administered in cycles of once-weekly infusions for 4 weeks, with subsequent cycles initiated based on clinical evaluation. MG Activities of Daily Living (MG-ADL) and Quantitative MG (QMG) scales assessed efficacy.

Results: Ninety percent of ADAPT patients (151/167) entered ADAPT+. As of February 2021, 106 anti-acetylcholine receptor antibody (AChR-Ab) positive and 33 AChR-Ab– patients had received  $\geq 1$  efgartigimod dose (including 66 receiving placebo during ADAPT). Patients received a mean 5.1 cycles (20.5 infusions) over a median (range) study duration of 371 (50–586) days, resulting in 138 patient-years total observation. Mean cycle duration was 61.4 days (40.4 days between cycles). The most common adverse events were headache (22.3%; 31/139), nasopharyngitis (10.8%; 15/139), and diarrhea (8.6%; 12/139), which were mostly mild or moderate. In cycle 1, a mean change (mean [SE]) of  $-5.1$  (0.32) in MG-ADL and  $-4.8$  (0.36) in QMG were observed, with similar results during each cycle ( $\leq 10$  cycles). Repeated reductions in total IgG and AChR-Abs were observed across cycles.

Conclusions: These analyses suggest long-term efgartigimod treatment results in consistent decrease in IgG antibodies and repeatable improvement in function and strength.

#### **ACUTE TRANSVERSE MYELITIS FOLLOWING COVID-19 INFECTION**

**Eni Reka**<sup>1</sup>, Altin Kuqo<sup>3</sup>, Arben Rroji<sup>2</sup>, Jera Kruja<sup>3</sup>

<sup>1</sup>*Neurology, UHC Mother Theresa, Albania*

<sup>2</sup>*Neuro-imaging, UHC Mother Theresa, Albania*

<sup>3</sup>*Neurology, University of Medicine, Faculty of Medicine, Albania*

Acute transverse myelitis (ATM) or long extensive transverse myelitis (LETM) were found to be associated with COVID-19, along with other neurologic complications like confusion, delirium, headache, ageusia, anosmia, stroke, and in rare cases, seizures

and epilepsy. We describe a case of acute transverse myelitis following acute COVID-19. It is important to consider SARS-CoV-2 infection as a potential trigger of postinfectious myelitis in cases presented with spastic paraplegia with urinary retention and positive testing for COVID-19 when other viral or autoimmune etiological factors are ruled out. This patient improved with corticosteroid therapy. Our case shows that improvement might also occur with moderate steroid treatment, avoiding high doses because of uncertain effects on the immunogenic elimination of SARS-CoV2. We aim to increase awareness of such a neurologic complication following COVID-19 although it is unclear whether post-infectious myelitis after COVID-19 behaves differently from other virus infections.

#### **EFGARTIGIMOD: A NOVEL FCRN ANTAGONIST IN THE TREATMENT OF AUTOIMMUNE DISEASES**

**Filippo Rocca**, Peter Ulrichs

*Medical Affairs, Argenx, Belgium*

**Introduction:** Immunoglobulin G (IgG) autoantibodies are key in autoimmune diseases pathogenesis, including immune thrombocytopenia (ITP), pemphigus vulgaris, and neurological conditions: generalized myasthenia gravis (gMG) chronic inflammatory demyelinating polyneuropathy (CIDP) and myositis.

**Methods:** The neonatal Fc receptor (FcRn) is the central regulator of IgG homeostasis. Efgartigimod, an FcRn antagonist, human IgG1-derived Fc-fragment, outcompetes endogenous IgG binding, reduces recycling and increases IgG degradation, including all IgG subtypes, without impacting other immunoglobulins or albumin, making it a potential treatment for IgG-mediated disorders.

**Results:** Based on the clinical benefit reported in the Phase 3, ADAPT study, efgartigimod is approved for treatment of adult patients with anti-acetylcholine receptor antibody positive gMG in several countries. Ongoing studies include: phase 3 studies in ITP (ADVANCE and ADVANCE SC), pemphigus vulgaris and foliaceus (ADDRESS), and phase 2/3 studies in CIDP (ADHERE), bullous pemphigoid (BALLAD), and myositis (ALKIVIA). ADVANCE met the primary endpoint with higher, sustained platelet response with efgartigimod versus placebo.

Across all completed studies to date, efgartigimod reduced total IgG, including pathogenic IgG, corresponding to clinical improvements in each population. Efgartigimod safety is consistent, with comparable treatment emergent adverse event (TEAE) rates to placebo (ADAPT 77.4% efgartigimod/84.3% placebo; ADVANCE 93.0% efgartigimod/95.6% placebo; 85% of participants open-label pemphigus study). Most TEAEs were mild to moderate in severity. Efgartigimod was well tolerated in ADAPT+ extension study, with no increase in TEAE incidence rates or infections with up to 19 treatment cycles.

**Conclusion:** FcRn inhibition by efgartigimod is a promising therapeutic option for autoimmune diseases mediated by pathogenic IgG autoantibodies.

#### **4 WEEKS, 3 THERAPIES, 2 HEMISPHERES - A DIFFICULT ADEM DIAGNOSIS AND TREATMENT**

**A.C. Tanasoiu**<sup>1</sup>, D. Tulba<sup>1,2</sup>, B.O. Popescu<sup>1,2,3</sup>

<sup>1</sup>*Department of Neurology, Colentina Clinical Hospital, Romania*

<sup>2</sup>*Faculty of Medicine, "Carol Davila" University of Medicine and Pharmacy, Romania*

<sup>3</sup>*Laboratory of Molecular Medicine, "Victor Babeş" National Institute of Pathology, Romania*

Acute disseminated encephalomyelitis is an immune-mediated inflammatory disease usually triggered by an infection or immunization. A humoral and/or cell-mediated response targets the myelin sheath in the brain and spinal cord. The clinical presentation involves mostly multifocal neurologic deficits and encephalopathy, reaching the nadir time two weeks after clinical onset.

We present the case of a 54-year-old man known with arterial hypertension who was referred from a secondary care center. He was found unconscious one month prior and treated for aspiration pneumonia, with worsening confusion afterwards. Having received high dose methylprednisolone pulse therapy, his mental status continued to deteriorate. At admission, the patient had global aphasia and psychomotor agitation, without focal neurologic deficits. Laboratory work-up (including blood and CSF) for metabolic, toxic, infectious, lymphoproliferative, and systemic/primary CNS autoimmune disorders was unremarkable. Noteworthy, anti-MOG antibodies were negative. Brain MRI identified su-

pratorial large confluent hyperintense T2/FLAIR lesions distributed throughout the white matter and globus pallidus, sparing the cortex, without restricted diffusion or contrast enhancement. No improvement with intravenous immunoglobulin was noted, but there was a spectacular response to plasma exchange. At discharge, the patient was able to speak fluently, with complex sentences.

Although widely covered in medical literature, acute disseminated encephalomyelitis can still raise

diagnostic and therapeutic challenges. A clinical presentation without focal neurologic deficits and progression to nadir in more than one month should not exclude this diagnosis. Moreover, inadequate response to glucocorticoids and intravenous immunoglobulin should prompt plasma exchange, provided that alternate diagnoses were excluded.



## **Neuromyelitis Optica Spectrum Disorders (NMOSD)**

## **PHENOTYPES DIFFERENCES IN PATIENTS WITH NEUROMYELITIS OPTICA SPECTRUM DISORDERS**

**Irene Gómez Estévez**, Lorena García Vasco, Johnny Adrian Sánchez Quezada, Sara Cabanillas Sanz, Clara Gonzalez Gallego, Celia Oreja-Guevara  
*Neurology, Hospital Clínico San Carlos, IdiSSC, Madrid, Spain*

**Introduction:** In 2015 The International Panel for NMO Diagnosis published the International consensus diagnostic criteria for neuromyelitis optica spectrum disorders. However, there are still patients with AQP4-seronegative difficult to classify.

**Objetives:** We analyze our cohort of NMOSD patients to study the demographic, clinical characteristics, MRI and CSF.

**Results:** 19 patients have been diagnosed with NMOSD, 9 with CRION spectrum, 1 with RION, 4 monophasic longitudinally extensive transverse myelitis lesions (LETM) and 3 with monophasic neuritis optica (NO), one MOG-Ab positive.

6 NMOSD are AQP4-seropositive (mean age at diagnosis: 41). The first outbreak was NO in 16,67%, bilateral NO (BNO) in 33%, acute myelitis in 16,67%, area postrema syndrome (APS) in 33,33%. The mean time to the second outbreak was 3 months to NO, 18 to NOB and 5 to APS. Oligoclonal bands (OB) were negative in all patients. The MRI brain was normal in the first outbreak in one patient.

13 NMOSD are AQP4-seronegative (mean age at diagnosis: 36). The first outbreak was NO in 7,69%, BNO in 7,69%, LETM in 53,85%, APS in 7,68%, acute brain syndrome in 7,69% and LETM + NOB in 15,38%. OB were positive in 38%. The MRI brain was normal in the first attack in 38,42%. 4 NMOSD patients received treatment after the first outbreak. The mean time to the second outbreak for treated patients was 61 months and for untreated 32,72 ( $p=0,123$ ). In untreated patients, no association was found between the type of the first outbreak and the time elapsed until the second outbreak ( $p=0,363$ ).

4 CRION are MOG-seropositive (mean age at diagnosis: 39). The first outbreak was NO in all patients. All patients are corticosteroid dependent. MRI brain was normal in all of the patients.

5 CRION are MOG-seronegative (mean age at diagnosis: 35). The first outbreak was NO in 90% and BNO in 10%. All patients are corticosteroid dependent.

MRI brain shows a nonspecific changes in 10% patients.

OB were negative in all of the CRION.

**Conclusions:** It seems that there are some specific characteristics in each group. MRI and CSF results differ among the four groups. We found that patients who receive early treatment are less likely to have a new outbreak. Early characterization of patients with NMOSD is important to reduce relapse and disability.

## **A CASE OF AREA POSTREMA SYNDROME ASSOCIATED WITH SYNCOPES IN A YOUNG WOMAN: CASE REPORT.**

**Triin Helin Unt**

*Faculty of Medicine, University of Tartu, Estonia*

**Background:** Lesions to area postrema may lead to area postrema syndrome (APS) which is defined as intractable nausea, vomiting, or hiccups, which persist for at least 48 hours. Since 2015 it is considered as one of the core clinical characteristics for neuromyelitis optica spectrum disorders (NMOSD), a group of CNS inflammatory autoimmune demyelinating diseases.

**Case presentation:** Previously healthy, active 41-year-old woman was admitted due to complaints of progressive nausea for 3 weeks, vomiting and persistent hiccups that had appeared on admission day. During monitoring in the emergency department she experienced an episode of bradycardia (27 bpm) followed by a syncope. She was admitted to cardio-ICU and was fitted with a temporary cardio stimulator. As the episodes with loss of consciousness persisted a possible CNS pathology was suspected. Head MRI with contrast enhancement showed multiple demyelinating white matter lesions, one being located in area postrema. CSF analysis showed pleocytosis of  $10 \times 10^6/L$ , with normal levels of protein, lactate and glucose. Result for oligoclonal band was indeterminate. Analyses for aquaporin-4 and MOG antibodies were negative. With high-dose intravenous methylprednisolone treatment the patient's condition improved. After 3 months she remained without neurological finding. Repeat MRI was comparable with the previous scan.

**Conclusion:** In this case the diagnosis criteria for NMOSD is not yet met and area postrema syndrome

remains the diagnosis for the meantime. As APS is commonly encountered either in isolation or accompanying other symptoms at onset or during the course of the NMOSD, the patient remains on observation for further developments.

## **ROLE OF THE MEASURE OF THE PLANTAR FASCIA THICKNESS IN REHABILITATION SCIENCE**

**Sedegheh Malek Mohammadi**

*Orthotics and Prosthetics, Faculty of Orthotics and Prosthetics Research Clinic, Iran*

The objective of this research is evaluating plantar fascia thickness along its length in equivalent locations in both feet to calculate the amount of the load (body weight) applied on the foot in static and locomotion in living individual. Plantar fascia has long been connected to the kinematics and kinetics qualities of the ankle and foot. It is believed quantified plantar fascia thickness is a location to quantify the amount of the applied body weight on identified location on the foot in static and locomotion, in living individual. Additionally, it has been accepted that thickness of the plantar fascia is different along the length of the plantar fascia and plantar fascia thickness is unlike in equivalent locations in both feet.

Method: 1) plan of investigation was designed based on six landmarks and three reference lines to identify the location of the plantar fascia along its length, 2) thickness of the plantar fascia was scanned through Ultra Sound 2D measuring in unloading position and before modification. Plantar fascia thickness was scanned in sagittal and frontal planes to be quantified with Image J software, 3) per plan of investigation, pressure markers were put on identified locations of the plantar fascia. The amount of the applied pressure was assessed with E-med, in static and locomotion, 4) Qualysis, The percentage of the body weight was calculated in identified locations. Data was collected simultaneously through Emed and Qualysis in static and locomotion. It was found that quantifying the amount of the applied load in identified location of the plantar fascia is achievable, individually.

The outcome of quantitative information of an individual with 65 kg weight was; plantar fascia thickness [(1.1 ± 0.6mm) longitudinally (1.4 ± 0.2mm) and (1.2 ± 0.6mm) transversely (1.4 ± 0.2mm)], [(41.3 ± 4.5) (79.3 ± 17.5)] ,[(0.6% ± 0.18%) (1.1% ±

0.27%)]. Appropriately, insoles, medical shoes, foot and lower limb orthoses can be designed and aligned as close as possible to the biological qualities of the movements of each user.

## **ASSOCIATION OF B-CELL SUBSETS AND AQUAPORIN-4 ANTIBODY TITERS WITH DISEASE ACTIVITY IN PARTICIPANTS IN THE N-MOMENTUM TRIAL RECEIVING INEBILIZUMAB TREATMENT**

**Kristina Patterson**<sup>1</sup>, Michael Smith<sup>2</sup>, William Rees<sup>2</sup>, Friedemann Paul<sup>3</sup>, Ho Jin Kim<sup>4</sup>, Sean Pittock<sup>5</sup>, Bruce Cree<sup>6</sup>, Jeffrey Bennett<sup>7</sup>

<sup>1</sup>*Medical Affairs and Outcomes Research, Horizon Therapeutics, USA*

<sup>2</sup>*Research and Development, Horizon Therapeutics, USA*

<sup>3</sup>*Neurology, Experimental and Clinical Research Center, Max Delbrueck Center for Molecular Medicine and Charité – Universitätsmedizin, Germany*

<sup>4</sup>*Neurology, Research Institute and Hospital of National Cancer Center, South Korea*

<sup>5</sup>*Neurology, Mayo Clinic and Center for MS and Autoimmune Neurology, USA*

<sup>6</sup>*Neurology, UCSF Weill Institute for Neurosciences, USA*

<sup>7</sup>*Neurology, University of Colorado School of Medicine, Anschutz Medical Campus, University of Colorado, USA*

Background: Inebilizumab (INEB), an anti-CD19 B-cell-depleting antibody, is approved to treat neuromyelitis optica spectrum disorder (NMOSD). We evaluated the relationship between peripheral blood B-cell subsets and aquaporin 4 (AQP4) immunoglobulin G (IgG) titers and NMOSD attacks in participants of N-Momentum (NCT02200770).

Methods: Participants received INEB 300 mg or placebo on days 1 and 15 during the randomized controlled period (RCP) and every 6 months in the optional open-label period. Absolute counts of CD20+ B cells and CD27+ memory B cells, plasma cell (PC) gene expression, and AQP4-IgG titers were determined in peripheral blood.

Results: In placebo-treated participants, CD20+ B cells (P0.01) and CD27+ memory B cells were increased during an NMOSD attack relative to the preceding study visit. The PC signature was already

increased at the preceding visit relative to baseline ( $P=0.016$ ). During attack, a 2-fold increase from baseline was seen in 20% for CD20+ B cells, 16% for memory B cells, and 57% for PCs. Among INEB-treated participants, B-cell subsets were significantly decreased and did not increase significantly during attack relative to the preceding visit. Changes in AQP4-IgG titer from baseline to attack did not differ significantly between treatment groups ( $P=0.15$ ). At RCP end, 9/50 (18%) placebo-treated participants vs 59/159 (37%) INEB-treated participants ( $P=0.014$ ) had  $\geq 2$ -fold decrease in AQP4-IgG (0% vs 11%  $\geq 8$ -fold decrease,  $P=0.008$ ).

Conclusion: B-cell subset levels increased during attack in the placebo but not INEB group, particularly in the PC subset. Inebilizumab treatment was associated with reduction in AQP4-IgG in a subset of participants.

#### **SAFETY AND EFFICACY OF INEBILIZUMAB IN AQP4+ NMOSD PARTICIPANTS WITH HISTORY OF IMMUNOSUPPRESSION TREATMENT PRIOR TO N-MOMENTUM STUDY**

**Friedemann Paul**<sup>1</sup>, Romain Marignier<sup>2</sup>, John Lindsey<sup>3</sup>, Ho Jin Kim<sup>4</sup>, Dewei She<sup>5</sup>, Daniel Cimbora<sup>6</sup>, Kristina Patterson<sup>7</sup>, Bruce Cree<sup>8</sup>  
<sup>1</sup>Neurology, Experimental and Clinical Research Center, Max Delbrueck Center for Molecular Medicine and Charité – Universitätsmedizin Berlin, Corporate Member of Freie Universität Berlin and Humboldt-Universität zu Berlin, Germany  
<sup>2</sup>Neurology, Service de Neurologie, Sclérose en Plaques, Pathologies de la Myéline et Neuroinflammation, Hôpital Neurologique Pierre Wertheimer, Hospices Civils de Lyon, France  
<sup>3</sup>Neurology, Division of Multiple Sclerosis and Neuroimmunology, University of Texas Health Science Center at Houston, USA  
<sup>4</sup>Neurology, Research Institute and Hospital of National Cancer Center, South Korea  
<sup>5</sup>Research and Development, Horizon Therapeutics, USA  
<sup>6</sup>Clinical Development, Horizon Therapeutics, USA  
<sup>7</sup>Medical Affairs and Outcomes Research, Horizon Therapeutics, USA  
<sup>8</sup>Neurology, UCSF Weill Institute for Neurosciences, USA

Introduction: Inebilizumab is approved for the treatment of neuromyelitis optica spectrum disorder (NMOSD) in adults seropositive for aquaporin-4 antibody (AQP4+).

Methods: N-Momentum (NCT02200770) was a 28-week randomized phase 2/3 trial of inebilizumab vs placebo, with an optional Open-Label Extension (OLE). Immunosuppressant medication for the prevention or treatment of NMOSD relapses was allowed prior to Day 1 dosing. In this post hoc analysis, AQP4+ participants who received inebilizumab through the OLE were grouped by no history of immunosuppression therapy beyond treatment of acute NMOSD attacks (naïve, n=103), or prior azathioprine and/or mycophenolate mofetil (AZA/MMF) therapy (n=94).

Results: The total patient-years of inebilizumab treatment in the prior AZA/MMF group was 300.35 and for immunosuppressant naïve participants, 335.7. The annualized relapse rate (95% confidence interval [CI]) for participants with prior AZA/MMF was 0.11 (0.07, 0.17), compared with 0.08 (0.05, 0.14) for naïve. The annualized NMOSD-related inpatient hospitalization rate (annualized rate [95% CI]) for prior AZA/MMF was 0.15 (0.08, 0.27), and 0.12 (0.06, 0.22) for naïve. The percentage of participants with  $\geq 1$  study drug-related treatment-emergent adverse event (AE) was 30.9% (29/94) in prior AZA/MMF and 47.6% (49/103) in naïve; 4.3% (n=4) of prior AZA/MMF and 5.8% (n=6) of immunosuppressant-naïve reported  $\geq 1$  study drug-related serious AE. Most AEs were infection-related for both groups (72.3% [68/94] for prior AZA/MMF and 77.7% [80/94] for naïve).

Conclusions: This analysis evaluating long-term outcomes of inebilizumab in AQP4+ NMOSD participants treated with prior AZA/MMF therapy demonstrated a similar efficacy and safety profile as participants without prior immunosuppressant therapy.





## Other

## SAFETY OF INCOBOTULINUMTOXINA IN PEDIATRICS: A POOLED ANALYSIS

Carrie Foster<sup>1</sup>, M. Banach<sup>2</sup>, E. Dabrowski<sup>3</sup>, D. Gaebler-Spira<sup>4</sup>, H. Chambers<sup>5</sup>, S. Schroeder<sup>1</sup>, T. Geister<sup>6</sup>, M. Althaus<sup>6</sup>, A. Hanschmann<sup>6</sup>, **S. Berweck**<sup>7,8</sup>

<sup>1</sup>*Division of Pediatric Neurology & Lmu Center for Children with Medical Complexity, Dr. von Hauner Children's Hospital, Ludwig-Maximilians-University, Germany*

<sup>2</sup>*Department of Neurology, Collegium Medicum, Jagiellonian University, Poland*

<sup>3</sup>*Beaumont Pediatric Physical Medicine & Rehabilitation – Royal Oak, Beaumont Hospital, Royal Oak, USA*

<sup>4</sup>*Shirley Ryan AbilityLab, Northwestern Feinberg School of Medicine, USA*

<sup>5</sup>*Southern Californian Cerebral Palsy Center, Rady Children's Hospital, USA*

<sup>6</sup>*Medical and Clinical Development, Merz Therapeutics GmbH, Germany*

<sup>7</sup>*Department of Paediatrics, Schoen Klinik Vogtareuth, Germany*

<sup>8</sup>*Department of Paediatrics, Dr. Von Hauner Children's Hospital, Ludwig-Maximilians-University, Germany*

**Background:** BotulinumtoxinA (BoNT-A) is used to treat pediatric conditions, including spasticity and sialorrhea, that often require repeated, long-term therapy. IncobotulinumtoxinA (INCO), a purified BoNT-A formulation, is free of complexing proteins.

**Objective:** To analyse INCO pediatric safety data.

**Methods:** Pooled safety data were analyzed from four phase 3 studies children/adolescents (2–17 years) investigating INCO for the treatment of limb spasticity associated with cerebral palsy [Treatment with IncobotulinumtoxinA in Movement (TIM), Treatment with IncobotulinumtoxinA in Movement Open-label (TIMO), incobotulinumtoxinA in aRm treatment in cerebral palsy (XARA)] or sialorrhea associated with neurological disorders [Sialorrhea Pediatric Xeomin Investigation (SIPEXI)]. INCO doses and number/frequency of injection cycles (ICs) were captured. Methodological details were published previously. Safety endpoints included treatment-emergent adverse events (TEAEs), treatment-related TEAEs, treatment-related serious adverse events (TESAEs), treatment-related adverse

events of special interest (TEAESIs), and TEAEs leading to discontinuation. INCO dose groups were combined.

**Results:** 1159 patients (mean age 7.3 years, 60.4% males, GMFCS levels I-V) received INCO for 2–6 ICs over ≤96 weeks. Overall, 481 (41.5%) experienced a TEAE. Of these, 45 (3.9%) were considered treatment-related, with injection site reactions (1.3%), muscular weakness (0.5%), and dysphagia (0.5%) the most common, and all generally of mild-to-moderate intensity. Two (0.2%) patients with spasticity experienced a treatment-related TESAE and overall four (0.3%) discontinued due to treatment-related TEAEs. Safety event frequencies were similar for both indications.

**Conclusions:** INCO, given repeatedly for up to 96 weeks, was associated with very few treatment-related TEAEs in 1100 children/adolescents of broad age range and GMFCS levels.

## MYASTHENIA GRAVIS AND HASHIMOTO THYROIDITIS IN A PATIENT WITH CHARCOT-MARIE-TOOTH 4C (SH3TC2-HMSN)

**Maja Bozinovska Smicheska**<sup>1</sup>, L. Gogovska<sup>2</sup>

<sup>1</sup>*Neurology, Special Hospital "Sv.Erazmo", Republic of North Macedonia*

<sup>2</sup>*Neurology, Specialized Practice of Neurology "D-r Lodi Gogovska", Republic of North Macedonia*

**Objective/background:** To present a rare case of concurrence of Myasthenia gravis, Hashimoto thyroiditis and CMT4C (SH3TC2-HMSN).

**Case history:** We describe a case of 22 years old female who complained on facial weakness, double vision, abnormal speech, impaired hearing, numbness of hands and feet, hand weakness, difficulties in walking, breathing problems and fatigue. In childhood, she was diagnosed with scoliosis, foot deformities and hip dysplasia and underwent hip arthroplasty 2 years ago. She suffers hypothyroidism as result of Hashimoto thyroiditis and thyroidectomy 5 years ago. Neurological examination at admission revealed well-developed syndrome of chronic sensorimotor polyneuropathy (including impairment of deep and superficial sensations in the feet and hands shading off proximally, distal muscular weakness and atrophy, foot drop), mild proximal muscle and neck muscle weakness, instability of gait as well

as bilateral facial weakness, diplopia and unequal ptosis. Clinically myasthenic fatigue phenomenon was evident and Neostigmin test was positive. Detailed laboratory was performed and anti AChR antibodies were detected. Electrophysiological testing confirmed chronic demyelinating senso-motor polyneuropathy without conductive block and discovered decremental response on repetitive nerve stimulation test. CT of the chest showed thymic hyperplasia. Genetic testing was positive for SH3TC2-HMSN. Treatment with acetylcholinesterase inhibitors, corticosteroids and immunosuppressant drug lead to moderate improvement and less than satisfactory response.

Conclusion: Even extremely rare, recognition of possible association of MG or other neurological autoimmune conditions with CMT, is important because therapeutic response depends on it.

#### **NATURAL DISEASE HISTORY CLINICAL CHARACTERISTIC OF PERSISTENT IDIOPATHIC FACIAL PAIN**

**George Chakhava**<sup>1</sup>, Miranda Demuria<sup>2</sup>, Ia Rukhadze<sup>3</sup>, Otar Koniashvili<sup>3</sup>

<sup>1</sup>*Georgian Association of Medical Specialties, D.Tvildiani Medical University, Multiprofile Clinic Consilium Medulla, Georgia*

<sup>2</sup>*Neurology, Multiprofile Clinic Consilium Medulla, Georgia*

<sup>3</sup>*Neurology, Central University Clinic after Academic N.Kipshidze, Georgia*

Background: This disease, opposed to trigeminal neuralgia, is not associated with neurovascular compression. In our study, we aimed to investigate specific clinical and epidemiological characteristics of PIFP as well as the clinical course of the condition.

Methods: We retrospectively analyzed 17 patients diagnosed with PIFP. The Diagnosis was made according to the International Classification of Headache Disorders of the International Headache society.

Results: 88% of the patients diagnosed with atypical facial pain were female (n=15), and 2 patients were male. In most of the patients (82,3 % - n=14) the pain was localized in one-half of the face. From this patients, 9 individuals reported right-sided and 5 left-sided pain. In the remaining 17.6 % of the pa-

tients (n=3) the pain had bilateral distribution. Most of the patients (41% - n=9) stated that the pain was localized in the Maxillary, Mandibular or Temporal area, while others reported Frontal, Orbital, Parietal, Occipital, Gingival, or Nasal distribution. 64% of the patients described the pain to be dull, the remaining ones reported the presence of sharp pain. The onset of the symptoms ranged from 8 months to 4 years, mean – of 17.8 months (Standard Deviation 10.4).

Conclusion: PIFP is a severe, chronic condition that is episodic in nature and characterized by frequent recurrences and a significant impact on the patient's quality of life, mood, and productivity. Management of PIFP can be quite challenging for healthcare workers since it often demonstrates resistance to multiple medications.

#### **LACK OF IMMUNOGENICITY OF INCOBOTULINUMTOXINA IN PEDIATRICS: A POOLED ANALYSIS**

**F. Heinen**<sup>1</sup>, M. Banach<sup>2</sup>, E. Dabrowski<sup>3</sup>, D. Gaebler-Spira<sup>4</sup>, H. Chambers<sup>5</sup>, S. Schroeder<sup>1</sup>, T. Geister<sup>6</sup>, M. Althaus<sup>6</sup>, A. Hanschmann<sup>6</sup>, S. Berweck<sup>7,8</sup>

<sup>1</sup>*Division of Pediatric Neurology & LMU Center for Children with Medical Complexity, Dr. von Hauner Children's Hospital, Ludwig-Maximilians-University, Germany*

<sup>2</sup>*Department of Neurology, Collegium Medicum, Jagiellonian University, Poland*

<sup>3</sup>*Beaumont Pediatric Physical Medicine & Rehabilitation – Royal Oak, Beaumont Hospital, Royal Oak, USA*

<sup>4</sup>*Shirley Ryan AbilityLab, Northwestern Feinberg School of Medicine, USA*

<sup>5</sup>*Southern Californian Cerebral Palsy Center, Rady Children's Hospital, USA*

<sup>6</sup>*Medical and Clinical Development, Merz Therapeutics GmbH, Germany*

<sup>7</sup>*Neuro-Rehabilitation and Epileptology, Schoen Klinik Vogtareuth, Germany*

<sup>8</sup>*Department of Paediatrics, Dr. Von Hauner Children's Hospital, Ludwig-Maximilians-University, Germany*

Background: BotulinumtoxinA (BoNT-A) is used to treat chronic pediatric conditions, including spasticity and sialorrhea. Repeated use of biologic drugs like BoNT-A can cause antibody formation, and

clinical non-responsiveness. IncobotulinumtoxinA (INCO), a purified BoNT-A, is free from complexing proteins associated with immunogenicity.

Objective: To analyse INCO pediatric immunogenicity data.

Methods: Pooled antibody data were analysed from four phase 3 studies of children/adolescents (2–17 years): investigating INCO for either limb spasticity associated with cerebral palsy [Treatment with IncobotulinumtoxinA in Movement (TIM), Treatment with IncobotulinumtoxinA in Movement Open-label (TIMO), incobotulinumtoxinA in aRm treatment in cerebral palsy (XARA)] or sialorrhea associated with neurological disorders [Sialorrhea Pediatric Xeomin Investigation (SIPEXI)]. Methodological details have been published. INCO doses, number/frequency of injection cycles, and antibody testing timing were captured. Samples were screened using fluorescence immunoassay (FIA) to detect BoNT antibodies. If positive, neutralizing antibody (NAB) titer testing was performed using the mouse ex vivo hemidiaphragm assay (HDA). Data were pooled across INCO doses. Only patients weighing  $\geq 21$  kg (spasticity)/ $\geq 30$  kg (sialorrhea) were tested.

Results: 520/1159 INCO-treated patients were eligible for antibody testing at screening. 422 (81.2%) test results were available. Screening/last visit results: Using FIA, 60 (11.5%)/ 54 (8.8%) tested positive. Using HDA, 10 (1.9%)/ 10 (1.6%) were NAB positive. In those with known pre-treatment status, no BoNT-naïve patients developed NABs after INCO; all with positive NAB tests had previously received a BoNT other than INCO.

Conclusions: INCO in treatment-naïve children/adolescents lacks an immunologic response and does not induce new NAB formation during extended use.

**PSYCHOMETRIC EVALUATION OF THE COMPUTERIZED BATTERY FOR NEUROPSYCHOLOGICAL EVALUATION OF CHILDREN (BENCI) AMONG SCHOOL AGED CHILDREN IN THE CONTEXT OF HIV IN AN URBAN KENYAN SETTING**

A. Abubakar<sup>2</sup>, J. Hia<sup>1</sup>, M. Perez-Garcia<sup>3</sup>, M. Kumar<sup>2</sup>, J. Wicherts<sup>1</sup>

<sup>1</sup>*Methods and Statistics, Tilburg University, Netherlands*

<sup>2</sup>*Brain and Mind Institute, Aga Khan University, Kenya, Kenya*

<sup>3</sup>*Mind, Brain and Behavior Research Center (Cimcyc), University of Granada, Spain*

Culturally validated neurocognitive measures for children in Low- and Middle Income Countries are important in the timely and correct identification of neurocognitive impairments. Such measures can inform development of interventions for children exposed to additional vulnerabilities like HIV infection. The Battery for Neuropsychological Evaluation of Children (BENCI) is an openly available, computerized neuropsychological battery specifically developed to evaluate neurocognitive impairment. This study adapted the BENCI and evaluated its reliability and validity in Kenya.

The BENCI was adapted using translation and back-translation from Spanish to English language. The psychometric properties were evaluated in a case-control study of 328 children (aged 6 – 14 years) living with HIV and 260 children not living with HIV in Kenya. We assessed reliability, factor structure, and measurement invariance with respect to HIV. Additionally, we examined convergent validity of the BENCI using tests from the Kilifi Toolkit.

Internal consistencies (0.49  $\alpha$  0.97) and test-retest reliabilities (-.34 to .81) were sufficient-to-good for most of the subtests. Convergent validity was supported by significant correlations between the BENCI's Verbal memory and Kilifi's Verbal List Learning ( $r = .41$ ), the BENCI's Visual memory and Kilifi's Verbal List Learning ( $r = .32$ ) and the BENCI's Planning total time test and Kilifi's Tower Test ( $r = -.21$ ) and the BENCI's Abstract Reasoning test and Kilifi's Raven's Progressive Matrix ( $r = .21$ ). The BENCI subtests highlighted meaningful differences between children living with HIV and those not living with HIV. After some minor adaptations, a confirmatory four-factor model consisting of flexibility, fluency, reasoning and working memory fitted well

( $\chi^2 = 135.57$ ,  $DF = 51$ ,  $N = 604$ ,  $p = .001$ ,  $RMSEA = .052$ ,  $CFI = .944$ ,  $TLI = .914$ ) and was partially scalar invariant between HIV positive and negative groups.

The English version of the BENCI formally translated for use in Kenya can be further adapted and integrated in clinical and research settings as a valid and reliable cognitive test battery.

#### **REHABILITATION OF PATIENTS WITH GUNSHOT INJURIES OF THE PERIPHERAL NERVES OF THE LOWER EXTREMITIES**

**Sadagat Huseynova Huseynova<sup>1</sup>**, E. Mustafayeva<sup>2</sup>

<sup>1</sup>*Physiotherapy and Medical Rehabilitation, Azerbaijan Medical University, Azerbaijan*

<sup>2</sup>*Clinical Neurophysiological Laboratory, Research Institute of Medical Rehabilitation, Azerbaijan*

**Purpose of the study:** To study the characteristics of the action of various types of electrical stimulation (ES) and naphthalan therapy (NT) by clinical and neurophysiological studies in the rehabilitation of veterans of the second Karabakh war.

**Materials and methods of research:** The treatment experience of 208 patients with gunshot injuries of the nerves of the lower extremities was summarized. Isolated injury of the nerves of the lower extremities was observed in 135 (64.9%) patients, combined injury - in 73 (35.1%). The symptoms of nerve injury included various types of pain (in 36%), numbness (in 69.7%), motor disorders up to paralysis (85.2%), vegetative and trophic disorders.

Comprehensive rehabilitation treatment included the use of various types of ES at the first stage (bioelectric stimulation - BES, transcutaneous electrical nerve stimulation (TENS), acupuncture electrical stimulation - APES) and at the second stage of NT.

**Results.** After treatment, patients of all groups showed a decrease in pain, regression of motor disorders and an increase in muscle strength. Under the influence of various types of ES, there was an increase in the amplitude of the M-potential, conduction velocity ( $p < 0.001$ ), amplitude of the H-reflex ( $p < 0.001$ ) and the ratio  $H_{max}/M_{max}$ . A positive therapeutic effect was achieved in 72.4% of patients in the first group, in 83.8% in the second group and in 76.1% in the third group.

**Conclusion:** The use of various types of ES in combination with NT is effective in the rehabilitation of patients with gunshot injuries of the nerves of the

lower extremities, in all forms of nerve damage, as well as after reconstructive operations.

#### **A CASE OF ATYPICAL CHRONIC PROGRESSIVE EXTERNAL OPHTHALMOPLEGIA PLUS WITH OPTIC NERVE ATROPHY**

**Sang Jin Kim**

*Department of Neurology, Busan Paik Hospital, Inje University College of Medicine, South Korea*

Chronic progressive extraocular ophthalmoplegia (CPEO) manifests as a progressive, bilateral ophthalmoplegia and ptosis. Cases with the affection of muscles or organs other than the extra-ocular eye muscles are referred to CPEO-plus. Herein, we describe a patient of CPEO-plus with unusual phenotypes such as optic disc and nerve atrophies. A 64-year-old woman presented sensorineural hearing loss, bilateral ptosis and ophthalmoplegia, decreasing of visual acuity, both hands and head tremors, and gait disturbance beginning several years ago. The targeted gene panel test for mitochondrial DNA identified a heteroplasmic m.5703GA mutation in the MT-TN gene in the patient's blood. The m.5703GA mutation has been already reported in a few CPEO patients with late-onset myoclonic epilepsy with ragged red fibers syndrome, or with mitochondrial myopathy. However, optic disc atrophy and neuropathy are unreported phenotypes in patients with the m.5703GA mutation. Therefore, this case showed the broad phenotypic spectrum of CPEO with the m.5703GA mutation.

#### **LATE-ONSET OF BIOTINIDASE DEFICIENCY- A TREATABLE CAUSE OF PERIPHERAL NEUROPATHY**

**Kremena Kancheva**, I. Stefanov

*Neurology, MC "Arthromedica", Bulgaria*

Biotinidase deficiency (BTD) is a rare, inherited, potentially treatable disease. It affects the way the body processes biotin (sometimes called vitamin H). Biotin is an important vitamin that helps the body break down protein, fats and carbohydrates. BTD is characterized by severe neurological manifestations such as hypotonia, lethargy, ataxia, hearing loss, seizures and development retardation in its classical form. In adults biotinidase deficiency presents distinctly from the classical form such as limb weakness and vision

problems. We describe an adult with lower limb neuropathy. He was found to have biotinidase deficiency by identifying homozygous pathogenic variant of the BTD gene, which is associated with autosomal recessive biotinidase deficiency.

**Case report and methods:** The man had progressive peripheral neuropathy with weakness, pain and fatigue, which started at the age of 14. Profound biotinidase deficiency was found after 13 years.

**Results:** The patient's neuropathy did not improve with 12 months of biotin therapy.

**Conclusions:** The long-term symptoms of the patient were irreversible. These cases emphasize the importance of considering biotinidase deficiency in the differential diagnosis of adolescents and adults with peripheral neuropathy before symptoms become irreversible.

**Key words:** biotinidase deficiency in adolescents and adults, biotin therapy

## IS TGA A VASCULAR DISEASE

**P. Kapeller**

*Neurology, LKH Villach, Austria*

Transient global amnesia (TGA) is a temporary disturbance in cognitive processes which results in anterograde and retrograde amnesia and lasts up to 24 hours.

The exact etiology of TGA is widely discussed. Since there is a percentage of patients whose MRIs show a meanwhile TGA-typical hippocampal lesion in the diffusion weighted imaging (DWI), a question of potential vascular etiology rises. If we are to follow some of the latest studies, these lesions can also be seen in the 7 T MRIs, which could potentially be the ultimate confirmation of a vascular damage in regards of modern technology. On the other hand, the same technology could be used as a mean to a final dismiss of vascular etiology of TGA, as it has recently been published that the primarily proven lesions disappear after several months. Furthermore, DWI lesions can also be seen in other neurological conditions, such as encephalitis, multiple sclerosis, cytotoxic edema and epilepsy.

In the light of new evidence in favor and against vascular etiology of TGA, there is a need of further studies in order to gain the right perspective of the existent data.

## UREMIC ENCEPHALOPATHY MIMICKING ACUTE BULBAR STROKE WITH PROGRESSION FROM BRADYKINESIA TO CHOREIC MOVEMENTS IN A DIABETIC PATIENT UNDERGOING HEMODYALYSIS : A CASE REPORT

J. Tana<sup>2</sup>, B. Qazimllari<sup>2</sup>, **A. Kuqo**<sup>1</sup>, A. Rroji<sup>3</sup>, A. Verlaku<sup>2</sup>, A. Rama<sup>2</sup>, J. Kruja<sup>1,2</sup>

<sup>1</sup>*Neurology Service, UHC Mother Teresa, Albania*

<sup>2</sup>*Neurology Service, University of Medicine Tirana, Albania*

<sup>3</sup>*Radiology Department, UHC Mother Teresa, Albania*

UE is an uncommon neurologic complication encountered in patients with acute or chronic renal failure. We report the case of a 42-year-old man of Romany descent, with end stage renal disease (ESRD), who developed symmetrical bilateral basal ganglia syndrome manifesting as acute bulbar stroke. The patient presented with a 4-days history of sudden onset of generalized weakness, dysphagia, dysarthria, right hemiparesis and unsteady gait. He suffered from long-standing uncontrolled diabetes mellitus on insulin therapy, hypertension, tobacco using and ESRD secondary to diabetic nephropathy on regular hemodialysis for the last three years. The patient had no history of recent infection, but reported frequent hypoglycemic episodes. Neurological examination showed hypophonia, dysarthria, hypomimia, bradykinesia and a short-step gait. Laboratory investigations demonstrated increased renal function tests, glycemia 20 mg/dl. Other metabolic and electrolyte tests were normal. The acute clinical presentation in a patient with vascular risk factors made us consider a bulbar stroke. Brain MRI revealed bilateral lentiform fork sign. The patient was diagnosed with "bilateral basal ganglia syndrome" triggered by hypoglycemia. He was discharged without significant changes of neurological status. Three months later, he presented with generalized choreic movements. The involuntary movements were so severe, causing him inability to stay stable during hemodialysis, were associated with episodes of hypoglycemia and improved with relative increased glucose levels. In conclusion, we highlight that it is of paramount importance to avoid glycemic fluctuations in diabetic uremic patients in order to prevent the syndrome of acute basal ganglia lesions and progression of clinical symptomatology.

### TREATMENT, CLINICAL COURSE, AND CARE FOR THE PATIENTS WITH NEUROLOGICAL DISEASES IN KHARKIV REGION DURING UKRAINIAN CRISIS

Yevgeniya Lekomtseva<sup>1</sup>, Liudmila Bilyk<sup>2</sup>, Igor Kutovyi<sup>3</sup>, Anastasiia Sydorenko<sup>4</sup>, Gregers Wegener<sup>4</sup>, Betina Elfving<sup>5</sup>, Cecilia Bay-Richter<sup>5</sup>

<sup>1</sup>Department of Clinical Medicine, Translational Neuropsychiatry Unit, Aarhus Institute of Advanced Studies, Denmark

<sup>2</sup>Outpatient Clinic, State Institute of Neurology, Psychiatry and Narcology of the National Academy of Medical Sciences of Ukraine, Ukraine

<sup>3</sup>Department of Functional Neurosurgery and Paroxysmal States, State Institute of Neurology, Psychiatry and Narcology of the National Academy of Medical Sciences of Ukraine, Ukraine

<sup>4</sup>Translational Neuropsychiatry Unit, Aarhus Institute of Advanced Studies, Denmark

<sup>5</sup>Department of Clinical Medicine, Translational Neuropsychiatry Unit, Aarhus University, Denmark

24.02.2022 terrible war started in Ukraine. The health care medical system has been broken and suffered from the damage of medical supply in Kharkiv region (Ukraine) which lost medical resources completely for some months in the spring. Large deficit of urgently needed drugs had appeared such as anti-epileptic drugs for seizure controlling, methylprednisolone for treatment of multiple sclerosis (MS) relapses, heparin for ischemic strokes, cholinesterase inhibitors for myasthenia and MS patients, as well as drugs for emergency care, such as antibiotics, painkillers. Ukrainian patients and doctors are highly appreciating the international support at this difficult time for Ukraine provided by World Health Organization and volunteer service who helped enormously from the first days and this deficit was covered.

Survey with repeated consultations were conducted over phone (12.03.2022-19.07.2022) among patients with epilepsy (n=29, M=11, F=18), MS patients (n=58, M=9, F=49), dyscirculation-vascular encephalopathy (M=3), neurosis and panic attacks (F=9), hemicrania continua (n=23, M=4, F=19), peripheral radiculopathy (n=18, M=16, F=2), sleep disturbances (n=54, M=8, F=39), trigeminal neuralgia (M=2), Parkinson disease (n=9, M=4, F=5), facial tics (n=4, M=2, F=2). Ukrainian patients with neurological diseases applied for medical help in

Kharkiv (on-line with in person consultations of specialists in Institute of Neurology) and hospitals and outpatient clinics of cities in western Ukraine and Europe. Many patients couldn't receive the necessary treatment during the first months of Ukrainian crisis, also a huge patient migration was observed (total n=191, immigrated n=86; 45.03%), so, it's not easy to assess the medical care provided to Kharkiv region patients. We recognized a significant worsening of all neurological symptoms within this time suggesting the escalation of their diseases.

### BELIEF IN OMENS AND SUPERSTITIONS AMONG PATIENTS WITH CHRONIC NEUROLOGICAL DISORDERS

Ruta Mameniskiėne, Kristijonas Puteikis  
Faculty of Medicine, Vilnius University, Lithuania

Background: Chronic neurological disorders may affect various cognitive processes, including superstitious belief. We tested whether superstitious beliefs are equally prevalent among patients with Parkinson's disease (PD), multiple sclerosis (MS), epilepsy (PWE) and healthy controls (HCs).

Methods: We conducted an anonymous survey among outpatients and HCs by asking them to ascribe meaning or report belief for 27 culturally adapted statements (9 omens and 18 superstitions). The superstition index (SI) was measured as the sum of items respondents believed in. The SI was compared between groups and two-step cluster analysis was performed to discern different subgroups based on answers to the items of the SI.

Results: Among 371 respondents (152 PWE, 47 patients with PD, 71 with MS and 101 HCs), complete SI scores were collected for 312 (84.1%) and they were lower in patients with PD (n=29, Md=1, IQR=0-5) in comparison to those with epilepsy (n=127, Md=7, IQR=1-14), MS (n=58, Md=6.5, IQR=0-12) or HCs (n=98, Md=4.5, IQR=1-10),  $H(3)=14.431$ ,  $p=0.002$ . The negative binomial regression model (n=289,  $\chi^2=26.323$ ,  $p<0.001$ ) was adjusted for sex (OR=1.760, 95%CI=1.304-2.376), income (OR=0.954, 95%CI=0.807-1.128) and education (OR=0.942, 95%CI=0.851-1.043), and PD was the only disease associated with the SI (OR=0.531, 95%CI=0.296-0.953). Two-step cluster analysis classified individuals with PD grouped into "non-believer" and "semi-believer" groups rather

than “non-believer” and “believer” clusters characteristic for PWE, patients with MS and HCs.

**Conclusion:** We suggest that individuals with PD are less prone to have superstitious beliefs than patients with MS, PWE or HCs. This could reflect a unique impact of PD on cognitive processes underpinning superstitious thinking.

#### **ENCOURAGING RESULTS OF FOCUSED ULTRASOUND THALAMOTOMY FOR MULTIPLE SYSTEM ATROPHY**

**Maria Nassar**<sup>1</sup>, Alon Sinai<sup>2</sup>, Lev Shornikov<sup>3</sup>, Marius Constantinescu<sup>2</sup>, Inna Senderova<sup>1</sup>, Menashe Zaaroor<sup>2</sup>, Ilana Schlesinger<sup>1</sup>

<sup>1</sup>Neurology, Rambam Health Care Campus, Israel

<sup>2</sup>Neurosurgery, Rambam Health Care Campus, Israel

<sup>3</sup>Neurology, The Baruch Padeh Medical Center, Israel

**Objective:** To report on the efficacy and safety of MRI-guided focused ultrasound (FUS) VIM-thalamotomy in patients with multiple system atrophy (MSA) Parkinsonian type (MSA-P).

**Background:** FUS has established efficacy in tremor relief but its efficacy and safety in relieving tremor in MSA-P patients has not been established.

**Methods:** Patients were assessed using the Unified MSA rating scale (UMSAR). Tremor was quantified overall and in the treated hemi-body using the Clinical Rating Scale for Tremor (CRST).

**Results:** Five Patients with possible MSA-P with a median age of 69 years (range 67-74), median disease duration of 2 years range (1-7), were treated. FUS treatment resulted in immediate complete cessation of tremor at the end of the procedure in the treated arm in 4 patients and significant improvement in 1 patient. At 1 month 2 patients remained tremor free, 2 patient had significant improvement compared with baseline and in 1 patient tremor returned to baseline. After 6 months, 2 patients remained tremor free, 2 maintained significant improvement and 1 was lost to follow-up. UMSAR decreased from 35 before treatment (n=5) to 26 at 1 week (n=5), 33 at 1 month (n=5), 30 at 6 months (n=4). Adverse events included transient objective and subjective gait ataxia, lip paresthesias and asthenia that resolved within 1-6 months.

**Conclusions:** Our report suggests that FUS VIM-thalamotomy may be effective in tremor relief in patients with MSA-P. Larger double blind studies are needed to verify our observations.

#### **AN ATYPICAL PRESENTATION OF BANNWARTH SYNDROME**

L.M. Selescu<sup>1,2</sup>, **Ioana-Andreea Neagu**<sup>1</sup>, A-M. Vladila<sup>1</sup>

<sup>1</sup>Neurology, Colentina Clinical Hospital, Romania

<sup>2</sup>Research and Development Center, Colentina Clinical Hospital, Romania

**Introduction:** Lyme disease is a tick-borne multisystem illness caused by the spirochete *Borrelia burgdorferi*. Bannwarth syndrome is a neuroinvasive form of Lyme disease occurring in 3% of cases, usually early, but occasionally late in its course. It consists of a painful radiculoneuritis accompanied by motor deficits, CSF pleocytosis and sometimes peripheral facial palsy.

**Case presentation:** A 66-year-old male known with B viral hepatitis, hypertension and diabetes developed pain and a burning sensation in the upper abdomen. One month later he complained of pain in the left shoulder and distal muscle weakness of the left upper limb. Two weeks later he described similar symptoms in the right upper limb and bilateral palmar numbness. Four months after the initial symptom onset, CSF testing revealed normal glucose, increased protein (134 mg/dl), lymphocytic pleocytosis with 166 cells/mm<sup>3</sup>, oligoclonal bands and IgM/IgG antibodies against *Borrelia burgdorferi*. Serum *Borrelia burgdorferi* IgM/IgG antibodies were positive on Western blot and their CSF/serum index was elevated. Electrophysiology studies revealed an axonal length-dependent sensorimotor polyneuropathy. Clinical and laboratory findings were in favor of neuroborreliosis. Antibiotic treatment with ceftriaxone 2 g/day was undertaken for 30 days. The evolution was favorable, with complete remission of the symptoms.

**Conclusion:** This case is noteworthy because the neurological symptoms were the only manifestation of Lyme disease. They could be classified as an atypical form of Bannwarth syndrome, with CSF pleocytosis, without cranial nerve involvement and with a rather late onset, although the moment of the infection is not precisely documented.



### THE UPS AND DOWNS OF A CASE OF SPONTANEOUS INTRACRANIAL HYPOTENSION COMPLICATED WITH CEREBRAL VENOUS THROMBOSIS

Sorina Neculai<sup>1</sup>, D. Tulba<sup>1,2</sup>, N. Dima-Blidaru<sup>1</sup>, M. Avasilichioaei<sup>1</sup>, B.O. Popescu<sup>1,2,3</sup>

<sup>1</sup>Neurology, Colentina Clinical Hospital, Romania

<sup>2</sup>Carol Davila, University of Medicine and Pharmacy, Romania

<sup>3</sup>Laboratory of Cell Biology, Neurosciences and Experimental Myology "Victor Babes" National Institute of Pathology, Romania

Spontaneous intracranial hypotension (SIH) is a rare condition, with cerebral venous sinus thrombosis (CVT) among its potential, albeit uncommon, complications.

Proposed mechanisms for this association include the maintenance of a constant intracranial volume by increasing blood flow in compensation for volume depletion, leading to blood stasis and thrombosis; blood hyperviscosity due to low CSF absorption could be yet another mechanism. The risk of thrombosis increases with additional risk factors such as hereditary hypercoagulable states

A 40-year old man was admitted to our clinic for orthostatic headache and hearing disturbances, binocular horizontal diplopia and dizziness for one week. Neurological examination revealed left infranuclear sixth nerve palsy. We performed contrast brain MRI with angiography sequences that identified pachymeningeal enhancement, right cavernous sinus thrombosis and superior sagittal sinus thrombosis. A lumbar tap with associated manometry revealed low CSF opening pressure.

The workup was positive for inherited thrombophilia (homozygous mutation in PAI 4G/5G and in XIII factor V34L, heterozygous C677T mutation in MTHFR) and negative for neuroinfections and autoimmune disorders. An epidural blood patch was applied after MRI myelography, with complete symptom relief, followed by anticoagulation with LMWH in the therapeutic range.

SIH is an important, underestimated risk factor for cerebral venous thrombosis, especially in association with hypercoagulable disorders. CVT should always be considered in a patient with SIH, given its potentially severe complications.

### POOLED SAFETY ANALYSIS OF INCOBOTULINUMTOXINA IN THE TREATMENT OF NEUROLOGICAL DISORDERS IN ADULTS

Emma Owens<sup>1</sup>, P. Kaňovský<sup>2</sup>, M. Hast<sup>3</sup>, A. Hanschmann<sup>4</sup>, M. Althaus<sup>4</sup>, A. Patel<sup>5</sup>

<sup>1</sup>Neurology, Parkinson-Klinik Ortenau, Germany

<sup>2</sup>Faculty of Medicine and Dentistry and University Hospital, Palacký University Olomouc, Czech Republic

<sup>3</sup>Medical Affairs Scientific Strategy, Merz Pharmaceuticals LLC, USA

<sup>4</sup>Medical and Clinical Development, Merz Therapeutics GmbH, Germany

<sup>5</sup>Physical Medicine and Rehabilitation, Kansas City Bone and Joint Clinic, USA

Background: The safety and efficacy of incobotulinumtoxinA in adults with neurological disorders have been investigated in multiple prospective clinical trials.

Objective: To examine the pooled incidence of treatment-emergent adverse events (TEAEs) and immunogenicity by indication in sponsored incobotulinumtoxinA clinical trials in adults.

Methods: TEAEs were identified in the integrated clinical database of Merz-sponsored placebo-controlled studies in adults with cervical dystonia (CD), blepharospasm, upper limb (UL) and lower limb (LL) spasticity, sialorrhea or essential tremor of the UL. Overall incidences of TEAEs and the categories of serious TEAEs (SAEs), TEAEs leading to discontinuation, fatal TEAEs, TEAEs of special interest (AESIs; indicating possible toxin spread) and treatment-related (TR) events were determined for incobotulinumtoxinA and placebo after a single injection cycle and for incobotulinumtoxinA after multiple cycles. Neutralizing antibody (NAb) testing was performed in most studies.

Results: After a single cycle, incidences of overall TEAEs were similar between incobotulinumtoxinA and placebo in all indications, although between-indication differences were observed. Most TEAEs were mild to moderate; only one subject experienced a TR-SAE. Few TEAEs led to discontinuation of incobotulinumtoxinA; no fatal TEAEs occurred with incobotulinumtoxinA. Repeated cycles generally did not increase the incidence of any TEAE category. The most frequent TEAEs and TR-TEAEs were

indication-dependent. The most common TR-AESIs across all indications were muscular weakness and dry mouth. Few subjects developed NAb and most had been positive at baseline.

Conclusions: This pooled analysis supports and extends the favorable safety/tolerability profile of incobotulinumtoxinA for the treatment of adult neurological disorders established by individual clinical studies.

#### **MILD COGNITIVE IMPAIRMENT IN 35-YEAR-OLD PATIENT AFTER *LISTERIA MONOCYTOGENES* MENINGITIS**

**Tea Plisic**

*School of Medicine, University of Zagreb, Croatia*

Introduction: Mild cognitive impairment (MCI) is a form of early-stage memory loss or other cognitive ability loss specific for individuals who maintain the ability to independently complete most daily activities. It is characterized by problems with memory, judgement, language, and visual perception.

*Listeria monocytogenes* (LM) is one of the most frequent causes of bacterial meningitis in immunocompromised adults, individuals suffering from arterial hypertension and the elderly. Early treatment with ampicillin or penicillin increases the likelihood of survival. Neurologic sequelae of varying degree remain prevalent in the survivors (approximately 60%).

The aim of this case report is to raise awareness of potential development of neurocognitive complications after *Listeria monocytogenes* meningitis.

Case presentation: We herein report a 35-year-old male patient with mixed connective tissue disease (since 2017), and celiac disease and gastritis. He was treated with methotrexate. In July of 2022, the patient was admitted for bacterial meningitis caused by *Listeria monocytogenes*. After discharge from hospital, the patient noticed mild memory loss, lack of vocabulary, inattentiveness vertigo, and impairment of fine motor skills with occasional myoclonic jerks. Neurocognitive testing confirmed mild cognitive impairment (MCI). His MMSE score was 23/30 and MoCA score was 18/30. Brain MRI showed normal brain morphology with decreased cerebral blood flow on ASL sequences in posterior cingular cortex and precuneus.

Conclusion: Treatment with immunosuppressant agents such as methotrexate, may increase risk for bacterial meningitis. Development of mild cognitive impairment after listeria meningitis should be considered as an important neuropsychiatric complication.

#### **A CASE REPORT OF UNILATERAL MOYAMOYA DISEASE IN A 24-YEAR-OLD PATIENT**

**T. Plišić<sup>1</sup>, T. Sučić Radovanović<sup>2</sup>, V. Kalousek<sup>3</sup>, H. Budinčević<sup>4,5</sup>**

*<sup>1</sup>School of Medicine, University of Zagreb, Croatia*

*<sup>2</sup>Department of Radiology, Sveti Duh University Hospital, Croatia*

*<sup>3</sup>Department of Radiology, Clinical Hospital Center 'Sisters of Mercy', Croatia*

*<sup>4</sup>Department of Neurology, Sveti Duh University Hospital, Croatia*

*<sup>5</sup>Department of Neurology and Neurosurgery, J.J. Strossmayer University of Osijek, Croatia*

Introduction: Moyamoya disease is a rare vascular disorder of the brain arteries. It is a chronic and progressive condition, where gradual narrowing of the blood vessels in the brain may lead to ischemic stroke, transient ischemic attack (TIA) or intracranial hemorrhage. The aim of this report to present a case of unilateral Moyamoya syndrome.

Case presentation: We herein report a 24-year-old female patient with a medical history of migraine headaches and recurrent TIA with left sided arm monoparesis, paresthesia's and twitching of the left hand. Patient was admitted to Neurology Day-hospital for evaluation. The Brain MRI was normal, but MR angiography and subsequent testing showed unilateral stenosis of the M1 segment of the right *middle cerebral artery*. The patient was given dual antiplatelet therapy. Oral contraceptives were excluded from therapy due to their procoagulant effect. Digital subtraction angiography and functional neuroradiological examinations were used to determine whether there is need for neurosurgical vascular procedures to ensure appropriate cerebral blood flow. Since there was optimal brain perfusion, the surgery was postponed to a later date, with the patient being instructed to have continuous clinical and imaging check-ups.

Conclusion: This case report displays the rare presentation of unilateral Moyamoya syndrome and ac-

knowledge this condition as a potential differential diagnosis in patients with recurrent headaches. Early diagnosis and long-term neurologic and radiologic follow-ups are crucial in prevention of vascular complications and improving the quality of life. Cerebral extracranial-intracranial bypass surgery is a treatment for patients with cerebral hypoperfusion due to Moyamoya disease.

#### **RELATIONSHIP BETWEEN ANXIETY AND HEART RATE VARIABILITY IN ELDERLY INSOMNIA PATIENTS**

**Jinwon Seo, S. Kim**

*Psychiatry, Samsung Medical Center, South Korea*

**Objective:** This study investigated the association between anxiety symptoms in elderly insomnia patients and heart rate variability (HRV) parameters.

**Methods:** In total, 46 elderly patients ( $67.91 \pm 5.61$  years old, 11 males, 35 females) were enrolled. The Pittsburgh Sleep Quality Index (PSQI), Beck Anxiety Inventory (BAI), Albany panic and phobia questionnaire (APPQ), Penn State Worry Questionnaire (PSWQ) and Liebowitz social anxiety scale (LSAS) were used to measure sleep quality and anxiety. Resting-state HRV was also obtained. The associations between anxiety measures and HRV were analyzed.

**Results:** Female sex was related to higher normalized high-frequency (HF norm) power ( $\beta = 0.32$ ,  $p = 0.04$ ). The APPQ score was negatively correlated with the HF norm ( $\beta = -0.59$ ,  $p = 0.01$ ). Age was negatively correlated with low-frequency power/high-frequency power (LF/HF) ratio ( $\beta = -0.33$ ,  $p = 0.04$ ). Female sex was correlated to lower LF/HF ratio ( $\beta = -0.36$ ,  $p = 0.02$ ). The APPQ score was positively correlated with LF/HF ratio ( $\beta = 0.68$ ,  $p = 0.01$ ).

**Conclusions:** Panic symptoms in elderly insomnia patients were negatively correlated with parasympathetic nervous system activity.

#### **SERONEGATIVE LIMBIC ENCEPHALITIS MISDIAGNOSED WITH WERNICKE ENCEPHALOPATHY**

**G. Pšemeneckienė<sup>1</sup>, E. Šlajūtė<sup>2</sup>**

*<sup>1</sup>Department of Neurology, Hospital of Lithuanian University of Health Sciences Kaunas Clinics, Lithuania*

*<sup>2</sup>Faculty of Medicine, Lithuanian University of Health Sciences, Lithuania*

Autoimmune encephalitis is a group of immune-mediated brain inflammatory syndromes with a difficult diagnosis due to the heterogeneity of the symptoms. We present a case of a patient with atypical limbic encephalitis misdiagnosed with Wernicke encephalopathy.

A 41 yrs woman was hospitalized due to tonic-clonic seizures followed by sudden behavioral changes, hallucinations, and episodic memory impairment. A previous episode of subfebrile temperature was reported. It was also revealed the patient has taken 300 mg of bitters every evening for several years. Routine blood tests and CSF were normal. Chronic infections were ruled out, except for positive anti-CMV IgG. Brain MRI showed bilateral cortico-subcortical T2W hyperintensity without diffusion restriction in the amygdala, hippocampus, and less in the T and F regions. The Autoimmune Encephalitis Panel (serum) was negative and no oncological disease was detected. The history of alcohol abuse led to the diagnosis of Wernicke encephalopathy and thiamin treatment which resulted in a slight improvement. The persisting cognitive deficit after regression of psychiatric symptoms prompted a reassessment of the diagnosis. Subsequent neuropsychological examination and brain imaging demonstrated signs common to limbic encephalitis, but the CSF remained normal including the Autoimmune Panel. The seronegative autoimmune limbic encephalitis was set as the most likely diagnosis and the patient was referred for further follow-up.

Our case highlights the importance of maintaining vigilance in the diagnosis of disorders presenting with behavioral and cognitive symptoms. The negative impact of social status or substance abuse should be assessed with caution in medical decisions.

### EXTENDED LIFE EXPECTANCY IN INFANTILE NEUROAXONAL DYSTROPHY: CASE REPORT OF TWO SIBLINGS

G. Cakciri<sup>2</sup>, A. Rama<sup>1</sup>, N. Mitrollari<sup>1</sup>, J. Kruja<sup>3</sup>

<sup>1</sup>Neurology, Faculty of Medicine, University of Medicine, Albania

<sup>2</sup>Neurology Department, "Mother Teresa" University Hospital Center, Albania

<sup>3</sup>Head of Neurology Department, "Mother Teresa" University Hospital Center, Albania

Infantile neuroaxonal dystrophy (INAD) is a rare neurodegenerative disease which is characterized by infantile onset of rapid motor and cognitive regression and hypotonia evolving into spasticity. It is caused by biallelic pathogenic variants in PLA2G6, which encodes a calcium-independent phospholipase A2.

We present a case of two sisters, 19 and 18 years old, both suffering INAD, with heterozygous mutations of PLA2G6. The onset of the disorder was at four years of age, with hypotonia, static and dynamic ataxia, inability to walk, intentional tremor, involuntary nystagmus and scanned speech. At 6 years of age, generalized tonic-clonic seizures with loss of consciousness were seen. At seven years of age generalized spasticity and stiffness was seen, leading to spastic posture of arms, hands and feet. Due to disease progression, bulbar dysfunction was observed, such as dysphagia and dysarthria. They are currently both presented with spastic tetraplegia, anarthria, severe dysphagia, divergent strabismus, vertical gaze palsy and loss of awareness to the surroundings.

EEG showed bilateral slow spike waves and diffuse polyspikes. Brain MRI for each showed cerebellar cortex atrophy.

INAD is a rare neurodegenerative disorder that presents in early childhood, with a continuous progressive clinical course, usually causing death between the ages 5 to 10 years, however, in extremely rare cases, extended life expectancy is observed.

### INTRATHECAL HYALURONIDASE: RESCUE MEDICATION IN PATIENT OF SECONDARY SYRINX WITH NON-INFECTIVE SPINAL ARACHNOIDITIS

P.N. Renjen, D. Chaudhary, N. Sahu, J. Singh, A. Goswami

Neurology, Indraprastha Apollo Hospitals, India

Introduction- Spinal arachnoiditis can have various etiologies like tuberculosis, trauma, surgery, and intrathecal radiopaque substances. Syringomyelia or syrinx, can be primary, as seen with chiari malformations, or can be secondary, as a complication of arachnoiditis. Management of syringomyelia with spinal arachnoiditis is not guidelineed due to lack of literature, and is hence limited to expert opinion from case reports. Here, we report a case of progressive spastic paraparesis with sensory loss secondary to non-infective spinal arachnoiditis with syrinx, who was treated successfully with intrathecal hyaluronidase.

Case Report: A 43 year old Nigerian Male patient, presented with 7 year history of progressively worsening painful paraesthesia's, starting from mid-abdomen, progressing to distal lower limbs. Gradually, he developed spastic paraplegia with urge incontinence and erectile dysfunction. His MRI Dorsal spine revealed D7-D9 syrinx with mild spinal arachnoiditis without any evidence of tubercular or other infective etiology in CSF analysis. He was managed with IV steroids, followed by weekly 1500 units of intrathecal hyaluronidase for 6 doses. He showed significant improvement in his motor power as well as sensory symptoms. He is currently being followed for radiological improvement and requirement of further doses.

Conclusion: Hyaluronidase has long been a very effective mode of treatment for adhesive exudates as in pleural effusion. Intrathecal hyaluronidase shows its therapeutic efficacy via resolution of adhesions, increased capillary permeability and various other mechanisms. This case illustrates the importance of increasing the scope of hyaluronidase for the management of arachnoiditis with syrinx formation.

**SHOULD SURGICAL TREATMENT BE  
CONSIDERED FOR PROGRESSIVE ULNAR  
NEUROPATHY AT THE ELBOW?**

**Jae Young An**

*Department of Neurology, St. Vincent's Hospital,  
College of Medicine, The Catholic University of  
Korea, South Korea*

Background: Ulnar neuropathy at the elbow (UNE) is the second most common entrapment neuropathy after carpal tunnel syndrome. Treatment for UNE may be conservative or surgical. However, it has been controversial when to treat a person with ulnar neuropathy at the elbow surgically. Some studies reported that young age and mild to moderate pre-surgical status predicted a favorable outcome. Case: We reported a 73-year-old male with reversible ulnar neuropathy at the elbow. After coronary bypass grafting, he experienced paresthesia at the left 4th and 5th finger. The electrophysiological studies, one

month after onset, showed only reduced amplitude of distal sensory nerve action potentials of the left ulnar nerve. Ultrasonography revealed swelling of the ulnar nerve at the medial epicondyle. Clinical symptoms progressed to the weakness of the first dorsal interossei (FDI) and adductor digiti minimi and mild atrophy of FDI over 2 months. Follow-up ultrasonography showed a more enlarged swelling of the ulnar nerve at the elbow, but there was no definite change in the nerve conduction studies. Nine months after avoiding movements or positions provoking, the weakness and paresthesia were improved, with normalization in the electrophysiological studies and ultrasonography. Discussion: In clinically progressive ulnar neuropathy, especially in the acutely developed case, conservative treatment of a long enough period may be needed with close follow-up before deciding on surgical treatment.



## Parkinson's Disease

### **AUTONOMIC DYSFUNCTIONS ARE ASSOCIATED WITH STRIATAL DOPAMINE TRANSPORTER ACTIVITY IN PARKINSON'S DISEASE**

**Sang-Myung Cheon**<sup>1</sup>, Young Jin Jeong<sup>2</sup>,  
Jae Woo Kim<sup>3</sup>

<sup>1</sup>Neurology, Dong-A University School of Medicine, South Korea

<sup>2</sup>Nuclear Medicine, Dong-A University School of Medicine, South Korea

<sup>3</sup>Neurology, Dong-A University Hospital, South Korea

**Background & Objective:** Autonomic symptoms have major impacts on daily life of patients with Parkinson's disease (PD). The aim of this study is to investigate the correlation between autonomic dysfunction and striatal dopamine transporter (DAT) activity in PD.

**Methods:** Autonomic symptoms of patients were assessed by structured questionnaire (AsQ) and non-motor symptom scale (NMSS). All of 122 patients took dopamine transporter (DAT) PET using F-18-FP-CIT, and autonomic function tests using composite autonomic severity score (CASS) and delayed heart-to-mediastinum ratio (HMR) from I-123 MIBG cardiac SPECT.

**Results:** Based on HMR, abnormal HMR group (HMR1.8) showed trend of higher AsQ and significantly increased CASS. According to CASS, normal CASS group was younger and showed milder disease status compared to other groups. Both of normal HMR group and normal CASS group showed significantly increased striatal DAT. Multiple regression analyses using age and disease duration as covariate confirmed association between HMR and sexual subscore of AsQ, and between CASS and AsQ (GI subscore and total score).

**Conclusion:** The results of this study found that objective autonomic measures such as CASS and I-123 MIBG cardiac scan well reflected subjective autonomic symptoms, and suggested association between symptoms and signs of autonomic dysfunction and striatal DAT activity in PD.

### **APATHY AND ITS IMPACT ON QUALITY OF LIFE IN PATIENTS WITH EARLY PARKINSON'S DISEASE**

**Seong-Min Choi**, Man-Seok Park, Byeong C. Kim  
*Department of Neurology, Chonnam National University Hospital and Chonnam National University Medical School, South Korea*

**Background:** Apathy is a common non-motor symptom of Parkinson's disease (PD) that can affect the health-related quality of life (HRQoL) of patients and caregivers. This study aimed to investigate the clinical determinants of apathy and its impact on HRQoL in patients with early PD.

**Methods:** We enrolled 324 patients with early PD with modified Hoehn-Yahr (mHY) stages 1-3 and a disease duration  $\leq 5$  years. Demographic information was obtained, and motor and non-motor symptoms were evaluated with relevant scales.

**Results:** Apathy was present in 110 of 324 (33.9%) patients. Compared with patients with non-apathetic PD, those with apathetic PD had significantly higher mHY stage, Unified Parkinson's Disease Rating Scale-II (UPDRS-II) score, Non-Motor Symptoms Scale (NMSS) total score, Beck Depression Inventory (BDI) score, and Parkinson's Disease Questionnaire-8 (PDQ-8) score. Clinical variables independently associated with the Apathy Evaluation Scale (AES) score were age, mHY stage, NMSS total score, and BDI score. The univariate regression analysis revealed that the PDQ-8 score was significantly associated with age; disease duration; formal education duration; mHY stage; and UPDRS-III, UPDRS-II, NMSS total, Mini-Mental Status Examination, BDI, Beck Anxiety Inventory (BAI), and AES scores. Independent predictors of the PDQ-8 score in the multivariate regression analysis were age and UPDRS-III, UPDRS-II, NMSS total, AES, and BAI scores.

**Conclusion:** In the present study, apathy was an independent predictor of HRQoL in patients with early PD. Therefore, identifying and managing apathy could help improve HRQoL in patients with early PD.

**SYNAPTOGYRIN-3 (SYNGR3) OVEREXPRESSION PROMOTES STRIATAL DOPAMINE UPTAKE IN MUTANT LRRK2-R1441G KNOCKIN MOUSE MODEL OF PARKINSON'S DISEASE**

**Shu-Leong Ho<sup>1</sup>**, Ho Philip Wing-Lok<sup>1</sup>, Li Lingfei<sup>1</sup>, Liu Hui-Fang<sup>1</sup>, Choi Zoe Yuen-Kiu<sup>1</sup>, Chang Eunice Eun Seo<sup>1</sup>, Pang Shirley Yin-Yu<sup>1</sup>, Malki Yasine<sup>1</sup>, Kung Michelle Hiu-Wai<sup>1</sup>, Ramsden David<sup>2</sup>

<sup>1</sup>*Medicine, University of Hong Kong, Hong Kong*

<sup>2</sup>*Institute of Metabolism and Systems Research, University of Birmingham, UK*

LRRK2 mutation is a common genetic risk factor of Parkinson's disease (PD). Synaptic dysfunction is an early pathogenic event associated with dopamine (DA) dysregulation in striatum. DA uptake of dopamine uptake transporter (DAT) affects synaptic plasticity, motor and non-motor behaviour. SYNGR3 is a member of the synaptogyrin family, especially abundant in brain. In vitro studies had shown interaction between SYNGR3 and DAT. Reduced SYNGR3 expression has been observed in human PD brains. Here, we explored whether inducing SYNGR3 expression can affect a) cellular DA uptake using differentiated human SH-SY5Y neuronal cells, b) striatal synaptosomal DA uptake in mutant LRRK2-R1441G knockin mouse model of PD, and c) innate rodent behaviour using the marble burying test. Young LRRK2 mutant mice showed significantly lower striatal SYNGR3 levels compared with age-matched wild-type (WT) controls, similar to aged WT mice. SYNGR3 spatially co-localized with DAT at striatal presynaptic terminals, visualized by immuno-gold transmission electron microscopy (TEM) and immunohistochemistry. Their protein-protein interaction was confirmed by co-immunoprecipitation. Transient overexpression of SYNGR3 in differentiated SH-SY5Y cells increased DA uptake without affecting total DAT levels. Inducing striatal SYNGR3 expression by adenovirus-7 (AAV7) in vivo increased synaptosomal DA uptake in mutant LRRK2 mice and improved their innate marble burying behaviour. These findings show the influence of SYNGR3 on striatal synaptic DA uptake and potential effects on behaviour in a genetic mouse model of PD.

**PROTECTIVE ROLE OF SELENIUM AGAINST FERROPTOSIS-MEDIATED DOPAMINERGIC CELL DEATH: IMPLICATION FOR PARKINSON'S DISEASE**

**Yu Jin Jung<sup>1</sup>**, Hyunsu Choi<sup>2</sup>, Eungseok Oh<sup>3</sup>

<sup>1</sup>*Neurology, Daejeon St. Mary's Hospital, College of Medicine, The Catholic University of Korea, South Korea*

<sup>2</sup>*Chemistry, Clinical Research Institute, Daejeon St. Mary's Hospital, South Korea*

<sup>3</sup>*Neurology, Chungnam National University Hospital, College of Medicine, Chungnam National University, South Korea*

Ferroptosis is non-apoptotic cell death, characterized by lipid peroxidation and iron overload. GPX4, a key regulatory factor in ferroptosis, containing selenium can protect interneurons from ferroptosis. We tried to investigate the protective properties of selenium in an in vitro Parkinson's disease (PD) model, focusing on its underlying mechanism through ferroptosis inhibition. MPP<sup>+</sup>-induced neurotoxicity model was established with SH-SY5Y cells. Western blotting was performed to determine the levels of ferroptosis markers and  $\alpha$ -synuclein. Lipid peroxidation, intracellular ROS, and iron levels were measured using Liperfluo, DCFH-DA, and FerroOrange. The protective effect of selenium was tested with GPX4 silencing. SH-SY5Y cells exposed to selenium with MPP<sup>+</sup> exhibited decreased expression of  $\alpha$ -synuclein and SLC7A11 and increased expression of GPX4 with those exposed to MPP<sup>+</sup> alone. Selenium decreased lipid peroxidation, intracellular ROS, and iron levels. However, siRNA-mediated downregulation of GPX4 attenuated the protective effects of selenium. Ferroptosis inhibition associated with the increase of GPX4 might be an important mechanism underlying the neuroprotective function of selenium in the MPP<sup>+</sup>-induced PD model.

**ALTERATION OF IMMUNOPROTEASOME MRNA IN THE PERIPHERAL BLOOD MONONUCLEAR CELLS OF PATIENTS WITH PARKINSON'S DISEASE**

Hyeo-il Ma<sup>1</sup>, H Nguyen<sup>1</sup>, **J Kang<sup>2</sup>**, Y Kim<sup>1</sup>

<sup>1</sup>*Neurology, Hallym University Sacred Heart Hospital, South Korea*

<sup>2</sup>*Neurology, Jeju National University Hospital, South Korea*



**Background:** Immunoproteasome, a part of ubiquitin proteasome system, is involved in protein degradation and immune response. However, the relationship between immunoproteasome and Parkinson's disease was not evaluated clearly. We hypothesized that the shift of immunoproteasome attributes to PD due to its role in immune system and protein homeostasis.

**Objective:** To determine whether immunoproteasome mRNA in peripheral blood mononuclear cells is expressed differently between patients with PD and healthy controls and to test its value as a biomarker of PD

**Methods:** Blood samples were collected from 19 healthy controls and 40 patients with PD of comparable ages. Peripheral blood mononuclear cells were isolated and used to measure by RT-qPCR the mRNA levels of three catalytic subunits of immunoproteasome, namely, PSMB8, PSMB9, and PSMB10.

**Results:** The levels PSMB9 and PSMB10 mRNA were not different between the PD group and healthy control group, whereas the PSMB8 mRNA in PD group significantly increased. The ratio of PSMB10 and PSMB8 (PSMB10/8) best reflected significant difference between the PD group and healthy control group ( $p = 0.002$ ). This ratio can discriminate all PD, mild PD (Hoehn and Yahr  $\leq 2.5$ ), and drug-naive PD from healthy controls. We found correlation between the PSMB10/8 ratio with the UPDRS total and Part III score in the mild PD subgroup and drug-naive PD subgroups

**Conclusion:** The expression of PSMB8 mRNA increased in PD, and the PSMB10/8 ratio can differentiate Parkinson's disease from healthy controls.

#### **THE EFFECTS OF TRANSCRANIAL DIRECT CURRENT STIMULATION IN PARKINSON PATIENTS IN TERMS OF AMOUNT OF DAILY ACTIVITY AND SLEEP STATUS**

**Jihoon Kang**<sup>1</sup>, D Kwon<sup>3</sup>, H Ma<sup>2</sup>

<sup>1</sup>Neurology, Jeju National University Hospital, South Korea

<sup>2</sup>Neurology, Hallym University Sacred Heart Hospital, South Korea

<sup>3</sup>Neurology, Korea University Ansan Hospital, South Korea

Anodal transcranial direct current stimulation (tDCS) is a noninvasive brain stimulation technique. The aim of this study was to investigate the effects of anodal tDCS on the actual activity of daily living and sleep status in Parkinson's disease (PD) patients with depressive mood measured with individual smart band recordings.

**Method:** Twenty PD patients were evaluated. Total 10 times of anodal tDCS was applied for 20 minutes, 3 times per week, with 2mA current over left dorso-lateral prefrontal cortex. The primary outcome was assessed by average number of total daily steps and the amount of sleep time on the smart-band recording checked for 7days before and after tDCS intervention each. UPDRS part III score, the change of depression rating score and patient global impression scale were analyzed as secondary outcomes.

**Result:** We found that the total step counts were significantly increased after completion of stimuli ( $p=0.012$ ) recorded by smart band. The total activity time, sleep time, deep sleep time were improved without statistical significance. UPDRS part III score and patient global impression score were significantly improved ( $p0.01$ ). Clinical improvement lasted for at least one month after intervention completed.

**Conclusion:** Short-term active anodal tDCS on left DLPFC was well-tolerated and resulted in improvements in total amount of daily activity, motor rating scale, sleep condition and satisfaction of the subjects, indicating a possible adjunctive therapeutic option for the motor, non-motor symptoms and improve the activity of daily living function in real world situations.

#### **DISCREPANCY BETWEEN SELF-AWARENESS AND OBJECTIVE MEASUREMENTS OF OLFACTORY FUNCTION IN PATIENTS WITH PARKINSON'S DISEASE**

**Do-Young Kwon**<sup>1</sup>, Yong-Gi Jung<sup>3</sup>, Minyoung Seo<sup>2</sup>  
<sup>1</sup>Neurology, Korea University Ansan Hospital, South Korea

<sup>2</sup>Otolaryngology, Korea University, Ansan Hospital, South Korea

<sup>3</sup>Otolaryngology, Sungkyunkwan University School of Medicine, Samsung Hospital, South Korea

**Objective:** Parkinson's disease (PD) is the second most common neurodegenerative disorders mainly affecting motor system. Importance of non-motor symptoms of PD such as REM sleep behavior disorder, constipation, affective disorders and hypo/anosmia is getting emphasized as those are known prodromal biomarkers of PD. olfaction is sensitive biomarker reflecting underlying neurodegeneration but there are lots of discrepancy of self-reporting olfactory function scale and the laboratory data in clinical practice. This study is performed to elucidate the correlations between self-awareness of olfactory function and results of objective olfactory test and investigate the factors influencing the differences in PD patients.

**Methods:** Cross-sectional clinical study was performed with 164 newly diagnosed non-demented drug-naive PD. Basic epidemiological and clinical data were collected. Self-rating olfaction scale by visual assessment of rating) and Korean version Sniffin' stick test II (KVSS II) results were compared. Above 80% of self-rating score was considered as normal by self-rating and The KVSS-II TDI score ranged from 1 to 20 for anosmia, 20.25–27 for hyposmia, and  $\geq 27.25$  for normosmia

**Results:** 47 (28%) of the subjects had normosmia on KVSS II. Among 117 (72%) subjects had hypo/anosmia on KVSS II, 69 (59%) patients reported having normal olfaction by self-rating (VAS 8). Subjective self-rating olfactory function of PD patients showed correlation with TDI total score ( $p=0.021$ ) and threshold ( $p0.001$ ), but not with discrimination ( $p=0.362$ ) and identification ( $p=0.547$ ) score on KVSS II.

**Conclusion:** Odor identification and discrimination requires complicated process within central nervous system that is not just simple sensory perception. Odor identification might be attributable to cognitive function and is representatively affected in various neurodegenerative disorders. Self-awareness of olfactory function is largely determined by perception of the smell, while more complicated odor process was not perceived by the subjects in this study. Self-rating scale to check olfactory function is not suitable to detect prodromal non-motor symptoms in elderly PD patients.

## COMBINED APPROACH IN THE DIAGNOSTIC OF PARKINSON'S DISEASE

V Abramov<sup>2</sup>, T Subbotina<sup>1,3</sup>, M Sadovsky<sup>1</sup>,  
**D V Pokhabov<sup>1,2</sup>**

<sup>1</sup>*Neurological Diseases, Krasnoyarsk State Medical University, Russia*

<sup>2</sup>*Neurological Research, Federal Siberian Research Clinical Centre FMBA, Russia*

<sup>3</sup>*Genetic Research, Siberian Federal University, Russia*

Millions of people suffer from neurodegenerative disorders worldwide. Parkinson's disease(PD) is among the leading disease. Our aim was to develop and scientifically substantiate set of criteria for early diagnosis of neurodegenerative disorders, including molecular genetic analysis, positron emission tomography(PET) and olfactory dysfunction diagnostic.

For molecular genetic analysis we included 60 patients with sporadic and genetic PD forms. To identify genes(PARK2 and 7, LRRK2 and etc.) we used the MLPA technique. Analysis of the GBA gene was carried out by direct sequencing according to Sanger. For PET with 18F-FDG we had 10 patients with PD and 10 healthy people for determination of diagnostic norm. To do it, we used graphs of the distribution density of the activity of the RFP using the Parsen-Rosenblatt method. To test the olfactory function, we chose the Sniffin' sticks test.

When conducting MLPA analysis, none of the 60 patients revealed any mutations, which is apparently due to the low incidence of this mutations among patients of our region with diagnosis of PD. But analysis of the GBA gene revealed 6 different variants in 9 out of 60 examined patients.

Using PET, the standard indicators have been established that allow to confidently diagnose PD on the basis of PET examination(and to differentiate with healthy people).

Analysis in the GBA gene showed a similar frequency of occurrence in a sample of patients from our region as in European populations. Determination of a decrease in the uptake of 18F-fludopa during PET allows to confirm the disease, regardless of the presence or absence of motor manifestations.

**EFFICACY OF CONVENTIONAL REHABILITATION ON PAIN AND FATIGUE IN PATIENTS WITH ADVANCED PARKINSON'S DISEASE ON LEVODOPA/CARBIDOPA INTESTINAL GEL. A CASE CONTROL STUDY**

**Ioana Stanescu<sup>1</sup>**, Alexandra I Bulboaca<sup>1</sup>, AE. Bulboaca<sup>2</sup>

<sup>1</sup>*Department of Neurosciences, University of Medicine and Pharmacy "Iuliu Hatieganu", Romania*

<sup>2</sup>*Department of Functional Biosciences, University of Medicine and Pharmacy "Iuliu Hatieganu", Romania*

**Background:** Patients with Parkinson's disease (PD) have severe functional impairments despite optimal management of symptoms with advanced therapies. Rehabilitation is effective and should be incorporated into multidisciplinary PD treatment. In advanced PD patients on Levodopa-Carbidopa Intestinal Gel (LCIG), we aimed to investigate the effect of conventional rehabilitation therapy on fatigue and pain, non-motor symptoms with high prevalence.

**Method:** We identified 39 patients with advanced PD (H&Y stage 4) without severe cognitive impairment, on LCIG treatment with stable doses for at least 6 weeks. Nineteen patients included in the study group received in-hospital conventional rehabilitation treatment (10 sessions, 1.5 h/day of physical therapy, occupational therapy, and virtual therapy) and were compared to a group of 15 control outpatients without rehabilitation treatment. The primary outcomes were pain severity (King's PD Pain Scale, Visual Analog Scale), and fatigue (the Parkinson Fatigue Scale). The secondary outcome was the motor function (UPDRS part III). Assessments were done at baseline, at 2 weeks and 2 months.

**Results:** In the study group, pain perception and intensity were significantly decreased at 2 weeks, without significant effect at follow-up. Fatigue was reported less frequently and with significantly lower intensity in the rehabilitation group, and improvements persisted at follow-up. Short-term benefits on motor function were noticed after 2 weeks, but not after 2 months.

**Conclusion:** PD patients on LCIG have short-term benefits on pain and fatigue after conventional rehabilitation programs. Study limitations are the short

duration of intervention and the limited number of patients


**ALTERED PERIPHERAL CLOCK GENES ASSOCIATED WITH SLEEP AND WAKEFULNESS DISTURBANCES IN PARKINSON'S DISEASE**

**Weidong Le, Hang Yu**

*Institute of Neurology, Sichuan Academy of Medical Science-Sichuan Provincial People's Hospital, Medical School of University of Electronic Science and Technology of China, Chengdu, China*

Disturbance of sleep and wakefulness as a sign of circadian rhythm abnormalities is one of the most common non-motor symptoms of Parkinson's disease (PD). A growing number of studies reveals a link between PD and circadian rhythm alteration. However, little is known whether altered expression of clock genes is involved in the development of sleep-wake disturbances in PD. To evaluate the altered expression of peripheral clock genes and their correlations with sleep-wake phenotypes including probable rapid eye movement sleep behavior disorder (pRBD) symptoms in a relatively large sample of PD patients, we determined the expression profiles of five principal clock genes, BMAL1, CLOCK, CRY1, PER1, and PER2, in the peripheral blood mononuclear cells (PBMCs) of PD patients (n=326), and healthy controls (HC, n=314) using quantitative real-time PCR. Then we performed comprehensive association analyses on the PBMCs clock gene expression and sleep characteristics. Our data showed that the expression levels of BMAL1, CLOCK, CRY1, PER1, and PER2 were significantly decreased in the PBMCs of PD compared to that of HC (P 0.05). pRBD is associated with the expression levels of all five clock genes ( $r = -0.344 \sim -0.789$ , P 0.01). Statistical analyses also revealed that a combination of five clock genes could reach a high diagnostic performance (areas under the curves, 97%) for PD comorbid pRBD.

This case-control study demonstrates that peripheral BMAL1, CLOCK, CRY1, PER1, and PER2 levels are altered in PD patients and may serve as endogenous markers for sleep and wakefulness disturbances of PD.



## Stroke

### EFFECTS OF FUNCTIONAL EXERCISE ON GAIT SYMMETRY IN CHRONIC STROKE SURVIVORS

Styliani Fotiadou<sup>1</sup>, Erasmia Giannakou<sup>1</sup>, Pinelopi Vlotinou<sup>2</sup>, Evageli Karabina<sup>1</sup>, Konstantinos Vadikolias<sup>2</sup>, Nikolaos Aggelousis<sup>1</sup>

<sup>1</sup>Department of Physical Education & Sport Science, Democritus University of Thrace, Greece

<sup>2</sup>Department of Neurology, School of Medicine, Democritus University of Thrace, Greece

Stroke gait patterns are characterized by large differences in spatiotemporal and kinematic parameters between the paretic and non-paretic limb that cause balance disturbances and decrease gait speed. The purpose of this research was to study the effects of functional exercise on the symmetry of gait patterns between the paretic and non-paretic limb in chronic stroke survivors.

Twelve stroke survivors were randomly divided into an exercise group (EG) and a control group (CG). EG followed a number of hourly sessions, 3 times/week for 8 weeks, while CG carried out their normal daily activities. The workouts were based on the respective AHA/ASA recommendations for improving muscle strength/endurance, flexibility, and neuromuscular function, using multi-joint exercises throughout the body. A standard 3D gait analysis protocol using a motion analysis system (Vicon, Oxford Metrics, Oxford, UK) was applied to assess gait at baseline and after treatment. Symmetry ratio (SR) was calculated for selected spatiotemporal and kinematic gait parameters, as the ratio of parameter values between paretic and non-paretic limb.

The results showed a non-significant improvement in SR of spatiotemporal and kinematic parameters in EG only. However, hip, knee, and ankle joint range of motion in the sagittal plane, as well as hip abduction/adduction range of motion improved significantly after treatment in the EG, while remaining practically unchanged in the CG. This may be an indication of the reduced contribution of gait symmetry to gait improvement in stroke survivors, possibly due to the different mechanical work generated by the paretic and non-paretic leg.

### LEFLUNOMIDE-INDUCED HYPEREOSINOPHILIA PRESENTING AS STROKE

D. Tulba<sup>1,2</sup>, N. Bidaru<sup>1</sup>, V. Pompilian<sup>3</sup>, B.O. Popescu<sup>1,2,4</sup>

<sup>1</sup>Department of Neurology, Colentina Clinical Hospital, Romania

<sup>2</sup>Faculty of Medicine, "Carol Davila" University of Medicine and Pharmacy, Romania

<sup>3</sup>Department of Internal Medicine, Colentina Clinical Hospital, Romania

<sup>4</sup>Laboratory of Molecular Medicine, "Victor Babes" National Institute of Pathology, Romania

Hypereosinophilia has previously been linked to the occurrence of multiple watershed cerebral infarctions. Posited mechanisms include either emboli from mural thrombi that lodge in the heart as part of Loeffler endocarditis or local endothelial damage by eosinophils that interfere with the coagulation cascade. An intricate mechanism has also been suggested, whereby local emboli are difficult to wash out from the already underperfused distal arterial territories.

We report the case of a 41-year-old woman diagnosed with rheumatoid arthritis in 2016, with leflunomide added to her treatment regimen about six months prior to presentation. Three months into treatment, she developed a pruritic rash, followed by sudden headache, balance impairment and paresthesia in the left leg. The neurological examination revealed lateral deviations while walking and standing, brisk deep tendon reflexes in the left arm and sensory limb ataxia. Brain MRI identified multiple areas of restricted diffusion suggestive of recent cortical watershed strokes. Blood tests were normal except for hypereosinophilia ( $4.2 \times 1000 \mu\text{L}$ ). A comprehensive imaging work-up, including transesophageal echocardiography and CT angiography of the cerebral arteries was performed, with normal results. A diagnosis of watershed strokes secondary to leflunomide-induced hypereosinophilia was established. Leflunomide was discontinued and the patient received corticosteroids and antiplatelets, with remission of both hypereosinophilia and neurological symptoms.

While post-marketing studies indicate that leflunomide can induce hypereosinophilia and hypereosinophilia has been reported in association with stroke, to our knowledge this is the first case of leflunomide-induced hypereosinophilia presenting as stroke.

## ANTICOAGULANT THERAPY IN HEMORRHAGIC STROKE

Živadinovic Biljana<sup>1</sup>, B Živadinović<sup>1</sup>,  
J Živadinović<sup>2</sup>

<sup>1</sup>*Department of Cerebro Vascular Diseases,  
University Clinical Center Niš,  
Clinic of Neurology, Serbia*

<sup>2</sup>*Clinic for Anesthesia, University Clinical Center  
Niš, Serbia*

Case report: The use of oral anticoagulant therapy (OAT) in patients with ischemic stroke (IS) carries numerous risks and must be tightly controlled. The existence of diseases that require use of OAT in patients with hemorrhagic stroke raises the problem to a higher level and presents the clinician with a major problem of administration and dosing of OAT.

Our case describes patient 67 years old man who has been suffering from hypertension and diabetes for many years.

The first hospitalization due to left-sided weakness, headache, confusion, vomiting, slight right-sided weakness, visual disturbances. CT scan shows IS in the left temporooccipital region.

Due to the occurrence of paroxysms atrial fibrillation, OAT is switched on. After a short hospitalization with a good recovery), the patient is discharged home.

About ten days, a more intense headache occurs. Control MSCT shows the presence of hemorrhage at the site of the previous IS.

After a few days of therapy, the complaints are reduced and the patient is discharged.

All the time, the neurological findings are residual (slight right-sided weakness, right-sided homonymous hemianopsia). Advised continuation of OAT with other regular therapy. Shortly after the second discharge, a stronger headache occurs, visual disturbances increase, changes in behavior, the patient is confused and disoriented. This is followed by the third hospitalization. After improvement, he is discharged home with the recommendation of a lower dose of OAT.

At the follow-up examination after several months, the patient is fine with a minor neurological deficit

## A CASE SERIES OF COVID ASSOCIATED FREE-FLOATING THROMBUS PRESENTING WITH ACUTE STROKE

**Dinesh Mohan Chaudhari**, Anjali Mishra, Kamal Ahmad, Neelam Sahu, Jyoti Singh  
*Neurosciences, Indraprastha Apollo Hospital New Delhi, India*

Background and Aims: Multiple studies in the literature highlight the association between COVID-19 and stroke. We report a case series of acute ischemic stroke in a COVID-19 patient without displaying symptoms of active COVID-19 infection or risk factors for stroke with further review of the literature.

Methods: Case-1: A 51-year-old gentleman with no past medical illness developed sudden onset of right hemiparesis with slurring of speech two hours back. The Patient was found to have a positive COVID 19 RTPCR with no respiratory symptoms.

Case-2: A 57 years old diabetic patient with a recent history of COVID 19 illness one week back, presented with sudden onset painless loss of bilateral vision with unsteadiness of gait and drowsiness for the last six hours.

Results: In both cases, an urgent MRI brain with MRA was done. Case 1 patient had acute left frontoparietal infarct with a carotid free-floating thrombus (FFT) in the left ICA. FFT is a thrombus attached to the arterial wall, without complete intraluminal occlusion, particularly observed in COVID related hypercoagulable phenomena. Case 2 patient had acute infarcts in the right basal ganglia, right cerebellum and left occipital lobe, secondary to an FFT thrombus in the left vertebral artery. Both patients were thrombolysed with IVtPA, which lead to the complete dissolution of the FFTs.

Conclusions: A free-floating thrombus, in the setting of a recent COVID-19 infection, and with the aetiology of both events can be attributed to a COVID-19 hypercoagulable state. Arterial FFT leading to stroke is an uncommon entity with potentially devastating effects, must be diagnosed and treated at the earliest.

### LESION PATTERN OF TRANSIENT ISCHEMIC ATTACK WITH SUBCORTICAL INFARCTION IS DISTINCT FROM LACUNAR STROKE

Pil-Wook Chung<sup>1</sup>, Y. Kim<sup>1</sup>, Y. Song<sup>2</sup>

<sup>1</sup>Department of Neurology, Kangbuk Samsung Hospital, Sungkyunkwan University School of Medicine, South Korea

<sup>2</sup>Department of Neurology, Dankook University Hospital, Dankook University College of Medicine, South Korea

**Background:** In patients with transient ischemic attack (TIA) lasting less than 24 hours, acute infarction was often found on diffusion-weighted MRI (DWI). Infarcts associated with TIA typically have small lesion size, but it is unclear whether the lesion characteristics of TIA-related infarcts can be distinguished from those of lacunar stroke (neurologic deficits more than 24 hours).

**Methods:** Twenty-three patients with TIA with subcortical infarction (TSI) and 47 patients with lacunar stroke with subcortical infarction (LS) were analyzed. The size and relative location of infarcts in the corona radiata (CR) were compared between the two groups on DWI.

**Results:** The location of LS was limited to the posterior portion (3/5) of the CR, whereas the location of TSI was distributed over the whole portion of the CR. While the lesion size of TSI located in the anterior half of the CR was similar to that of LS ( $63.5 \pm 16.3 \text{ mm}^2$  vs.  $63.9 \pm 33.1 \text{ mm}^2$ ;  $p = 0.96$ ), the lesion size of TSI in the posterior half of the CR was smaller than that of LS ( $17.4 \pm 5.8 \text{ mm}^2$  vs.  $63.9 \pm 33.1 \text{ mm}^2$ ;  $p = 0.01$ ).

**Conclusion:** The results suggest that the lesion characteristics of TSI include noneloquent location in the anterior CR or very small (smaller than lacunar stroke) lesion size in the eloquent location of the posterior CR. TIA with subcortical infarction may be a distinct syndrome in clinical manifestations as well as in lesion characteristics distinguished from lacunar stroke.

### RIGHT SIDE PROPENSITY OF CARDIOGENIC EMBOLI IN ACUTE ISCHEMIC STROKE WITH ATRIAL FIBRILLATION

P. W. Chung<sup>1</sup>, K. Y. Park<sup>2</sup>

<sup>1</sup>Neurology, Kangbuk Samsung Hospital, Sungkyunkwan University School of Medicine, South Korea

<sup>2</sup>Neurology, Chung-Ang University Hospital, Chung-Ang University School of Medicine, South Korea

**Background:** Anatomical aspect of the aortic arch might influence the direction of cardiac emboli. We attempted to test the right side propensity of cardiogenic emboli associated with atrial fibrillation (AF) by comparing the detection sides of microembolic signals (MES) on transcranial Doppler (TCD) monitoring and the infarct location on MRI. **Methods and Results:** Patients with paroxysmal or persistent AF on Holter monitoring and MES on TCD monitoring were selected from acute ischemic stroke (AIS) registry. Patients with prosthetic valve or cerebral or carotid artery stenosis were excluded. From TCD monitoring of 30 patients, 78 MES were detected; 47 on right and 31 on left side (60.3% vs. 39.7%,  $p = 0.05$ , chi-square). Among 21 patients who had middle cerebral and/or anterior cerebral artery (MCA/ACA) territory infarct, 16 had right side dominant infarct and 5 patients had left side dominant infarct (76.2% vs. 23.8%,  $p = 0.05$ , chi-square). The mean infarct volume on right side was  $30.1 \pm 43.9 \text{ ml}$  while that of left was  $3.1 \pm 10.3 \text{ ml}$  ( $p = 0.01$ , independent t-test). **Conclusion:** This study demonstrated the right side propensity of cardiogenic emboli and the larger infarct volume of right side MCA/ACA stroke in patients with AF. These results can be attributed to the anatomical difference between innominate artery and left common carotid artery.

### CHASING THE MOYAMOYA: MOYAMOYA DISEASE PRESENTING AS RECURRENT WATERSHED STROKES

Ana Constantinescu<sup>1</sup>, Delia Tulba<sup>1,4</sup>, Radu Mihailescu<sup>1</sup>, Mioara Avasilichioaei<sup>1</sup>, Natalia Blidaru<sup>1</sup>, Mihai Ionescu<sup>2,3</sup>, Florina Antochi<sup>2</sup>, Bogdan Dorobat<sup>3</sup>

<sup>1</sup>Neurology, Colentina Clinical Hospital, Romania

<sup>2</sup>Neurology, The University Emergency Hospital of Bucharest, Romania

<sup>3</sup>Radiology, The University Emergency Hospital of Bucharest, Romania

<sup>4</sup>Faculty of Medicine, "Carol Davila" University of Medicine and Pharmacy, Romania

**Introduction:** Moyamoya is a progressive intracranial vasculopathy responsible for strokes in young adults, especially in Asian population. The currently accepted nomenclature distinguishes moyamoya disease from moyamoya syndrome. The latter comprises various conditions that cause moyamoya-like pattern of vessel blockage and compensatory new vessel growth.

**Methods:** A 32-year-old woman with unremarkable family history was admitted for persistent paresthesia in the left hemiface with sudden onset two days before. Five years prior, she had a stroke presenting as right hemiparesis; the MRI lesion located in the paramedian white matter was consistent with a cortical border zone infarct (between the left anterior and middle cerebral artery). At current admission, the neurological examination was normal except for the positive sensory phenomena. Brain CT revealed an acute hypodense lesion located in the right frontal cortex, suggestive of watershed cerebral infarction. She received antiplatelet monotherapy and was referred for surgical revascularization.

**Results:** An extensive work-up (including blood and CSF samples) for infections (including HIV, syphilis, Lyme disease), hematologic conditions (including thrombophilia), systemic autoimmune diseases and vasculitides was carried out, with values within the reference range. The MRA revealed bilateral stenosis in the distal internal carotid arteries and proximal middle cerebral arteries. Subsequently, the DSA confirmed the bilateral large-vessel stenosis and revealed abnormal vascular networks in the basal ganglia.

**Conclusion:** Moyamoya disease should be considered in young adults presenting with stroke of undetermined cause. Considering its progressive course with potential disabling additive manifestations and high mortality, it is of utmost importance to promptly diagnose and treat the patient.

### OUTCOME MEASUREMENT AND GOAL-SETTING RECOMMENDATIONS IN THE MULTIPATTERN TREATMENT OF SHOULDER SPASTICITY WITH BOTULINUM NEUROTOXIN

J. Jacinto<sup>1</sup>, A. Camões Barbosa<sup>2</sup>, S. Carda<sup>3</sup>, D. Hoad<sup>4</sup>, J. Wissel<sup>5</sup>

<sup>1</sup>Serviço de Reabilitação de Adultos 3, Centro de Medicina de Reabilitação de Alcoitão, Portugal

<sup>2</sup>Medicina Física e Reabilitação, Centro Hospitalar Universitário de Lisboa Central, Portugal

<sup>3</sup>Neuropsychology & Neurorehabilitation, CHUV, Switzerland

<sup>4</sup>Warwick Medical School, University of Warwick, UK

<sup>5</sup>Department of Neurorehabilitation and Physical Therapy, Vivantes Hospital Spandau, Germany

**Background:** Botulinum neurotoxin (BoNT) is a first-line treatment for post-stroke spasticity, helping reduce pain and involuntary movements and restore function. Clinical trials have reported improvements in pain and function after shoulder-muscle BoNT injections.

**Objective:** To present expert consensus on choice of outcome measurement scales and goal-setting recommendations for BoNT in the treatment of shoulder spasticity.

**Methods:** Following a pre-meeting survey, a two-part meeting was held online in late 2021. Five European experts with ~100 years' cumulative experience in post-stroke spasticity gave presentations on shoulder spasticity and treatment with BoNT injections, followed by discussion.

**Results:** Although velocity-dependent increase in muscle tone is often a focus of patient assessment, it is only one component of spasticity and a wider range of measurements is required. For outcome measurement following BoNT shoulder muscle injection, shoulder-specific scales are recommended: AS-SSS, SAAPS and shoulder-relevant items of the ArmA measure, plus standard measurements.



Goal-setting is an essential part of the multiprofessional management of spasticity; goals should be patient-centric, realistic and achievable; functional-focused goal statements and a mix of short (3–6 month) and long-term (9–18 month) goals are recommended. Goals can be grouped into symptomatic, passive function, active function, personal factors and global mobility, measured with the Goal Attainment Scale.

Conclusions: Clinical evaluation tools, goal-setting and outcome expectations for multi-pattern BoNT shoulder-spasticity treatment should be defined by the entire team, ensuring patient and caregiver involvement. These recommendations will benefit clinicians who may not be familiar with injecting shoulder muscles and assessing treatment outcomes.

#### **TROUSSEAU SYNDROME: ACUTE ISCHEMIC STROKE AS AN INITIAL MANIFESTATION OF OCCULT PANCREATIC CANCER**

**Hyeseon Jeong<sup>1</sup>**, Jong Wook Shin<sup>2</sup>, Dae-Hyun Kim<sup>3</sup>

<sup>1</sup>*Department of Neurology, Chungnam National University hospital, Daejeon, South Korea, South Korea*

<sup>2</sup>*Department of Neurology, Chungnam National University Sejong Hospital, South Korea*

<sup>3</sup>*Department of Neurology, Dong-A University Hospital, South Korea*

Introduction: Trousseau syndrome (TS) is roughly defined as an acquired coagulopathy causing thrombotic event in association with an occult malignancy. Stroke often accompanied in patients with advanced malignancy, or it can be an initial manifestation of a hidden malignancy. Herein, we report cases of ischemic stroke and advanced pancreatic cancer.

Case report: The first case (63/M) presented hospital with dysarthria. Brain diffusion weighted image (DWI) revealed multiple cerebral infarction (CI). The plasma level of D-dimer was high (3200ng/mL). Abdominal CT showed pancreatic cancer with liver metastasis. Oral anticoagulant has been prescribed, and any further ischemic event has not been occurred for a year. Another case (83/M) visited hospital with severe dysarthria and dysphagia. He also diagnosed as multiple CI with elevated level of D-dimer (1056ng/mL). Abdominal CT showed pancreatic tail cancer abutting to spleen and stomach. He

expired due to sepsis after 1 month of ICU care. The last case (84/F) showed aphasia and right hemiparesis. Brain DWI showed acute CI involving Lt MCA territory and multi-focal infarction in cerebellum and right hemisphere. Level of D-dimer was also significantly elevated (3200ng/mL), and CT showed multiple metastatic lesions in lung and liver, and the pancreatic head cancer.

Conclusion: In all cases, ischemic lesions were multiple scattered pattern on DWI, and the levels of D-dimer were significantly increased. In patients with stroke with these features should be evaluated the occult malignancy.

#### **EFFECTS OF TREADMILL GAIT TRAINING WITH VARIED INCLINATION ON EEG IN STROKE PATIENTS**

**SM Kim<sup>1</sup>**, KH Kim<sup>2</sup>, DH Kim<sup>2</sup>, SH Jang<sup>1</sup>

<sup>1</sup>*Physical Therapy, Korea National University of Transportation, South Korea*

<sup>2</sup>*Physical Therapy, Gimcheon University, South Korea*

The purpose of this study was to investigate the effect on EEG of stroke patients when gradually increasing the inclination during treadmill gait training. The subjects of this study were selected as 3 stroke patients who were diagnosed with stroke within 6 months and were able to walk on a treadmill. EEG electrode attachment sites were attached to the Fp1, Fp2, F3, F4, C3, C4, P3, and P4 positions of the cerebral hemispheres using the International 10-20 system. The intervention was to walk for 2 minutes each at 0 degrees, 15 degrees, and 30 degrees while looking at the target point located in front during treadmill gait training. At this time, the EEG (Smaringmobi, Serbia) generated when the treadmill gradient gradually increased was measured. In addition, relative alpha and relative beta waves were visualized through the Brain mapping program in the TeleScan program to check the changes in each brain region for the activity of the EEG. As a result of this study, the relative alpha wave value decreased as the treadmill inclination increased, and the relative beta wave value increased. This suggests that the method of gradually increasing the incline during treadmill gait training is an important parameter to increase the brain activity level of stroke patients.

**ACKNOWLEDGEMENT:** This research was supported by “Regional Innovation Strategy(RIS)” through the National Research Foundation of Korea(NRF) funded by the Ministry of Education(MOE)(2021RIS-001).

**A CHALLENGE TO DIAGNOSING SUBCLAVIAN ARTERY OCCLUSION IN A PATIENT WITH LUNG CANCER PRESENTING ACUTE UNILATERAL UPPER EXTREMITY WEAKNESS**

**Dae-Hyun Kim<sup>1</sup>**, Eungseok Oh<sup>2</sup>, Jong-Wook Shin<sup>2</sup>, Hye-Seon Jeong<sup>2</sup>

<sup>1</sup>*Department of Neurology, Dong-A University Hospital, South Korea*

<sup>2</sup>*Department of Neurology, Chungnam National University Hospital, South Korea*

**Background:** It can be a challenge for a physician in an emergent situation to differentiate the cause of unilateral upper limb weakness. A close physical and neurologic examination can help find a path to the correct diagnosis. We experienced a case of subclavian artery occlusion presented as an acute onset upper limb weakness caused by emboli from newly diagnosed lung cancer.

**Case:** A 92-year-old female complained of left arm weakness, 30 minutes ago. She had weak hand in the left involving extensors with pale skin color and felt durable pain with paresthesia. There was no cortical sign in the weak hand. As an abrupt onset of her symptom, we activated the stroke code. In diffusion-weighted MR images, there was no evidence of acute ischemic stroke. Instead, contrast-enhanced MR angiography depicted no presence of flow after the left proximal subclavian artery. With suspicion of artifact versus subclavian artery occlusion, retrograde physical examination revealed pulseless in the left radial and brachial artery with uncheckable blood pressure. We confirmed left subclavian artery occlusion, and planned emergent surgical thrombectomy. Chest x-ray implied the emboli originated from the lung mass. The pathology of emboli revealed adenocarcinoma.

**Conclusion:** We showed a patient with a unilateral subclavian artery occlusion as a presentation of lung cancer. A close physical examination could elucidate the cause of unilateral upper extremity weakness. The measuring blood pressure from both arms, pulse taking, and pale skin color could be the clue to the

differentiation between limb ischemia from cerebral cortical infarct

**EARLY ISOLATED SUBARACHNOID HEMORRHAGE VERSUS HEMORRHAGIC INFARCTION IN CEREBRAL VENOUS THROMBOSIS**

**Jan Kobal<sup>1</sup>**, Ksenija Cankar<sup>2</sup>, Borna Vudrag<sup>3</sup>, Lucijan Kobal<sup>4</sup>, Katarina Surlan Popovic<sup>4</sup>

<sup>1</sup>*Department of Neurology, UMC Ljubljana, Slovenia*

<sup>2</sup>*Institute of Physiology, University of Ljubljana, Faculty of Medicine, Slovenia*

<sup>3</sup>*Neurology Service, Izola General Hospital, Slovenia*

<sup>4</sup>*Institute of Radiology, UMC Ljubljana, Slovenia*

**Background.** Cerebral venous thrombosis (CVT) is a rare cerebral vascular disease, the presentation of which is highly variable clinically and radiologically. A recent study demonstrated that isolated subarachnoid hemorrhage (iSAH) in CVT is not as rare as thought previously and may have a good prognostic significance. Hemorrhagic venous infarction, however, is an indicator of an unfavorable outcome. We therefore hypothesized that patients who initially suffered iSAH would have a better clinical outcome than those who suffered hemorrhagic cerebral infarction.

**Patients and methods.** We selected patients hospitalized due to CVT, who presented either with isolated SAH or cerebral hemorrhagic infarction at admission or during the following 24 hours: 23 (10 men) aged 22–73 years. The data were extracted from hospital admission records, our computer data system, and the hospital radiological database.

**Results.** The iSAH group consisted of 8 (6 men) aged  $49.3 \pm 16.2$  and the hemorrhagic infarction group included 15 (4 men) aged  $47.9 \pm 16.8$ . Despite having a significantly greater number of thrombosed venous sinuses/deep veins (Mann-Whitney Rank Sum Test,  $p = 0.002$ ), the isolated SAH group had a significantly better outcome on its modified Rankin Score (mRs) than the hemorrhagic infarction group (Mann-Whitney Rank Sum Test,  $p = 0.026$ ). Additional variables of significant impact were edema formation ( $p = 0.004$ ) and sulcal obliteration ( $p = 0.014$ ).

Conclusions. The patients who suffer iSAH initially had a significantly better outcome prognosis than the hemorrhagic infarction patients, despite the greater number of thrombosed sinuses/veins in the iSAH group. A possible explanation might include patent superficial cerebral communicating veins.

#### **RETINOIC ACID REDUCES OXIDATIVE STRESS AND REDUCES THIOREDOXIN EXPRESSION IN FOCAL CEREBRAL ISCHEMIA**

**Phil-Ok Koh<sup>1</sup>, Ju-Bin Kang<sup>1</sup>**

*Department of Veterinary Anatomy and Histology,  
College of Veterinary Medicine, Gyeongsang  
National University, South Korea*

Brain ischemia is a serious neurological disorder caused by increasing oxidative stress. Retinoic acid is a vitamin A metabolite. It has the ability to regulate oxidative stress and exerts neuroprotective effects. Thioredoxin is a small redox protein with antioxidant activity. The aim of this study was to investigate whether retinoic acid modulates the expression of thioredoxin in ischemic brain injury. Cerebral ischemia was induced by middle cerebral artery occlusion (MCAO) surgery and retinoic acid (5 mg/kg) or vehicle was administered to adult male rats for four days prior to surgery. Neurological behavioral tests were performed and cerebral cortical tissues were collected for further study. MCAO induced neurological deficits and increased oxidative stress. However, these changes were attenuated by retinoic acid treatment. Retinoic acid ameliorated the MCAO-induced decrease in thioredoxin expression. Immunoprecipitation showed that MCAO decreases the interaction between thioredoxin and apoptosis signal-regulating kinase 1 (ASK1), and retinoic acid treatment alleviates this decrease. These results demonstrate that retinoic acid regulates oxidative stress and thioredoxin expression, maintains the interaction between thioredoxin and ASK1, and modulates apoptosis-associated proteins. Taken together, these results suggest that retinoic acid has neuroprotective effects by reducing oxidative stress and regulating thioredoxin expression.

#### **U-SHAPED ASSOCIATIONS BETWEEN GLYCATED ALBUMIN AND OBESITY AND ROLE OF IL-10 IN HYPERACUTE ISCHEMIC STROKE**

**S-H Lee, C Kim, M Lee**

*Department of Neurology, Hallym University  
College of Medicine, South Korea*

Background: There is growing interest to use a new biomarker such as glycated albumin (GA). Contrast to glycated hemoglobin (HbA1c), GA showed inverse correlation with prestroke obesity status, but data are limited in ischemic stroke (IS).

Aims: We explored the associations between GA and body mass index (BMI) and investigated the inflammatory cytokines to support the academic background.

Methods: A total of 155 patients with hyperacute IS between 2011 and 2019 were included. To identify the association between GA and BMI, patients were divided into four groups according to the BMI quartiles. Inflammatory cytokines including (IL-1 $\beta$ , IL-10, IL-6, TNF- $\alpha$  and TNF-R1) were determined by ELISA kit using a ProcartaPlex multiplex immunoassay.

Results: Among the 155 patients, the mean age was 68 $\pm$ 12 years, and 67.1% were men.

The lowest BMI group had higher GA levels (GA 2T and 3T =80%) (p-value=0.017) and these U-shaped associations were maintained only in SVO etiology (p-value= 0.004). Plasma levels of IL-10 was positively correlated with BMI and showed U-shaped pattern (p-value= 0.001).

Conclusions: The GA level and BMI had U-shaped associations in hyperacute IS. IL-10 acting as a protective cytokine for cardiovascular disease might be a novel role for this association. Although the GA is emerging favorable clinical marker for cardiovascular outcomes, obesity status should be considered to interpret those associations.

## THERAPEUTIC DILEMMAS IN CRYPTOGENIC STROKE

Aleksandar Professor<sup>1</sup>, **A. Lucic-Prokin**<sup>1</sup>,  
M. Zarkov<sup>1</sup>, J. Nikovic<sup>2</sup>, R. Pejcin<sup>3</sup>,  
Svetlana Ruzicka Kaloci<sup>1</sup>

<sup>1</sup>*Department of Neurology, University of Novi Sad, Medical Faculty, Serbia*

<sup>2</sup>*Department of Nursing, University of Novi Sad, Medical Faculty, Serbia*

<sup>3</sup>*Department of Internal Medicine, University of Novi Sad, Medical Faculty, Serbia*

**BACKGROUND:** Cryptogenic stroke makes about one-third of all strokes. Possible causes that are most mentioned are atrial fibrillation, patent foramen ovale, large artery atherosclerosis and thrombophilia, but some other, rare conditions could also be responsible.

**CASE REPORT:** Female patient, 60 years old, presented with right-sided weakness, and right-sided facial palsy. Patient's history reveals that she had stroke with similar symptoms two weeks before this accident, as well as two years ago. She also presented with progressive cognitive impairment. Twice performed MRI revealed multiple territorial infarctions in different regions and both sides, while MRA showed multiple endocranial saccular aneurysms. Fibromuscular dysplasia was mentioned, but not confirmed. Doppler ultrasound showed no traces of atherosclerosis, while transcranial bubble test implies minor patent foramen ovale. Patient has history of hypertension and hypercholesterolemia. Anti-platelet therapy proved to be unsuccessful, other therapeutic possibilities are considered.

**CONCLUSION:** Multiple, successive strokes are still of unclear etiology. Therapeutic dilemmas persist, with questioned efficiency of anti-platelet therapy.

## PROGNOSTIC FACTORS OF ACUTE STROKE WITH LARGE ISCHEMIC CORE TREATED BY MECHANICAL THROMBECTOMY

**Man Seok Park**<sup>1</sup>, Eun-Bi Ma<sup>1,2</sup>, Kang-Ho Choi<sup>1</sup>,  
Joon-Tae Kim<sup>1</sup>, Seong-Min Choi<sup>1</sup>, Ki-Hyun Cho<sup>1</sup>

<sup>1</sup>*Department of Neurology, Chonnam National University Medical School & Hospital, South Korea*

<sup>2</sup>*College of Pharmacy, Chonnam National University, South Korea*

**Background:** The benefits of mechanical thrombectomy (MT) for patients with acute ischemic stroke (AIS) and a large ischemic core at presentation are uncertain. We investigated the clinical and imaging factors associated with favorable outcome at 90 days in acute stroke patients with a large baseline ischemic core treated with MT.

**Methods:** Data from the CNUH (Chonnam National University Hospital) stroke registry of consecutive acute ischemic stroke patients treated with MT from January 1, 2016, to December 31, 2020, were retrospectively analyzed. Baseline large ischemic core was defined as diffusion-weighted imaging (DWI)–Alberta Stroke Program Early CT (ASPECT) Score of  $\leq 5$ . The degree of disability was assessed by the modified Rankin Scale (mRS) at 90 days. Favorable outcome was defined as mRS score of  $\leq 2$  at 90 days.

**Results:** Among 92 patients with DWI-ASPECT Score of  $\leq 5$  treated with MT, favorable outcome was achieved in 37 (40.2%) patients at 90 days. Symptomatic hemorrhagic transformation was detected in 12 (13.04%) patients within 24 hours post-MT. Younger age ( $p=0.04$ ), successful recanalization ( $p=0.02$ ), low baseline HbA1C ( $p=0.045$ ) and prior statin use ( $p=0.005$ ) predicted favorable outcome at 90 days. However, hemorrhagic transformation was related with unfavorable outcome. NLR (neutrophil-lymphocyte ratio) was not associated with short-term prognosis at 90 days. ( $p=0.168$ )

**Conclusion:** Successful recanalization, low baseline HbA1C and prior use of statin are the strong predictors of favorable outcome in stroke patients with a large ischemic core. However, development of the hemorrhagic transformation is associated with unfavorable outcome.

## CEREBELLAR DEVELOPMENTAL VENOUS ANOMALY PRESENTING WITH RECURRENT VERTIGO

**Key-Chung Park**<sup>1</sup>, HY Rhee<sup>2</sup>

<sup>1</sup>*Department of Neurology, Kyung Hee University College of Medicine, Kyung Hee University Medical Center, South Korea*

<sup>2</sup>*Department of Neurology, Kyung Hee University College of Medicine, Kyung Hee University Hospital at Gangdong, South Korea*

A developmental venous anomaly (DVA) is an unusual or irregular arrangement of small veins that look like the spokes of a wheel, which is most located in the frontoparietal region followed by the cerebellar hemisphere. We present a case of cerebellar DVA mimicking peripheral vestibular disorder as a possible cause of central vertigo. A 71-year-old woman was admitted to Department of Neurology of our hospital for the development of several recurrent vertigo over the past 7 years. The vertigo had suddenly developed with nausea and vomiting and lasted for several hours and aggravated after the positional change. Neurological examination showed right-beating spontaneous nystagmus on the right gaze. The bedside head impulse test in bare eyes was negative. Alternating cover tests for skew deviation revealed no abnormality. Audiometric assessment revealed no abnormality. T2-weighted MRI revealed DVA in the left cerebellar hemisphere where the small veins in the form of a spoke of wheel, originating from the left cerebellar hemisphere, ran backwards, passed adjacent to the Lt vermis and merged into a straight sinus. DVA is often encountered incidentally as it tends to be asymptomatic and follow a benign course but it becomes symptomatic under rare circumstances associated with mechanical or flow-related events. Based on the clinical findings, it is possible the vertigo was central origin and the DVA in the left cerebellar hemisphere is associated with the vertiginous attacks through the venous congestion or neurovascular contact although they were not clearly depicted on the imaging.

## AN UNUSUAL PATTERN OF BLEEDING IN A POST PARTUM FEMALE; ATYPICAL PRESENTATION OF SUBARACHNOID HEMORRHAGE.

J. Kito<sup>1</sup>, **A. Rama**<sup>2</sup>, M. Grada<sup>3</sup>, A. Rroji<sup>4</sup>, E. Ranxha<sup>5</sup>

<sup>1</sup>*Emergency Department, UHC Mother Theresa, Albania*

<sup>2</sup>*Neurology Department, Faculty of Medicine, UHC Mother Theresa, Albania*

<sup>3</sup>*Neurosurgery Department, UHC Mother Theresa, UHC Mother Theresa, Albania*

<sup>4</sup>*Neuroimaging Department, UHC Mother Theresa, Albania*

<sup>5</sup>*Head of Neurovascular Service, UHC Mother Theresa, Albania*

Subarachnoid haemorrhage (SAH) is the accumulation of blood between the arachnoid and pia mater. There are known both modifiable and non modifiable risk factors. The typical presenting symptom is the thunderclap headache, which patients often describe as the “worst headache of my life.” SAH is a neurologic emergency with substantial morbidity and mortality and most non traumatic causes of SAH (~85%) are caused by the rupture of an intracranial aneurysm. 15-20% of patients presenting with SAH do not have an identifiable vascular lesion on the initial Digital Subtraction Angiography (DSA).

We present the case of a 33-year-old female, presented in the ED complaining of an acute onset of right limb numbness, followed by a thunderclap headache, with a severity 10/10. Her neurological examination was normal, there was no neck stiffness and no focal neurological deficits. She was two months post-partum with an uncomplicated pregnancy and delivery. Computed Tomography (CT) scan showed significant amount of subarachnoid blood accumulated across the left cortical convexity, the left Sylvian fissure, and the basal cisterns. DSA showed no vascular abnormalities. Non-aneurysmal, non-perimesencephalic pattern of bleeding in a post-partum patient, is an unusual presentation of SAH. Control DSA is needed in the future for accurate diagnosis of our patient.

## CAVERNOUS SINUS DURAL ARTERIOVENOUS FISTULA

Eni Reka<sup>1</sup>, A Rroji<sup>2</sup>, E Enesi<sup>2</sup>

<sup>1</sup>Neurology, University Hospital Center (Uhc)

“Mother Theresa, Albania

<sup>2</sup>Neuroimaging, University Hospital Center (Uhc)

“Mother Theresa, Albania

**Introduction:** Carotid-cavernous fistulas (CCFs) are vascular shunts between carotid artery and the cavernous sinus. Direct Cavernous Sinus Dural Arteriovenous Fistula (CS-DAF) are high-flow fistulas usually traumatic and treated by the endovascular therapy, a small percentage are spontaneous or caused by the rupture of a cavernous aneurysm into the sinus.

**Case presentation:** We present the case of a 59-year-old right-handed woman treated for a period of 3-months with anticoagulation for a mistaken diagnosis of sinus thrombosis; with worsening symptoms of a painful exophthalmos in the left eye, with conjunctival chemosis and diplopia. The patient had no motor or sensory deficits and no evident markings on neurological examination, whereas on the ophthalmological examination the left eye had a visual acuity of 5/10 with ophthalmoplegia, an increased intra ocular pressure of 34.

**Results:** The next day of hospitalization a DSA was performed revealing a CS-DAF which was categorized as direct flow. Therapeutic options including conservative management, open surgery, endovascular intervention, and radiosurgery therapy are usually the approach in CCFs; with direct fistulas usually embolized. In this case even though the fistula was of direct flow, it was managed conservatively due to the fact that it was not associated with significant risk of intracranial hemorrhage. Follow Up imaging and clinical evaluation showed total resolution of the disease after 3 months.

**Conclusion:** CS-DAF are rare vascular disorders which usually need embolization, but conservative treatment and watchful waiting is often recommended in certain cases where the clinical and radiological features allow us not to treat.

## HYPERCOAGULABILITY ASSOCIATED WITH COVID-19 INFECTION: A CASE REPORT OF MULTIPLE ARTERIAL THROMBOEMBOLISM AND ACUTE ISCHEMIC STROKE

A. Repic Bulicic, M. Gabelica, M. Marcic, J. Budisa, K. Caljkusic

Neurology Department, University Hospital of Split, Croatia

An 82-year-old female patient who had suddenly developed left-sided weakness arrived at the emergency room. She has had arterial hypertension and multiple sclerosis for a long period. She was not taking anticoagulant therapy despite being aware of atrial fibrillation and had not received a COVID-19 vaccination or recovered from the virus.

At the time of admission, the patient was febrile up to 37.5°C, tachypnoeic, coughing. Auscultation of the lungs revealed bilateral crepitations, and ECG findings confirmed atrial fibrillation. The neurological investigation demonstrated significant left hemiparesis and left-sided central facial paresis; the patient also suffered from dysarthria (NIHSS 12).

The brain's MSCT scan detected no signs of recent ischemia. However, MSCT angiography revealed that the brachiocephalic trunk's lumen was noticeably narrowed by a partially recanalized thrombus. A partially recanalized thrombus and borderline stenosis at the origin of the left ICA were also detected, and finally, due to thrombosis, the right VA's V3 segment was essentially not visible. In addition to the report, a calcified plaque and borderline stenosis were observed at the right ICA's originating point. Intracranial LVO was absent. After laboratory results revealed high WBC, CRP, and PCT levels, the X-ray imaging confirmed bilateral pneumonia.

Azithromycin, amoxicillin/clavulanic acid along with oxygen therapy were initiated due to signs of acute respiratory insufficiency. Neurologic deficit spontaneously improved to NIHSS 2. LMWH in a therapeutic dose was also administered.

### NEUROPSYCHOLOGICAL PROFILE OF PATIENTS WITH SUBCORTICAL VASCULAR NEUROCOGNITIVE DISORDER

Anna Tsiakiri<sup>1,4</sup>, P. Vlotinou<sup>1,4</sup>, S. Mavromati<sup>2,4</sup>, D. Tsiptsios<sup>1,4</sup>, C. Kokkoti<sup>3,4</sup>, S. Kyriazidou<sup>1,4</sup>, P. Bebeletsi<sup>2,4</sup>, E. Lazaridou<sup>2,4</sup>, E. Tziaka<sup>2,4</sup>, N. Aggelousis<sup>3,4</sup>, K. Vadikolias<sup>1,4</sup>

<sup>1</sup>Neurology, Democritus University of Thrace, Greece

<sup>2</sup>Medicine, Democritus University of Thrace, Greece

<sup>3</sup>Physical Education, Democritus University of Thrace, Greece

<sup>4</sup>Project "Study of the interrelationships between neuroimaging, neurophysiological and biomechanical biomarkers in stroke rehabilitation (NEURO-BIO-MECH in stroke rehab)" (MIS 5047286), Operational Program : "Competitiveness, Entrepreneurship and Innovation" an co-financed by Greece and the European Union (European Regional Development Fund)., Greece

**Introduction:** Vascular Neurocognitive Disorder (VND) is due to vascular or circulatory damages caused by ischemic or hemorrhagic cerebrovascular disease. In clinical practice, VND is defined by three elements a) presence of dementia clinically, b) evidence of cerebral vascular pathology and c) exclusion of other conditions that can cause dementia. This classification leads to two clinical subtypes: a) poststroke dementia and b) subcortical VND.

**Methods:** The main purpose of the present study was to study the cognitive, executive and emotional functioning of 44 patients diagnosed with subcortical VND, according to DSM-V. According to the study design, all participants were evaluated in the full series of neuropsychological testing at baseline, after 6 and 12 months.

**Results:** During the 18-month follow-up, statistically significant reduction was presented in the cognitive domains of orientation ( $p=0.002$ ), language ( $p=0.003$ ), memory ( $p=0.019$ ), perception ( $p=0.004$ ), confrontation ( $p=0.000$ ), in the activities of daily living ( $p=0.001$ ) and in the emotional functioning ( $p=0.011$ ).

**Discussion:** From the outline of the performances, it was detected a neuropsychological profile characterized by a disturbance in the sections of semantic

memory, working memory, abstract reasoning, visuospatial ability and executive functioning. VND appears to be associated with extensive alteration of cognitive and executive functions as well as with the burden of neuropsychiatric symptoms. To sum up, it is considered necessary to evaluate and monitor all aspects of functioning through sensitive neuropsychological test aiming to early detection and comprehensive management of the specific clinical group.

### CHOICE OF SHOULDER MUSCLES FOR THE MULTI-PATTERN TREATMENT OF UPPER LIMB SPASTICITY WITH BOTULINUM NEUROTOXIN INJECTIONS

Hannah Williams<sup>1</sup>, A. Camões Barbosa<sup>2</sup>, S. Carda<sup>3</sup>, D. Hoad<sup>4</sup>, J. Jacinto<sup>5</sup>

<sup>1</sup>Department of Neurorehabilitation and Physical Therapy, Vivantes Hospital Spandau, Germany

<sup>2</sup>Medicina Física e Reabilitação de Adultos, Centro Hospitalar Universitário de Lisboa Central, Portugal

<sup>3</sup>Neuropsychology & Neurorehabilitation, CHUV, Switzerland

<sup>4</sup>Warwick Medical School, University of Warwick, UK

<sup>5</sup>Serviço De Reabilitação De Adultos 3, Centro De Medicina De Reabilitação De Alcoitão, Portugal

**Background:** Botulinum neurotoxin (BoNT) is a first-line treatment for post-stroke spasticity, reducing pain and involuntary movements and helping restore function. BoNT is not routinely injected into shoulder muscles, despite clinical trials demonstrating improvements in shoulder pain and function after BoNT injection.

**Objective:** To present expert consensus on the use of BoNT injections in the multi-pattern treatment of shoulder spasticity.

**Methods:** Following a pre-meeting survey on preferred treatment practices, a two-part meeting was held online in 2021. Five European experts with ~100 years' cumulative experience in post-stroke spasticity gave presentations on shoulder spasticity and treatment with BoNT injections, followed by discussion.

**Results:** Traditionally, when using BoNT to treat shoulder spasticity, target muscles were chosen

based on the spastic pattern and underlying functional anatomy. The expert consensus proposed a more patient-centred approach: identify which activities are limited by the spastic shoulder and consider treating the muscles involved in hindering those activities. Two patterns of shoulder spasticity were identified. For adduction, elevation/flexion and internal rotation of the shoulder, injecting the pectoralis major and teres major was recommended in most cases; for abduction or adduction, extension and internal rotation of the shoulder, injecting the posterior part of the deltoid, teres major and latissimus dorsi was recommended in most cases.

**Conclusions:** Choice of shoulder muscles for BoNT injection can be based on spasticity pattern, but functional limitation and patient expectations should be considered to establish more patient-centred treatment goals. These recommendations will benefit clinicians who may not be experienced in evaluating and treating spastic shoulders.

#### **SPATIO-TEMPORAL CHARACTERISTICS UNDER SIMPLE/DUAL TASK GAIT OF PATIENTS WITH CEREBRAL SMALL VESSEL DISEASE**

**Pinelopi Vlotinou**<sup>1,4</sup>, A. Tsiakiri<sup>1,4</sup>, S. Fotiadou<sup>1,4</sup>, E. Giannakou<sup>3,4</sup>, C. Kokkotis<sup>3,4</sup>, S. Mavromati<sup>2,4</sup>, K. Vadikolias<sup>1,4</sup>, N. Aggelousis<sup>3,4</sup>

<sup>1</sup>Neurology, Democritus University of Thrace, Greece

<sup>2</sup>Medicine, Democritus University of Thrace, Greece

<sup>3</sup>Physical Education and Sport Science, Democritus University of Thrace, Greece

<sup>4</sup>Project "Study of the interrelationships between neuroimaging, neurophysiological and biomechanical biomarkers in stroke rehabilitation (NEURO-BIO-MECH in stroke rehab)" (MIS 5047286), Operational Program : "Competiveness, Entrepreneurship and Innovation" an co-financed by Greece and the European Union (European Regional Development Fund)., Greece

**Background:** Dual task walking (DTW), is common in everyday living. Under DTW and Single- task walking (STW) conditions the gait pattern does not always remain stable, especially in elderly. More specific patients suffering from cerebral small vessel disease (CSVD) present difficulties in movement and walking in particular. Although spatiotemporal characteristics of gait seem to be affected, there are not well established yet through research data.

**Research question:** Is there any differentiation in spatiotemporal parameters, under simple task walking (STW) and DTW in CSVD patients?

**Method:** 3 elderly patients (70y ±2) with CSVD were recruited. Patient's gait was monitored by a 3D Gait analysis System, under two conditions, STW and DTW. Spatiotemporal characteristics: Walking Frequency, Single Support Duration, Double Support Duration, Stride length and Walking Speed were compared under the two situations.

**Results:** The gait cycle was divided in right and left, in order to accelerate possible differentiation according to the dominant leg. Comparing the gait parameters under DTW and STW in CSVD results, for both dominant (dl) /non- dominant leg (ndl): differences in single support duration (dl: F3,6= 1.746, p.01, ndl : F3,6= 5.938, p.005) and frequency (dl: F3,6= 12.584, p.01, ndl: F3,6= 17.097, p.005)) was revealed. On the contrary, no stride length or gait speed differences were found.

**Conclusion:** The spatiotemporal characteristics under STW and DTW could be described as biomarkers for gait dysfunction in elderly patients suffering from CSVD. In this study, Gait parameters bear a greater burden under a greater load, as in DTW.

#### **UNILATERAL HYPERKINETIC DYSKINESIA IN PATIENTS AFTER ACUTE ISCHEMIC STROKE OUTSIDE BASAL GANGLIA AS VASCULAR HEMICHOREA-HEMIBALLISM OR LIMB-SHAKING TRANSIENT ISCHEMIC ATTACK**

**Hak Young Rhee**<sup>1</sup>, KC. Park<sup>2</sup>, HJ. Kang<sup>3</sup>

<sup>1</sup>Department of Neurology, Kyung Hee University College of Medicine, Kyung Hee University Hospital at Gangdong, South Korea

<sup>2</sup>Department of Neurology, Kyung Hee University College of Medicine, Kyung Hee University Medical Center, South Korea

<sup>3</sup>Department of Physical Medicine and Rehabilitation, Veterans Health Service Medical Center, South Korea

Hemichorea-hemiballism can develop suddenly in patients with acute ischemic stroke (AIS) in the specific brain region and it is well-known that subthalamic nucleus is responsible for the development of dyskinesia. But it has been reported that lesions outside basal ganglia are associated with the development of hemichoreoballism after the stroke.



Limb-shaking transient ischemic attack (TIA) is also well-known for post-stroke involuntary movement. We describe two cases of unilateral hyperkinetic dyskinesia in patients after AIS and discuss vascular hemichorea-hemiballism and limb-shaking TIA. Limb-shaking TIA is focused on the episodic and repetitive development and resolution of the symptom but the involuntary movement has been described grossly as limb-shaking which includes several types of dyskinesia such as tremor, myoclonus or choreoballism. For the lesion in the cortical area causing unilateral hyperkinetic dyskinesia, there would be an overlap in the type of dyskinesia between cortical hemichorea-hemiballism after cerebral infarction and limb-shaking TIA that have been reported.

#### **CHOICE OF SHOULDER MUSCLES FOR THE MULTI-PATTERN TREATMENT OF UPPER LIMB SPASTICITY WITH BOTULINUM NEUROTOXIN INJECTIONS**

**Hannah Williams<sup>1</sup>**, A. Camões Barbosa<sup>2</sup>, S. Carda<sup>3</sup>, D. Hoad<sup>4</sup>, J. Jacinto<sup>5</sup>

<sup>1</sup>*Department of Neurorehabilitation and Physical Therapy, Vivantes Hospital Spandau, Germany*

<sup>2</sup>*Medicina Física e Reabilitação de Adultos, Centro Hospitalar Universitário de Lisboa Central, Portugal* <sup>3</sup>*Neuropsychology & Neurorehabilitation, CHUV, Switzerland*

<sup>4</sup>*Warwick Medical School, University of Warwick, UK*

<sup>5</sup>*Serviço De Reabilitação De Adultos 3, Centro De Medicina De Reabilitação De Alcoitão, Portugal*

**Background:** Botulinum neurotoxin (BoNT) is a first-line treatment for post-stroke spasticity, reducing pain and involuntary movements and helping restore function. BoNT is not routinely injected into shoulder muscles, despite clinical trials demonstrating improvements in shoulder pain and function after BoNT injection. **Objective:** To present expert consensus on the use of BoNT injections in the multipattern treatment of shoulder spasticity. **Methods:** Following a pre-meeting survey on preferred treatment practices, a two-part meeting was held online in 2021. Five European experts with ~100 years' cumulative experience in post-stroke spasticity gave presentations on shoulder spasticity and treatment with BoNT injections, followed by discussion. **Results:** Traditionally, when using BoNT to treat shoulder spasticity, target muscles were chosen based on the spastic pattern and underlying functional anat-

omy. The expert consensus proposed a more patient-centred approach: identify which activities are limited by the spastic shoulder and consider treating the muscles involved in hindering those activities. Two patterns of shoulder spasticity were identified. For adduction, elevation/flexion and internal rotation of the shoulder, injecting the pectoralis major and teres major was recommended in most cases; for abduction or adduction, extension and internal rotation of the shoulder, injecting the posterior part of the deltoid, teres major and latissimus dorsi was recommended in most cases. **Conclusions:** Choice of shoulder muscles for BoNT injection can be based on spasticity pattern, but functional limitation and patient expectations should be considered to establish more patient-centred treatment goals. These recommendations will benefit clinicians who may not be experienced in evaluating and treating spastic shoulders

#### **CONTROVERSIES REGARDING THE DIFFERENTIAL DIAGNOSIS BETWEEN HEMORRHAGIC STROKE DUE TO RUPTURED ARTERIOVENOUS MALFORMATION AND A BRAIN TUMOR IN A PATIENT WITH ONSET OF COMA**

**A.L. Zaharia<sup>1</sup>**, A. Croitoru<sup>1</sup>, A.M. Păduraru<sup>3</sup>, C. Marinescu<sup>2</sup>, D.C. Voinescu<sup>1</sup>, M. Chetronu<sup>4</sup>, M. Lungu<sup>1</sup>

<sup>1</sup>*Clinical, Faculty of Medicine and Pharmacy, Lower Danube University of Galati, Romania, Romania*

<sup>2</sup>*Neurosurgery, Clinical Emergency Hospital of Galati, Romania, Romania*

<sup>3</sup>*Internal Medicine, Clinical Emergency Hospital of Galati, Romania, Romania*

<sup>4</sup>*Anatomopathology, Clinical Emergency Hospital of Galati, Romania, Romania*

In neurological and neurosurgical practice, a differential diagnosis between a brain tumor - possibly with necrosis and intratumoral hemorrhage, versus a cerebral hemorrhage - possibly through ruptured arteriovenous malformation, can be challenging. Imaging support and, in some cases, neurosurgery can establish the diagnosis.

We present the case of a 64-year-old female patient, with a history of cardiovascular disease, who suddenly entered a 3 points GCS coma. Initial imaging evaluation by cerebral computed tomography reveals an extensive complex lesion in the left cere-

bral hemisphere, with multiple serpentine trajectories displacing the midline by 16 mm and extending into the brainstem. Neurological and neurosurgical examinations raised the suspicion of cerebral hemorrhage due to complex arteriovenous malformation of the left hemisphere. In the following 24 hours, the patient's general condition improved and she was re-evaluated by imagistic investigation, and the result raised the suspicion of a left hemisphere tumor lesion with spontaneously hyperdense calcified serpinginous trajectories. Under these conditions, neurosurgical intervention was performed, intraoperatively detecting the dural tension, an infiltrative

greyish-yellowish tumorous formation with a rich vascular component, with tumor ablation of 5/4/3 cm from the lesion. Later, the histopathological examination established the diagnosis of oligodendroglioma. The evolution was unfavorable with the death of the patient 8 days after admission.

Although in this case, the onset and the initial clinical-imaging evaluation suggested a cerebral hemorrhage due to a ruptured arterio-venous malformation, the final diagnosis was established intraoperatively with the detection of a highly vascularized tumor.

## NEXT EDITION

**SAVE THE DATE**

**CONY**

**The 18<sup>th</sup> World Congress on  
CONTROVERSIES IN NEUROLOGY**  
March 21-23, 2024 | London, UK

[cony2024.comtecmed.com](http://cony2024.comtecmed.com)