

## Case Report

---

# Constitutional trisomy 8 mosaicism syndrome: case report and review

Achandira M. Udayakumar<sup>a,\*</sup> and Adila Al-Kindy<sup>b</sup>

<sup>a</sup>*Cytogenetics Unit, Department of Genetics, College of Medicine and Health Sciences, Sultan Qaboos University, Muscat, Sultanate of Oman*

<sup>b</sup>*Clinical Genetics Unit, Department of Genetics, Sultan Qaboos University Hospital, Muscat, Sultanate of Oman*

Received 7 September 2013

Revised 6 December 2013

Accepted 21 December 2013

**Abstract.** Trisomy 8 mosaicism (Warkany syndrome) is a rare viable condition with variable phenotypes, ranging from mild dysmorphic features to severe malformations. Karyotyping and fluorescence in-situ hybridization potentially help detecting this low mosaic clone to confirm the diagnosis of patients with classical and unusual clinical presentations. This report reviews few previous cases to describe our case - a boy who had trisomy 8 mosaicism with severe dysmorphic features, born to a consanguineous Arabic couple. This study concludes that careful cytogenetic diagnoses of trisomy 8 mosaicism is essential for appropriate management and follow up of this rare disorder.

Keywords: Dysmorphic features, FISH, trisomy 8 mosaicism, Warkany syndrome

## 1. Introduction

Constitutional trisomy 8 mosaicism syndrome (T8MS), also known as Warkany syndrome, is a rare viable condition reported in 1/25,000 to 50,000 live births and is more prevalent in males than females (5:1) [1], and is estimated to occur in about 0.10% of recognized pregnancies [2]. Complete trisomy 8 is fatal, comprising 0.70% of first trimester miscarriage [3]. T8MS frequency is very low and so far only about 120 cases have been reported with variable clinical manifestation [4]. To the best of our knowledge, this is the first report from a consanguineous ethnic Omani Arabic population.

## 2. Case report

The propositus was a 7-year-old boy, born as a third child to a healthy, consanguineous (first cousin once removed) parents, a 35-year-old gravida 3 para 2 (G3P2) mother and a 36-year-old father of the ethnic Omani Arab descent. His mother was also seen for secondary infertility. There is a family history of learning difficulties in a 23-year-old maternal aunt. The pregnancy was complicated by polyhydramnios and he was born full term by emergency Caesarian section (indicated due to two previous caesarian-section and fetal macrosomia). He was admitted to special care baby unit for meconium aspiration syndrome and was found to be dysmorphic with multiple congenital anomalies including bilateral hydronephrosis, abnormal head shape, bilateral talipes equinovarus (requiring casting), agenesis of corpus callosum on brain imaging. Postnatal karyotype revealed mosaic trisomy 8. His birth weight

---

\*Corresponding author: Dr. Achandira M. Udayakumar, Cytogenetics Unit, Department of Genetics, College of Medicine and Health Sciences, Sultan Qaboos University, P.B. 35, P.C. 123 Muscat, Oman. Tel.: +968 24143492; Fax: +968 24413419; E-mail: uday.achandira@gmail.com.

at 3800 g was appropriate for gestational age and he was macrocephalic with his head circumference at 38 cm (above 97<sup>th</sup> percentile). At 7 yr, he was significantly delayed in all areas of development and he had mild cognitive deficit. He started to walk at 5 yr of age, his hand function was poor, and he was slow in self-care skills, severe speech and language delay was noted with expression more affected than comprehension. He could speak only few words, which were unintelligible. He had mild conductive deafness, which improved with time. He had right esotropia and amblyopia noted at the age of 2–3 yr of age. However, on the current eye examination he had alternating squint with slight dominance to the left eye with equal but reduced vision on both eyes. He was noted to have aggressive behavior and stereotyped behavior consisting of repetitive head nodding and wringing of his hands.

On examination at 7 yr of age, he was amiable person with short attention span and poor concentration and constant hyperactivity. He was short, his height and weight were below the 3<sup>rd</sup> percentile, and his head circumference on the 50<sup>th</sup> percentile, with relative macrocephaly. He showed significant craniofacial dysmorphism including scaphocephalic, plagiocephalic, long face with prominent forehead, expressionless face, with open mouth appearance, hypertelorism, down slanting palpebral fissure, broad nasal root, tubular bulbous nose, posterior rotated and low set ears with prominent helices, full lips with everted and prominent lower lip, and multiple caries. The hands had mild cutaneous syndactyly and spatula shaped fingers. He had clinodactyly and camptodactyly of the bilateral fifth fingers. His palmar creases were hypoplastic with hypoplasia of hypothenar muscle and his plantar creases were deep. He had limited elbow supination and walked with wide based gait and with knees in fixed flexed position. His feet showed asymmetry with left foot wider than the right, pes planus and 2–3 syndactyly of the toes and lateral deviated hal-luces. There were bilateral sandal gaps with extra skin appendage within the sandal gap. He had persistent scoliosis of the dorsolumbar spine, which has been operated. His anterior and posterior chest wall showed asymmetry because of his significant scoliosis. He had a relatively short neck and accessory nipple on the right. Diffuse hyperpigmentation with hypopigmented patches and streaks on his anterior chest wall, on his upper back. Hypopigmentation macules also noted on his right cheek and right side of his neck (Fig. 1). The patient was hirsute with abnormal body hair patterning on his upper back. He had large

phallus and previous right orchidopexy. Magnetic resonance imaging of brain showed agenesis of corpus callosum. His hematological tests were normal. Magnetic resonance imaging of his spine (preoperative) showed scoliosis of the dorsolumbar spine and convexity to the right with apex at lumbar 4, which is hemivertebrae. There was also sacralisation of sacral 1 vertebrae.

Conventional chromosomal analysis on peripheral blood cultures showed two cell lines: 47,XY,+8[6]/46,XY [44] (Fig. 2). Fifty metaphases analyzed, showed trisomy 8 in six and the rest 44 were normal. Florescence in situ hybridization (FISH) was performed using chromosome enumeration probe 8 (CEP 8) (Aquarius). Two hundred interphases were scored independently by two technologists. Three signals were observed in 36 nuclei (18%) confirming a clone with three copies of chromosome 8 [nuc.ish.(CEP8) X 3[36/200]. FISH done on control sample showed two signals. Karyotyping of both the parents was normal. The results were interpreted as per International System for Human Cytogenetic Nomenclature (ISCN) (2013) [5].

### 3. Discussion

The frequency of occurrence of T8MS is low and to our knowledge, there are no reports from the Arabic Middle-Eastern population, where consanguinity rate is high. Our patient with T8MS was born to consanguineous parents. There is a great phenotypic variability and its severity does not seem to be related to the degree of mosaicism in the blood or skin. This patient had long square shaped head, broad nasal root, long tubular nose, convex shaped nasal bridge, hypotelorism and posterior rotated ears as reported in several other earlier patients [6]. Similar global developmental delay, delayed speech, full lips and everted lower lips were prominent in our patient. His foot had deep plantar crease. Unlike earlier reports of optic disc coloboma and localized chorioretinal defects, our patient had right eye squint with latent nystagmus and amblyopia. Speech and language delay was observed in our patient as was earlier reported.

As reported in many earlier reports, agenesis of the corpus callosum was observed in our patient. Seizures were absent in our patient, but was reported in a 17-month-old male with T8MS [7]. There was a report of a variant of T8MS being present in the form of partial T8MS as pseudoisodicentric chromosome 8 [6]. Ruling out T8MS is crucial because trisomy of 8 is also a marker in acute leukemia and myelodysplastic syndromes, where

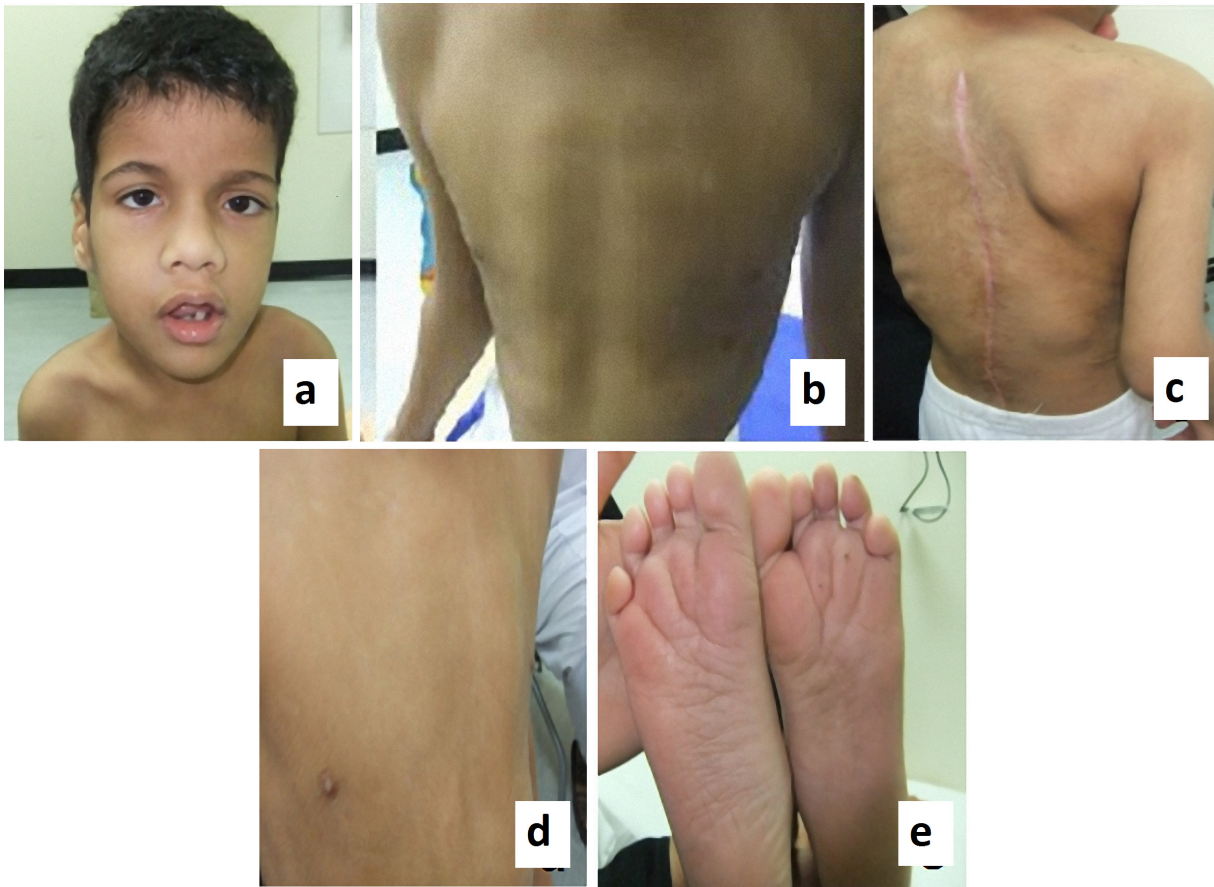

Fig. 1. Phenotype of patient showing certain key features (a) Prominent forehead, hypertelorism, strabismus, broad nasal root and wide base nose with prominent nares, open mouth appearance, everted prominent lower lip. (b) Widely spaced nipples, accessory nipple, skin pigmentary anomalies (c) Residual scoliosis abnormal position scapulae hypopigmented and hyperpigmented. (d) Whorls and streaks signifying the mosaicism. (e) Deep creases on soles.

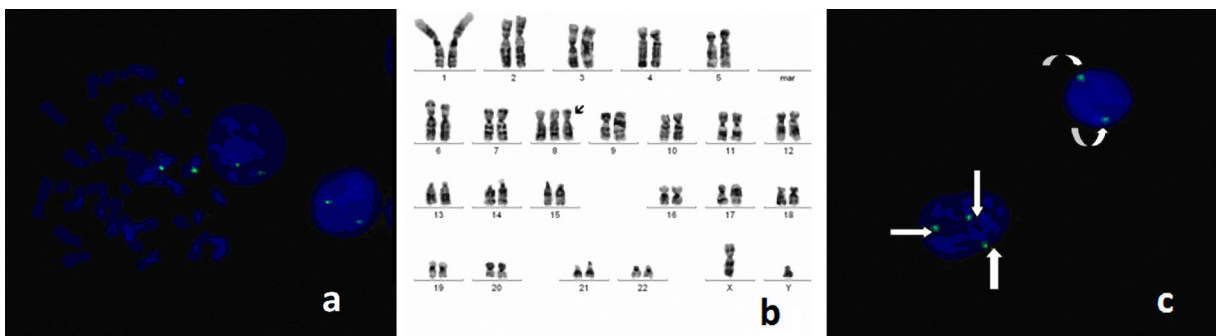


Fig. 2. (a) Field with metaphase and interphase showing two FISH signals. (b) Karyotype showing three copies of chromosome 8 (arrow). (c) Field showing interphase with three signals (arrow) and two signals (curved arrows) using CEP 8 probe (Aquarius).

in trisomy 8 is observed in bone marrow cells but in few cases there are reports, which showed T8MS in lymphocytes [8]. This could give us a clue that it could predispose those patients to leukaemogenic process [9]. All these reports provide substantial evidence that the presence of T8MS cannot be taken lightly and the screening for the same is very critical whenever any child or an adult has some classical symptoms mentioned in these earlier reports. An adult showed T8MS when investigated for lumbar spine herniated nucleus pulposus [4]. Similarly, a boy mistaken as Marfan syndrome until his karyotype showed T8MS and later managed as Warkany syndrome with atypical phenotypic features having craniofacial midline defects, including notched nasal tip, cleft maxillary alveolar ridge, bifid tip of tongue, grooved uvula and left choanal atresia with severe delay in psychomotor development [10,11]. These evidences strongly suggest that cytogenetic testing is important to detect T8MS. Additionally, more sensitive methods like FISH and array comparative genomic hybridization (aCGH) has to be adopted for testing. CGH being highly sensitive can detect dose increase of chromosome 8 even in patients showing normal karyotype with varying phenotypic features. Even skin biopsy (fibroblast culture) is useful for making the diagnosis. CGH analysis of blood DNA in a newborn suggested a 50% dose increase of chromosome 8 and 18, despite a normal standard karyotype. Child's phenotype had resemblance to both mosaic trisomy 8 and mosaic trisomy 18. Possible origin of such an error is incomplete correction of a tetraploid state resulting from failed cytokinesis or mitotic slippage during early embryonic development [12].

Investigation of epigenetic pattern associated with aneuploidy - trisomy 8 positive fibroblast displayed a characteristic expression and methylation phenotype distinct from disomic fibroblasts, with the majority (65%) of chromosome 8 genes in the trisomic cells being overexpressed. Trisomy 8 affects genes also on other chromosomes, which in cooperation with the observed chromosome 8 gene dosage effect, has an impact on the clinical features of constitutional trisomy 8 mosaicism (CT8M) that might explain the reason for increased incidence of hematologic malignancies in CT8M patients [13]. There is ample evidence that CT8M arises post-zygotically through a mitotic error, with no preferential parental origin of the gained chromosome 8 [14–18]. In humans, constitutional aneuploidy, for example, loss or gain of sex chromosomes or trisomy of chromosomes 13, 18 or 21, is a major cause of miscarriage and developmental disturbances. Gene expression patterns in patients with constitutional

trisomies have exclusively been compared with expression signatures derived from disomic control cells from unrelated healthy individuals [19–22].

The mosaic trisomies are especially informative for determination of the origin of the trisomy, as examination of the genotypes allows identification of the haplotype of the chromosome that is present in only a subset of cells. Meiotic origin of the trisomy is seen when the mosaic extra chromosome contains a genotype not present in the other two chromosomes. Mosaic aneuploidy originated mitotically in 16 cases as per earlier reports [23]. The constitutional trisomy is associated with abnormal phenotype due to imprinting effects, reduction to homozygosity at recessive disease loci, or trisomy mosaicism in few instances [24]. The vast majority of autosomal trisomies results from errors during maternal meiosis. Nondisjunction may occur either during meiosis or mitosis. Postzygotic mitotic errors accounts for some 5% of nonmosaic autosomal trisomies [25].

As far as it is possible, consanguineous marriage should be discouraged to prevent genetic disease. The possibility that a recessive condition, in addition to the trisomy 8 mosaicism, may contribute to the phenotype variability and severity in this patient, due to the consanguinity can not be ruled out. Hence, it is necessary to perform both karyotyping and FISH to detect low mosaic trisomy 8 in cases where clinical features correlate to those reported in the literature.

## References

- [1] Gorlin RJ, Cohen MM, Hennekam RC. Syndromes of the head and neck. 4th ed. New York: Oxford University Press; 2001.
- [2] Wolstenholme J. Confined placental mosaicism for trisomies 2, 3, 7, 8, 9, 16, and 22: their incidence, likely origins, and mechanisms for cell lineage compartmentalization. *Prenat Diagn* 1996;16(6):511–24.
- [3] Schinzel A. Catalogue of unbalanced chromosome aberrations in man. 2nd ed. Berlin, New York: De Gruyter; 2001.
- [4] Hale NE, Keane JF. Piecing together a picture of trisomy 8 mosaicism syndrome. *J Am Osteopath Assoc* 2010;110(1):21–3.
- [5] Shaffer LG, McGowan-Jordan J, Schmid M, editors. An international system for human cytogenetic nomenclature (ISCN). Basel, Switzerland Karger; 2013.
- [6] Leon E, Jamal SM, Zou YS, Milunsky JM. Partial trisomy 8 mosaicism due to a pseudoisodicentric chromosome 8. *Am J Med Genet A* 2011;155(7):1740–4.
- [7] Datta A, Picker J, Rotenberg A. Trisomy 8 mosaicism and favorable outcome after treatment of infantile spasms: case report. *J Child Neurol* 2010;25(10):1275–7.
- [8] Paulsson K, Johansson B. Trisomy 8 as the sole chromosomal aberration in acute myeloid leukemia and myelodysplastic syndromes. *Pathol Biol (Paris)* 2007;55(1):37–48.



- [9] Ripperger T, Tauscher M, Praulich I, Pabst B, Teigler-Schlegel A, Yeoh A, et al. Constitutional trisomy 8p11.21-q11.21 mosaicism: a germline alteration predisposing to myeloid leukaemia. *Br J Haematol* 2011;155(2):209–17.
- [10] Wiśniewska M, Mazurek M. Trisomy 8 mosaicism syndrome. *J Appl Genet* 2002;43(1):115–8.
- [11] Belengeanu V, Boia M, Farcas S, Popa C, Stoian M, Belengeanu A, et al. Trisomy 8 mosaicism with atypical phenotypic features. *Jurnalul Pediatruului* 2010;(13):36–9.
- [12] Houge G, Lybaek H, Gulati S. Mosaicism for combined tetrasomy of chromosomes 8 and 18 in a dysmorphic child: a result of failed tetraploidy correction? *BMC Med Genet* 2009;18(10):42.
- [13] Davidsson J, Veerla S, Johansson B. Constitutional trisomy 8 mosaicism as a model for epigenetic studies of aneuploidy. *Epigenetics Chromatin* 2013;6(1):18.
- [14] DeBrasi D, Genardi M, D'Agostino A, Calvieri F, Tozzi C, Varrone S, et al. Double autosomal/gonosomal mosaic aneuploidy: study of nondisjunction in two cases with trisomy of chromosome 8. *Hum Genet* 1995;95(5):519–25.
- [15] Robinson WP, Binkert F, Bernasconi F, Lorda-Sanchez I, Werder EA, Schinzel AA. Molecular studies of chromosomal mosaicism: relative frequency of chromosome gain or loss and possible role of cell selection. *Am J Hum Genet* 1995;56(2):444–51.
- [16] James RS, Jacobs PA. Molecular studies of the aetiology of trisomy 8 in spontaneous abortions and the liveborn population. *Hum Genet* 1996;97(3):283–6.
- [17] Seghezzi L, Maserati E, Minelli A, Dellavecchia C, Addis P, Locatelli F, et al. Constitutional trisomy 8 as first mutation in multistep carcinogenesis: clinical, cytogenetic, and molecular data on three cases. *Genes Chromosomes Cancer* 1996;17(2):94–101.
- [18] Karadima G, Bugge M, Nicolaidis P, Vassilopoulos D, Avramopoulos D, Grigoriadou M, et al. Origin of nondisjunction in trisomy 8 and trisomy 8 mosaicism. *Eur J Hum Genet* 1998; 6(5):432–8.
- [19] Biancotti JC, Narwani K, Buehler N, Mandefro B, Golan-Lev T, Yanuka O, et al. Human embryonic stem cells as models for aneuploid chromosomal syndromes. *Stem Cells* 2010;28(9):1530–40.
- [20] Altug-Teber O, Bonin M, Walter M, Mau-Holzmann UA, Dufke A, Stappert H, et al. Specific transcriptional changes in human fetuses with autosomal trisomies. *Cytogenet Genome Res* 2007;119(3–4):171–84.
- [21] Rozovski U, Jonish-Grossman A, Bar-Shira A, Ochshorn Y, Goldstein M, Yaron Y. Genome-wide expression analysis of cultured trophoblast with trisomy 21 karyotype. *Hum Reprod* 2007;22(9):2538–45.
- [22] Prandini P, Deutsch S, Lyle R, Gagnebin M, Delucinge Vivier C, Delorenzi M, et al. Natural gene-expression variation in Down syndrome modulates the outcome of gene-dosage imbalance. *Am J Hum Genet* 2007;81(2): 252–63.
- [23] Conlin LK, Thiel BD, Bonnemann CG, Medne L, Ernst LM, Zackai EH, et al. Mechanisms of mosaicism, chimerism and uniparental disomy identified by single nucleotide polymorphism array analysis. *Hum Mol Genet* 2010;19(7): 1263–75.
- [24] Karanjawala ZE, Kääriäinen H, Ghosh S, Tannenbaum J, Martin C, Ally D, et al. Complete maternal isodisomy of chromosome 8 in an individual with an early-onset ileal carcinoid tumor. *Am J Med Genet* 2000;93(3):207–10.
- [25] Bakshi SR, Brahmabhatt MM, Trivedi PJ, Dalal EN, Patel DM, Purani SS, et al. Trisomy 8 in leukemia: A GCRI experience. *Indian J Hum Genet* 2012;18(1):106–8.