

## Short Communication

# Progressive Supranuclear Palsy: Subcortical Tau Depositions Are Associated with Cortical Perfusion in Frontal and Limbic Regions

Hendrik Theis<sup>a,b</sup>, Michael T. Barbe<sup>b</sup>, Alexander Drzezga<sup>a,c,d</sup>, Gereon R. Fink<sup>b,e</sup>, Bernd Neumaier<sup>f,g</sup>, Gérard N. Bischof<sup>a,d,1</sup> and Thilo van Eimeren<sup>a,b,1,\*</sup>

<sup>a</sup>Department of Nuclear Medicine, University Hospital of Cologne, Cologne, Germany

<sup>b</sup>Department of Neurology, University Hospital of Cologne, Cologne, Germany

<sup>c</sup>German Center for Neurodegenerative Diseases (DZNE), Germany

<sup>d</sup>Institute for Neuroscience and Medicine (INM-2), Research Center Jülich, Jülich, Germany

<sup>e</sup>Institute for Neuroscience and Medicine (INM-3), Research Center Jülich, Jülich, Germany

<sup>f</sup>Institute of Radiochemistry and Experimental Molecular Imaging, University of Cologne, Germany

<sup>g</sup>Institute of Neuroscience & Medicine (INM-5), Nuclear Chemistry, Research Center Jülich, Jülich, Germany

Accepted 17 June 2024

**Abstract.** In progressive supranuclear palsy (PSP), subcortical tau and cortical perfusion can be assessed using the tracer [<sup>18</sup>F]PI-2620. We investigated if subcortical tau (globus pallidus internus, dentate nucleus) and frontal/limbic perfusion correlate in a cohort of 32 PSP patients. Tau in subcortical regions showed significant negative correlation with perfusion in limbic cortex. Perfusion in frontal regions was negatively associated with tau in both subcortical regions, but the significance threshold was only passed for the dentate nucleus. A reason could be a diaschisis-like phenomenon; that is, subcortical tau could lead to reduced connectivity to frontal regions and, thereby, to decreased perfusion.

**Keywords:** PSP, PET, imaging, tau, FDG, perfusion, progressive supranuclear palsy, diaschisis, [<sup>18</sup>F]PI-2620

## PLAIN LANGUAGE SUMMARY

In a study of 32 patients with progressive supranuclear palsy (PSP), we used a molecular imaging tracer called [<sup>18</sup>F]PI-2620 to measure two things: the presence of a protein called tau in deep brain areas

(specifically, the globus pallidus internus and dentate nucleus) and the function of the brain's cortex by assessing blood flow (perfusion). We found that higher amounts of tau in these deep brain areas were associated with reduced blood flow in the limbic cortex, which is involved in emotion regulation. Also, the frontal areas of the brain showed reduced blood flow related to tau in these deep brain regions. However, this connection was statistically significant only for the dentate nucleus. This study suggests that the buildup of tau protein in deeper brain areas can disrupt function in parts of the brain's cortex, highlighting the damaging role of tau in PSP.

<sup>1</sup>These authors contributed equally to this work.

\*Correspondence to: Thilo van Eimeren, MD, FEAN, University of Cologne, Faculty of Medicine and University Hospital Cologne, Department of Nuclear Medicine, Multimodal Neuroimaging Group, Kerpenerstr. 62, 50937 Cologne, Germany. E-mail: thilo.van-eimeren@uk-koeln.de.

## INTRODUCTION

Neuropathologically, progressive supranuclear palsy (PSP) is characterized by the aggregation of 4R-tau, primarily in subcortical areas of the brain, such as the globus pallidus internus (GPI) and the dentate nucleus.<sup>1</sup> The typical pattern of neuronal dysfunction in PSP can be identified by assessing glucose metabolism or perfusion through positron emission tomography (PET).<sup>2,3</sup> In contrast, the second-generation tau-PET tracer [<sup>18</sup>F]PI-2620 shows the typical pattern of tau deposition.<sup>4</sup> However, unlike in Alzheimer's disease,<sup>5</sup> tau and hypometabolism/perfusion patterns show limited spatial overlap in PSP. Tau depositions are characteristically found in subcortical regions, including the GPI and dentate nucleus,<sup>4</sup> while neuronal dysfunction dominates in cortical areas.<sup>2</sup> It needs to be clarified whether cortical perfusion is quantitatively associated with tau deposition in subcortical regions, as this link between tau pathology and neurodegeneration in PSP has yet to be examined. In order to investigate this quantitative relationship, key regions of subcortical tau and cortical perfusion were chosen based on our previous work with the tracer [<sup>18</sup>F]PI-2620.<sup>4,6</sup> To assess tau depositions, the non-displaceable binding potential (BP<sub>ND</sub>) was calculated, and for neuronal dysfunction, the early perfusion phase of this tracer was used. Since an [<sup>18</sup>F]FDG-PET was available in some patients, perfusion of [<sup>18</sup>F]PI-2620 and [<sup>18</sup>F]FDG metabolism were correlated in cortical regions to validate whether the perfusion modality adequately reflects neuronal dysfunction.

## METHODS

### *Participants*

Thirty-two patients diagnosed with probable or possible PSP according to established criteria received a dynamic tau PET (0-60 min) with [<sup>18</sup>F]PI-2620 at the Department of Nuclear Medicine of the University of Cologne.<sup>7</sup> Twenty-one patients also received an [<sup>18</sup>F]FDG-PET, which we used here to validate the perfusion modality. The clinical phenotype was evaluated according to established clinical criteria.<sup>7,8</sup> Furthermore, we implemented a [<sup>18</sup>F]PI-2620 reference sample of  $N = 10$  healthy controls. To rule out Alzheimer's disease pathology in our cohort according to the established clinical criteria, all

patients were tested for amyloid in CSF ( $A\beta_{42}/A\beta_{40}$  ratio) during their diagnostic work-up, while controls had an amyloid-PET with [<sup>18</sup>F]Florbetaben (negative on visual reads and Centiloids) for research purposes. All participants provided their informed consent in writing, and the study was conducted under the Declaration of Helsinki.

### *Preprocessing of imaging data*

SPM12 (<https://www.fil.ion.ucl.ac.uk/spm/software/spm12/>) was used for preprocessing. After movement correction, all frames were normalized to an established [<sup>18</sup>F]PI-2620 template.<sup>4</sup> Voxel-wise whole-brain non-displaceable binding potential (BP<sub>ND</sub>) maps were calculated by using the Simplified Reference Tissue Model 2 (SRTM2) in QModeling.<sup>4,9</sup> For the perfusion phase, we summed the realigned frames from 0.5–2.5 minutes p.i.<sup>2</sup> We spatially normalized this perfusion image and the [<sup>18</sup>F]FDG images to the SPM FDG PET template. Standardized uptake value ratio (SUVR) images of [<sup>18</sup>F]PI-2620 perfusion and [<sup>18</sup>F]FDG were calculated with the cerebellum, excluding the dentate nucleus as the reference region. All images were smoothed with an 8 mm<sup>3</sup> Gaussian kernel. We chose the GPI and the dentate nucleus as key regions of subcortical tau depositions<sup>4</sup> and extracted the mean BP<sub>ND</sub> of these two subcortical regions. For cortical perfusion and [<sup>18</sup>F]FDG metabolism, we extracted the mean bilateral SUVR in frontal and limbic areas according to the Brainnetome Atlas,<sup>10</sup> where PSP patients had significantly lower perfusion than controls.<sup>6</sup> A bilateral mask of all combined significant frontal regions with hypoperfusion (medial area 9 and medial area 10 of the superior frontal gyrus, dorsal area 44 of the inferior frontal gyrus and inferior frontal sulcus) and a bilateral mask of all combined significant limbic regions with hypoperfusion (pregenual area 32, subgenual area 32, caudodorsal area 24 of the cingulate gyrus) were created (Fig. 1A, B).<sup>10</sup> Mean BP<sub>ND</sub> values were additionally extracted in the cortical masks to correct the subsequent analyses for the influence of local tau in cortical regions. We wanted to measure whether subcortical tau, which is a significant PSP imaging biomarker,<sup>4</sup> is linked to cortical perfusion. Therefore, we wanted to rule out potential effects of local tau pathology in cortical regions.

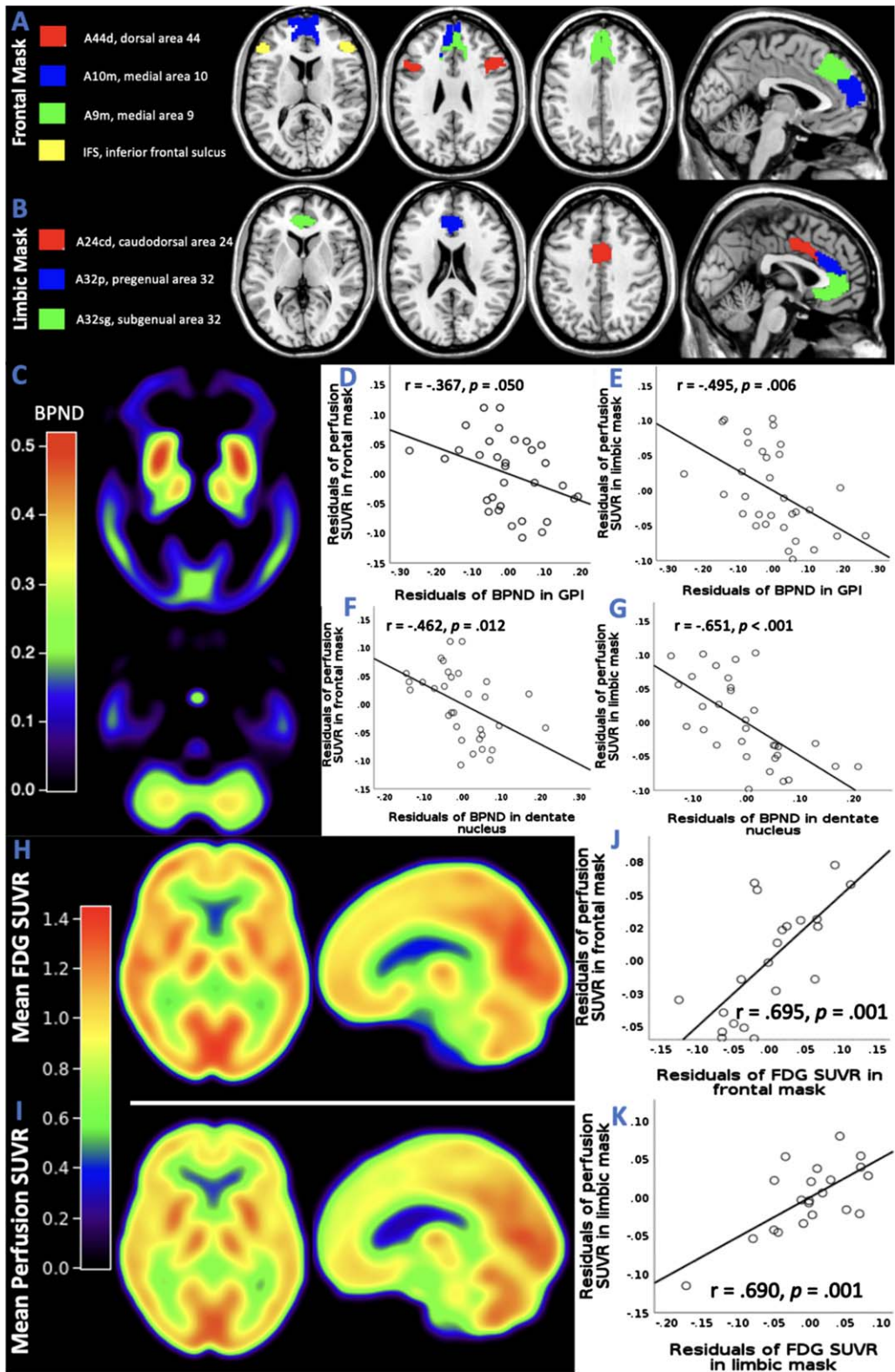


Fig. 1. (Continued)

Table 1

**Clinical and demographic data of the cohort.** For age, disease duration, and imaging data, mean and standard deviations were calculated. Two-sample *t*-tests were calculated to test for differences between PSP patients and controls. To test for differences in biological sex, the Chi-square test was applied

	PSP	HC	<i>p</i>
Number	32	10	n/a
Age	69 ± 7	59 ± 8	0.007
Sex (m:f)	17 : 15	6 : 4	0.703
Symptom duration (mo)	32.5 ± 18.7	n/a	n/a
BP <sub>ND</sub> GPI	0.30 ± 0.16	0.14 ± 0.10	0.008
BP <sub>ND</sub> Dentate	0.25 ± 0.13	0.18 ± 0.12	0.141
SUV <sub>R</sub> Frontal	0.81 ± 0.07	0.92 ± 0.05	<0.001
SUV <sub>R</sub> Limbic	0.86 ± 0.08	0.99 ± 0.05	<0.001

#### Statistical analyses: demographical and clinical data

We calculated the mean and standard deviations for age and duration of PSP symptoms. We applied two-sample *t*-tests and the Chi-square test, testing for age and sex differences between patients and controls (see Table 1).

#### Statistical analyses: imaging data

After checking for a normal distribution using the Kolmogorov-Smirnov test, we performed two-sample *t*-tests of the mean perfusion SUV<sub>R</sub> and the mean binding potential between PSP and the healthy controls in each region of interest.

In a second step, we performed a partial correlation between mean BP<sub>ND</sub> in the two subcortical regions, i.e., the GPI and dentate, and mean perfusion SUV<sub>R</sub> in the frontal and limbic mask, correcting for age, sex, and the amount of BP<sub>ND</sub> in the respective cortical mask. Bonferroni correction for multiple comparisons was applied to control the family-wise error rate to  $\alpha = 0.05/4 = 0.0125$ .

To validate whether early perfusion is equivalent to neurodegeneration as measured by [<sup>18</sup>F]FDG, we performed a partial correlation between perfusion SUV<sub>R</sub> and FDG SUV<sub>R</sub> in the frontal and limbic

masks, corrected for age and sex (family-wise error rate:  $\alpha = 0.05/2 = 0.025$ ).

## RESULTS

### Clinical data

Table 1 summarizes the demographic and clinical data. Patients were significantly older than the healthy control sample. PSP phenotypes were distributed as follows: 19 PSP with Richardson's syndrome, 1 PSP with progressive gait freezing, 4 PSP with predominant corticobasal syndrome, 1 PSP with predominant parkinsonism, 2 with predominant speech/language disorder, 2 with predominant frontal presentation. Three patients were not further classified.

### Imaging analysis

Upon visual inspection, the PSP cohort's mean BP<sub>ND</sub> maps showed a typical tau deposition pattern (Fig. 1C). Two-sample *t*-tests revealed that BP<sub>ND</sub> in GPI was higher in PSP patients than in controls. The higher BP<sub>ND</sub> in the dentate nucleus of PSP patients did not differ significantly from healthy controls. Perfusion SUV<sub>R</sub>s in frontal and limbic masks were lower in PSP patients than in healthy controls.

There were significant negative correlations between the mean BP<sub>ND</sub> in GPI and mean perfusion SUV<sub>R</sub> in the limbic mask ( $r = -0.495$ ,  $p = 0.006$ ) (Fig. 1E), as well as between BP<sub>ND</sub> in dentate and perfusion SUV<sub>R</sub> in frontal ( $r = -0.462$ ,  $p = 0.012$ ) (Fig. 1F) and limbic mask ( $r = -0.651$ ,  $p < 0.001$ ) (Fig. 1G). There was a borderline-significant correlation between BP<sub>ND</sub> in GPI and perfusion SUV<sub>R</sub> in the frontal mask ( $r = -0.367$ ,  $p = 0.050$ ) (Fig. 1D).

Mean perfusion and mean FDG SUV<sub>R</sub> maps are presented in Fig. 1H and 1I. There were strong and significant positive correlations between perfusion SUV<sub>R</sub> and FDG SUV<sub>R</sub> in frontal ( $r = 0.695$ ,  $p = 0.001$ ) and limbic mask ( $r = 0.690$ ,  $p = 0.001$ ) (Fig. 1J, K).

**Fig. 1. Link between subcortical tau and cortical dysfunction in PSP.** A frontal mask A) and a limbic mask B) were created by including regions of the Brainnetome atlas,<sup>10</sup> where patients with PSP had significant hypoperfusion in previous work.<sup>6</sup> C) Mean BP<sub>ND</sub> maps in the PSP cohort showing a typical pattern of tau depositions in subcortical regions. D-G) Partial correlation analyses between BP<sub>ND</sub> in GPI and dentate and perfusion SUV<sub>R</sub> in frontal and limbic mask corrected for age, sex and BP<sub>ND</sub> in respective cortical mask. For visualization, scatterplots of the residuals of BP<sub>ND</sub> and SUV<sub>R</sub> in the corresponding region were created. H) Mean perfusion SUV<sub>R</sub> map of [<sup>18</sup>F]PI-2620. I) Mean SUV<sub>R</sub> map of [<sup>18</sup>F]FDG. SUV<sub>R</sub> were calculated with the cerebellum excluding the dentate nucleus as reference region. J, K) Partial correlation analyses between perfusion SUV<sub>R</sub> and FDG SUV<sub>R</sub> in frontal and limbic mask corrected for age and sex. For visualization, scatterplots of the residuals of PDG and perfusion in the corresponding region were created.

## DISCUSSION

Here, we show that frontal and limbic cortical perfusion, is linked to the amount of subcortical tau as identified with Tau PET. Cerebral perfusion was strongly associated with [ $^{18}\text{F}$ ]FDG metabolism in this PSP cohort, similar to our previous work.<sup>2</sup> Since [ $^{18}\text{F}$ ]FDG is an established biomarker to assess neuronal dysfunction due to neurodegeneration, it is tempting to speculate that subcortical tau is linked to neuronal dysfunction in cortical regions.

We conclude that [ $^{18}\text{F}$ ]PI-2620 can provide quantifiable information on the underlying pathology (i.e., tau) and cortical dysfunction (i.e., perfusion). Unlike in AD, the patterns of neurodegeneration and tau deposition do not spatially overlap. A reason could be a diaschisis-like phenomenon; that is, subcortical tau could lead to reduced connectivity to frontal regions and, thereby, to decreased perfusion. It is important to note that while we observed a statistical relationship between the magnitude of subcortical tau and cortical dysfunction, this does not mean that these two biomarkers are interchangeable. Interestingly, the link between tau in the GPI and perfusion in the frontal region was only borderline-significant although the GPI directly projects to the regions of the frontal mask.<sup>10</sup> Therefore, more studies, specifically longitudinal ones with more subjects, are needed to examine the potential temporal sequence of subcortical tau pathology and cortical perfusion in PSP. In this regard, it might be interesting to examine whether the link of subcortical tau and cortical perfusion differs in clinical PSP phenotypes or whether hypoperfusion might be partially restored by dopamine replacement therapy.

## ACKNOWLEDGMENTS

We thank Life Molecular Imaging, Berlin, Germany, for providing the precursor for the production of [ $^{18}\text{F}$ ]PI-2620, and InviCRO, LLC, Boston, United States of America, for providing the [ $^{18}\text{F}$ ]PI-2620 reference sample.

## FUNDING

This work was partly funded by the Deutsche Forschungsgemeinschaft (DFG, German Research Foundation) Project-ID 431549029 – SFB 1451.

H.T. was supported by the Cologne Clinician Scientist Program (CCSP)/Faculty of

Medicine/University of Cologne. Funded by the Deutsche Forschungsgemeinschaft (DFG, German Research Foundation) (Project No. 413543196).

## CONFLICT OF INTEREST

A.D. reports the following competing interests: Research support: Siemens Healthineers, Life Molecular Imaging, GE Healthcare, AVID Radiopharmaceuticals, Sofie, Eisai, Novartis/AAA, Ariceum Therapeutics. Speaker Honorary/Advisory Boards: Siemens Healthineers, Sanofi, GE Healthcare, Biogen, Novo Nordisk, Invicro, Novartis/AAA, Bayer Vital. Stock: Siemens Healthineers, Lantheus Holding, Structured therapeutics, ImmunoGen

Patents: Patent for 18F-JK-PSMA- 7 (2-Alkoxy-6-[18F]Fluoronicotinoyl substituted Lys-C(O)-Glu derivatives as efficient probes for imaging of PSMA expressing tissues (Patent No.: EP3765097A1; Date of patent: Jan. 20, 2021)).

T.v.E. received or receives honoraria for consulting or in advisory roles from Lundbeck Foundation, Lundbeck Pharma, Orion Pharma, GT Gain Therapeutics SA, ICON PLC. Stock ownership: IBM, Microsoft, NVIDIA.

All other authors have no conflict of interest to report.

## DATA AVAILABILITY

Data will be made available upon reasonable request.

## REFERENCES

1. Roemer SF, Grinberg LT, Crary JF, et al. Rainwater Charitable Foundation criteria for the neuropathologic diagnosis of progressive supranuclear palsy. *Acta Neuropathol* 2022; 144:603–614.
2. Beyer L, Nitschmann A, Barthel H, et al. Early-phase [ $^{18}\text{F}$ ]PI-2620 tau-PET imaging as a surrogate marker of neuronal injury. *Eur J Nucl Med Mol Imaging* 2020; 47:2911–2922.
3. Beyer L, Meyer-Wilmes J, Schönecker S, et al. Clinical routine FDG-PET imaging of suspected progressive supranuclear palsy and corticobasal degeneration: a gatekeeper for subsequent tau-PET imaging? *Front Neurol* 2018; 9:483.
4. Brendel M, Barthel H, van Eimeren T, et al. Assessment of 18F-PI-2620 as a biomarker in progressive supranuclear palsy. *JAMA Neurol* 2020; 77:1408–1419.
5. Bischof GN, Jessen F, Fliessbach K, et al. Impact of tau and amyloid burden on glucose metabolism in Alzheimer's disease. *Ann Clin Transl Neurol* 2016; 3:934–939.
6. Katzdobler S, Nitschmann A, Barthel H, et al. Additive value of [ $^{18}\text{F}$ ]PI-2620 perfusion imaging in progressive

- supranuclear palsy and corticobasal syndrome. *Eur J Nucl Med Mol Imaging* 2023; 50:423–434.
7. Höglinger GU, Respondek G, Stamelou M, et al. Clinical diagnosis of progressive supranuclear palsy: The movement disorder society criteria. *Mov Disord* 2017; 32:853–864.
  8. Grimm M-J, Respondek G, Stamelou M, et al. How to apply the Movement Disorder Society Criteria for diagnosis of progressive supranuclear palsy. *Mov Disord* 2019; 34:1228–1232.
  9. López-González FJ, Paredes-Pacheco J, Thurnhofer-Hemsi K, et al. QModeling: a multiplatform, easy-to-use and open-source toolbox for PET kinetic analysis. *Neuroinformatics* 2019; 17:103–114.
  10. Fan L, Li H, Zhuo J, et al. The Human Brainnetome Atlas: A new brain atlas based on connectional architecture. *Cereb Cortex* 2016; 26:3508–3526.