

Supplementary Data

Executive Dysfunction in Mild Cognitive Impairment is Associated with Changes in Frontal and Cingulate White Matter Tracts

Ramune Grambaite^{a,b,*}, Per Selnes^{a,b}, Ivar Reinvang^c, Dag Aarsland^{b,d}, Erik Hessen^a,
Leif Gjerstad^e and Tormod Fladby^{a,b}

^a*Department of Neurology, Akershus University Hospital, Lørenskog, Norway*

^b*Faculty Division Akershus University Hospital, University of Oslo, Oslo, Norway*

^c*Center for the Study of Human Cognition, Department of Psychology, University of Oslo, Oslo, Norway*

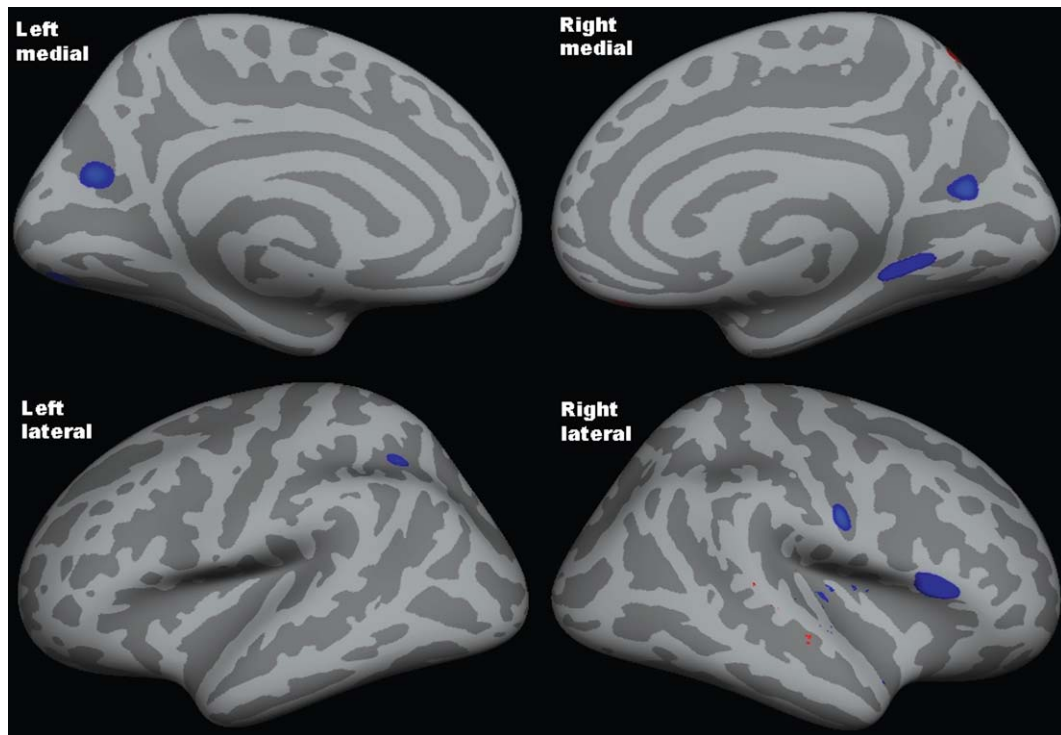
^d*Centre for Age-Related Medicine, Psychiatry Clinic, Stavanger University Hospital, Stavanger, Norway*

^e*Department of Neurology, Oslo University Hospital Rikshospitalet, Oslo, Norway*

Handling Associate Editor: Montse Alegret

Accepted 2 July 2011

*Correspondence to: Ramune Grambaite, Department of Neurology, Akershus University Hospital, Sykehusveien 25, NO-1478 Lørenskog, Norway. Tel.: +47 67968462; Fax: +47 67909130; E-mail: ramuneg@psykologi.uio.no.



Supplementary Figure 1. Statistical map showing the small areas where the cortex is thinner in a/e MCI than controls. The map is not corrected for multiple comparisons and the threshold is set at $p=0.01$.