

Erratum

Infiltration of CD4, CD8, CD56, and Fox-P3-positive lymphocytes in breast carcinoma tissue after neoadjuvant chemotherapy with or without trastuzumab

Naoko Itoi^a, Tomoko Umeda^{a,b,c,*}, Mitsuaki Ishida^d, Satoshi Murata^a, Tsuyoshi Mori^a, Yuki Kawai^a, Kaori Tomida^a, Tomoharu Shimizu^a, Ryoji Kushima^e and Masaji Tani^a

^aDepartment of Surgery, Shiga University of Medical Science, Tsukinowa-cho, Seta, Otsu, Shiga, Japan

^bConsortium for Community Medicine, Shiga University of Medical Science, Tsukinowa-cho, Seta, Otsu, Shiga, Japan

^cDepartment of Breast surgery, Japan Community Healthcare Organization (JCHO) Shiga Hospital, Fujimidai, Shiga, Japan

^dDepartment of Pathology and Laboratory Medicine, Kansai Medical University, Shin-machi, Hirakata, Osaka, Japan

^eDepartment of Clinical Laboratory Medicine and Division of Diagnostic Pathology, Shiga University of Medical Science, Tsukinowa-cho, Seta, Otsu, Shiga, Japan

[Breast Disease, 38(2) 2019, 57–65,
DOI 10.3233/BD-180350]
<https://content.iospress.com/articles/breast-disease/bd180350>

On page 61, Table 2, in the Tz⁺ group, the average number of immunoreactive CD8 cells in the intratumoral (I) compartment, previously reported as 17.3, has now been revised as 1.73.

On page 62, in Table 2 (continued), within the CD8/Fox-P3 column, the absence of Fox-P3-positive cells, previously reported as “0”, has now been revised as “–”. In addition, in the Tz⁺ group, in case 6, the number of CD8/Fox-P3-positive cells in the adjacent (A) and distal (D) stromal compartments, previously

reported as 1.2 and 6.8, respectively, has now been revised as 6.8 and 1.1, respectively. In the Tz[–] group, in case 13, the number of CD8/Fox-P3-positive cells in the D compartment, previously reported as 1, has now been revised as 6.6. In the Tz⁺ group, the average CD8/Fox-P3-positive cells in the I, A, and D compartments, previously reported as 0.3, 6.2, and 5.3, respectively, has been revised as 3, 11, and 10.6, respectively. In the Tz[–] group, the average CD8/Fox-P3-positive cells in the A and D compartment, previously reported as 4 and 1.3, respectively, has now been revised as 30.5 and 12.6, respectively.

On page 63, CD4 and CD8 in graph [b] and Fox-P3 and in graph [b and c] of Figure 2 have been revised. Furthermore, the statistical test mentioned at the lower right end of Figure 2, previously reported as Welch's t-test, has now been revised as Mann–Whitney U test.

The revised Table 2 (Tz⁺ and Tz[–] group, CD8 and CD8/Fox-P3) is shown below:

*Corresponding author: Tomoko Umeda, MD, PhD, Consortium for Community Medicine, Shiga University of Medical Science, Tsukinowa-cho, Seta, Otsu, Shiga, 520-2192, Japan. Tel.: +81 548 2238; Fax: +81 548 2240; E-mail: tomoko@belle.shiga-med.ac.jp.

Table 2
Expression of CD8 and CD8/Fox-P3-positive cells in each compartment

Tz ⁺ group Case	CD8			CD8/Fox-P3		
	I	A	D	I	A	D
1	3.4	39.2	63.6	–	–	–
2	0.6	86.4	23.2	–	–	–
3	2.8	24.6	18	–	–	–
4	1.2	1.8	10.8	–	–	–
5	0.4	1.4	20.8	–	–	–
6	0.2	64	9.4	–	6.8	1.1
7	0.2	3	0.6	1	0.4	–
8	2.2	39.8	12	5.5	1	0.8
9	0	37	10.2	–	–	–
10	2	53.8	15.2	2.5	13.5	12.7
11	2	106	21.8	–	15.1	36.3
12	7.2	230.6	5	–	21	3.1
13	1.2	19.8	13.8	–	4	11.5
14	0	19.8	1.8	–	7.1	9
15	2.6	53.6	11	–	29.8	–
Average	<u>1.73</u>	52	15.8	<u>3</u>	<u>11</u>	<u>10.6</u>
Tz [–] group Case	CD8			CD8/Fox-P3		
	I	A	D	I	A	D
1	1.4	34	9.8	–	–	–
2	0.2	3.6	12.2	–	–	–
3	0.2	15.2	16.4	–	–	–
4	0.6	13.2	2.6	–	–	–
5	2.6	12.4	10.4	–	–	–
6	0.2	0.8	2.4	–	–	–
7	0.4	7.6	0.4	–	–	–
8	0.4	9.2	0.4	–	46	–
9	0	6.6	7.4	–	–	18.5
10	1.2	20.2	11.4	–	–	–
11	1.2	10.2	8.2	–	–	–
12	0	0.2	0.2	–	–	–
13	0.6	3	10.6	–	15	6.6
14	1.2	18.6	11.8	–	–	–
Average	0.7	11.1	7.4	–	<u>30.5</u>	<u>12.6</u>

A, adjacent stromal compartment; D, distal stromal compartment; I, intratumoral compartment; Tz, Trastuzumab; –, Fox-P3-positive cells were not found.

The revised Fig. 2 is shown below:

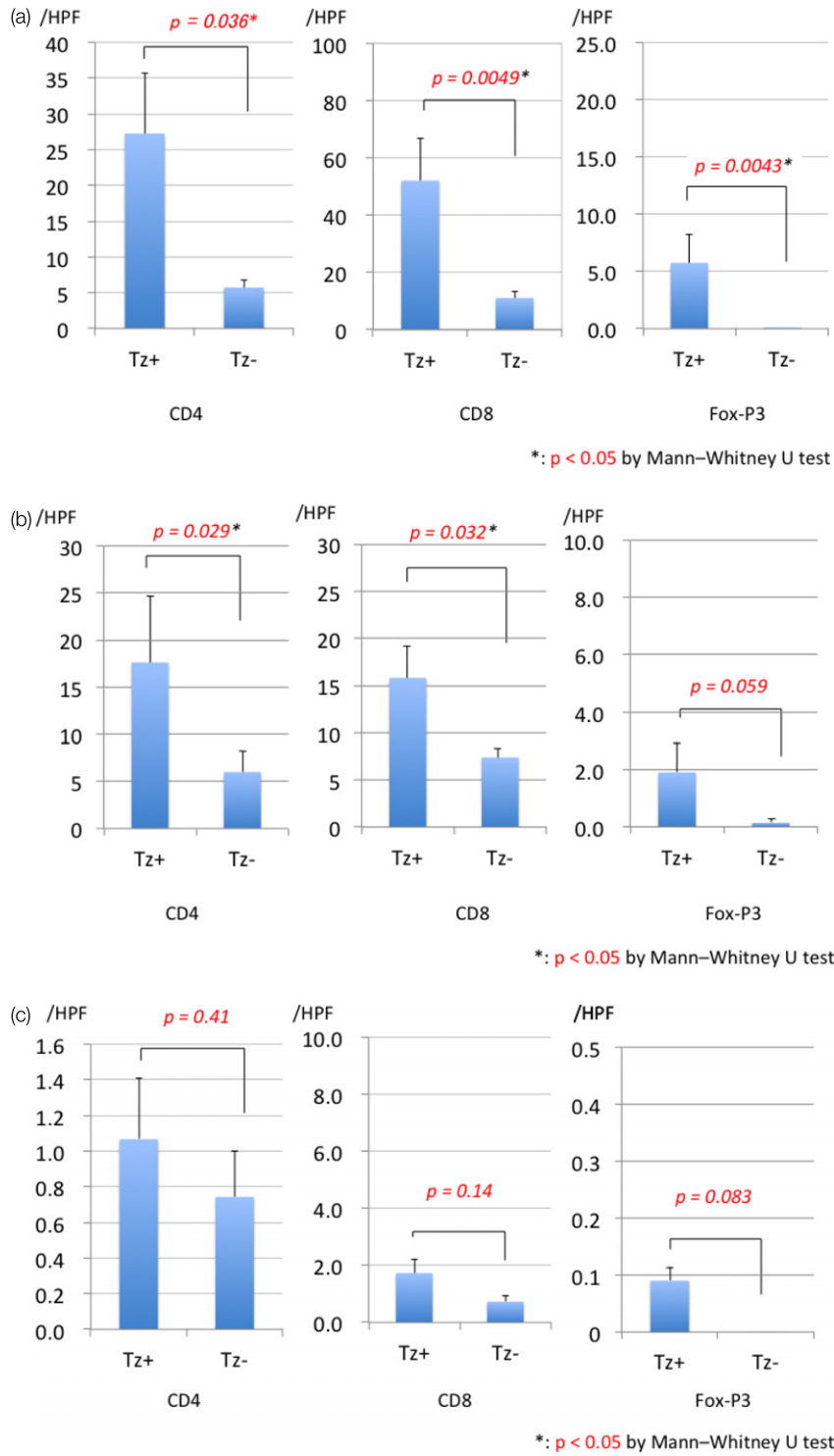


Fig. 2. Number of CD4-, CD8-, and Fox-P3-positive cells in the three different tissue compartments, (a) adjacent lesion, (b) distant lesion, and (c) intratumor lesion, with or without trastuzumab therapy.