

## Research Report

# Brain Volumetric Correlates of Memory in Early Parkinson's Disease

Ulla Ellfolk<sup>a,b,\*</sup>, Juho Joutsa<sup>b,c</sup>, Juha O. Rinne<sup>b,c</sup>, Riitta Parkkola<sup>d,e</sup>, Pekka Jokinen<sup>b,c</sup> and Mira Karrasch<sup>a</sup>

<sup>a</sup>Department of Psychology and Logopedics, Abo Akademi University, Turku, Finland

<sup>b</sup>Division of Clinical Neurosciences, Turku University Hospital and University of Turku, Turku, Finland

<sup>c</sup>Turku PET Centre, Turku University Hospital and University of Turku, Turku, Finland

<sup>d</sup>Department of Radiology, Turku University Hospital and University of Turku, Turku, Finland

<sup>e</sup>Department of Radiology, Tampere University Hospital and University of Tampere, Tampere, Finland

### Abstract.

**Background:** Free recall memory deficits are common in Parkinson's disease (PD), even at early stages before mild cognitive impairment or dementia. Their association with brain structural changes has not been established.

**Objective:** We studied local gray matter volumes in relation to different memory tasks in early stage PD.

**Methods:** Magnetic resonance images (MRI) and neuropsychological data were obtained from 28 non-demented, medicated PD patients, and 28 healthy controls. The gray matter segments of T1-weighted MRI images were analyzed using voxel-based morphometry in relation to visual and verbal memory tasks. Measures of immediate free recall, verbal learning, delayed recall and memory consolidation were obtained. A novel measure of incidental memory was included.

**Results:** Patients and controls showed no significant group differences in local gray matter volumes. Voxel-based morphometry analyses revealed that worse performance on an incidental visual memory task was associated with smaller right parietal gray matter volume (Family-wise error corrected  $P = 0.002$ ). This association was present in the PD group (corrected  $P = 0.005$ ), but not in controls (corrected  $P > 0.99$ ). No associations between gray matter volumes and the other memory tasks were found in either group.

**Conclusions:** The results suggest that right parietal cortical gray matter volume is related to free recall memory deficits in early stage PD in conditions not involving an intention to memorize visual items. This preliminary finding needs to be established in further studies utilizing incidental memory tasks in PD.

Keywords: Parkinson's disease, MRI, cognition, memory, parietal lobe, neuropsychology, voxel-based morphometry, incidental memory

## INTRODUCTION

Cognitive impairment and dementia are common in Parkinson's disease (PD). Structural brain imaging studies have demonstrated that Parkinson's disease

dementia (PDD) is associated with changes in limbic areas and widespread cortical atrophy in temporal, prefrontal, occipital and parietal areas [1–3]. Findings in non-demented patients are mixed, but patterns of temporal, parietal and occipital cortical involvement have been related to mild cognitive impairment (PD-MCI) [4, 5]. In relation to specific cognitive tasks, the most consistent finding in both demented and non-demented PD patients is hippocampal atrophy, which is related to memory functions [1, 6–8]. Recent evidence

\*Correspondence to: Ulla Ellfolk, Department of Psychology and Logopedics, Abo Akademi University, FIN-20500 Turku, Finland. Tel.: +358 2 2154409; Fax: +358 2 2154534; E-mail: ulla.ellfolk@abo.fi.

suggests that in non-demented PD patients, worse memory performance is associated with volume loss in several temporal lobe structures, including the entorhinal cortex [9].

Only a few studies have addressed brain gray matter volume in relation to specific cognitive tasks in early stages of PD (disease duration less than three years). Voxel-based morphometry (VBM) studies with untreated patients have mainly yielded no significant regional gray matter atrophy or correlations with cognitive tasks [10, 11]. A lack of structural-behavioral correlations has been suggested to result from the use of collapsed behavioral scores, instead of targeting tests in single cognitive domains [12], such as memory. While severe temporal lobe-dependent memory consolidation problems are rarely reported in early stage PD [13], impairments in immediate and delayed free recall are common [14, 15]. In early stages, free recall has been reported to be more strongly affected than language, performance on simple attention tasks, and visuospatial functioning [14]. One study [16] using radial distance mapping found significant associations between hippocampal volume and both short and long delay free recall at initial stages of PD. Another recent study [5] using a surface-based approach reported right posterior cortical thinning in relation to a verbal immediate free recall task in PD-MCI patients, but no associations with free recall tasks in cognitively intact patients. In PDD patients, cortical thinning in right parahippocampal gyrus, bilateral anteromedial temporal cortex, and left lingual gyrus was related to a delayed recall task. As very few studies have reported structural correlates of specific free recall memory tasks in early PD, and few have included both verbal and visual memory tasks, it remains to be elucidated whether visual and verbal memory are differently reflected in cortical volume in PD.

Our aim was to study gray matter volume in relation to visual and verbal memory tasks in early stage PD (disease duration <3 years) using VBM. As very recent recommendations on memory assessment [17] state that episodic memory should also be assessed by non-intentional tasks, we examined four conventional memory tasks and one non-intentional, incidental memory task. The examined tasks provided measures of immediate free recall (two tasks), verbal learning, delayed verbal recall, and relative verbal savings percentage (memory consolidation). To our best knowledge, no studies have addressed regional brain gray matter volume in relation to free recall after incidental encoding in PD. We expected that memory performances would be related to temporal gray matter.

## MATERIALS AND METHODS

### *Participants and clinical assessment*

56 participants (28 PD and 28 healthy controls) were enrolled through a national survey research project on PD cognition in collaboration with the Finnish Parkinson Association, and from two outpatient neurology clinics. Newly diagnosed patients (disease duration maximum three years) were asked to participate. All participants had a brain magnetic resonance imaging (MRI) scan and were neurologically evaluated by experienced clinical investigators at the Turku PET Centre (JJ and PJ). The MRI scans were visually rated by an experienced neuroradiologist (RP). Extensive neuropsychological assessments and clinical interviews were performed by an experienced neuropsychologist (UE) at the Department of Psychology and Logopedics at Abo Akademi University. The work was carried out in accordance with the Declaration of Helsinki. Written informed consent was obtained from all participants. The study protocol was approved by the Joint Ethics Committee of Turku University and Turku University Hospital.

28 PD patients and 28 healthy controls underwent MRI imaging and neuropsychological testing within a four-week interval. All patients had a diagnosis of idiopathic PD made by their treating neurologist according to the UK Brain Bank criteria, and none had structural brain findings inconsistent with the PD diagnosis. Motor impairment was rated using the validated Finnish version of the Unified PD Rating Scale (UPDRS-Fin III) ([http://www.parkinson.fi/sites/default/files/UPDRS-FIN%20\\_III.pdf](http://www.parkinson.fi/sites/default/files/UPDRS-FIN%20_III.pdf)). All patients were stable on their antiparkinsonian medications. The total medication dose was calculated in levodopa equivalents (LEDD) [18]. None of the patients were taking anticholinergic preparations. The possible presence of PDD was assessed according to Movement Disorder Society Task Force recommendations [19]. Based on clinical impression, a semi-structured interview and formal neuropsychological assessment, none of the patients were clinically demented and none of them had cognitive deficits significantly impairing daily life. All patients were community dwelling and functionally independent including independent usage of medications. Neuropsychological assessments were performed in the 'on' state. The group of healthy controls consisted of 15 men and 13 women. None of them were clinically diagnosed with depression, neurological or psychiatric disease, or had a history of head trauma. Patients and controls were equated for age and

Table 1  
Demographic, clinical, and MRI visual rating score comparisons between PD patients and controls

	PD (n = 28)	Controls (n = 28)	P-value
<i>Demographic and clinical<sup>a</sup></i>			
Age	60.3 (8.1)	61.3 (7.2)	NS
Gender (Male/Female) <sup>b</sup>	14/14	15/13	NS
Education (years)	13.8 (3.5)	14.8 (3.2)	NS
MMSE score	28.0 (2.0)	28.1 (1.9)	NS
Disease duration (months)	18.9 (10.8)	NA	
Age at disease onset	58.8 (7.8)	NA	
UPDRS-III motor score	25.9 (7.5)	NA	
H & Y stage, median (min-max)	2.5 (2-3)	NA	
Levodopa equivalent dose (mg/day)	392.0 (230.3)	NA	
Total intracranial volume (TIV) (ml) <sup>c</sup>	1515.1 (155.8)	1482.3 (160.8)	NS
<i>MRI visual rating score<sup>d,e</sup></i>			
Age-related white matter changes	0.5 (0.6)	0.4 (0.6)	NS
<i>Score/number of cases</i>	0/16, 1/10, 2/2	0/19, 1/7, 2/2	
Hippocampal atrophy (right)	0.07 (0.3)	0.07 (0.3)	NS
<i>Score/number of cases</i>	0/26, 1/2	0/26, 1/2	
Hippocampal atrophy (left)	0.04 (0.2)	0.07 (0.3)	NS
<i>Score/number of cases</i>	0/27, 1/1	0/26, 1/2	
Frontal atrophy	0.07 (0.4)	0.04 (0.2)	NS
<i>Score/number of cases</i>	0/27, 2/1	0/27, 1/1	

<sup>a</sup>Independent samples *t* test; <sup>b</sup>Pearson Chi square test; <sup>c</sup>TIVs obtained from native space images, control *n* = 27; <sup>d</sup>Age-related white matter changes (Wahlund et al., 2001), hippocampal atrophy (Scheltens et al., 1992), and frontal atrophy (Jokinen et al., 2009) were visually evaluated on scales ranging from 0 – 4; <sup>e</sup>Mann Whitney U test.

years of education on group level. Details are presented in Table 1.

### Memory tasks

Immediate free recall was assessed using two visual-verbal memory tests. Free recall after intentional encoding was assessed using the 20 Objects test [20]. 20 common physical objects (pencil, scissors, match-box etc.) exposed in a 34 × 25 cm size box were first named and immediately thereafter recalled. Prior to naming, the participants were instructed to memorize as many items as possible. Free recall after incidental encoding was assessed using a novel memory extension of the Boston Naming test (BNT), the Memo-BNT [21, 22]. The participant was asked to name items (drawings) 30–60 from the original BNT. Naming was followed by immediate free recall of the previously named items. An incidental encoding context was created by not giving participants any instructions to memorize during the naming task, and by introducing the task as the very first in the testing situation. Additionally, immediate and delayed verbal free recall was assessed using the wordlist learning (sum score of three trials), wordlist delayed recall and wordlist relative saving percentage (savings%) of the CERAD [23, 24]. Savings% expresses the percentage of words learned by the third trial that are retained at delayed recall. As executive [25] and working mem-

ory deficits [26, 27] are commonly reported in PD and may have some impact on memory performance, an executive cost sum score and a working memory sum score were created. The executive cost sum score was calculated by adding together the difference scores of the Trail Making test and the Stroop test, (TMT B – A) + (Stroop interference naming – color naming). Higher score indicates worse set-shifting and/or inhibition abilities. The working memory sum score consisted of the verbal and visual backward spans (sum of absolute spans, entities) of the Wechsler Memory Scale-III. Group differences on the neuropsychological measures were assessed using univariate ANOVAs and Mann-Whitney U tests. Correction for multiple comparisons was performed resulting in a significance level of  $.05/7 = .007$ . Non-parametric correlational analyses were conducted to examine possible relationships between the memory measures and the executive as well as working memory control measures. Parametric correlations were used for examining relationships between memory measures, UPDRS-III and LEDD in PD group. All behavioral analyses were performed in SPSS 21.

### MRI acquisition

The subjects were scanned using a 1.5 T scanner (Philips Gyroscan Intera 1.5T CV Novo Dual, Philips Healthcare, Best, The Netherlands) equipped with a

SENSE head coil. For VBM analyses, T1-weighted three-dimensional fast field echo images were obtained in transverse planes with contiguous  $1 \times 1 \times 1$  mm voxels, 25 ms echo time, 30 degrees flip angle, and field-of-view  $256 \times 256$  mm yielding at least 160 contiguous slices. In addition, T2-weighted, diffusion and FLAIR sequences were obtained for visual evaluation.

#### Visual MRI ratings

Age-related white matter changes were visually rated using the Wahlund scale (0–4) [28]. Hippocampal atrophy (left and right) was rated according to the Scheltens scale (0–4) [29] and frontal atrophy using a scale ranging from 0–4 [7]. Based on visual evaluation of the MRI images, one control subject was diagnosed with asymptomatic meningioma, and was thus excluded from the VBM analyses.

#### VBM

VBM was conducted using the VBM8 toolbox (Christian Gaser, University of Jena; <http://dbm.neuro.uni-jena.de/vbm8/>) in SPM8 (Wellcome Department of Cognitive Neurology, London, UK) running in Matlab R2011a (MathWorks, Natick, MA). The T1-weighted images were segmented into gray matter, white matter, and cerebrospinal fluid images [30]. The total intracranial volumes (TIVs) were obtained from the native-space images. The images were normalized to Montreal National Institute (MNI) space using the high-dimensional DARTEL normalization procedure [31]. The images were modulated using the Jacobian determinants derived from the normalization procedure [32]. A 10 mm full width half maximum (FWHM) Gaussian kernel was used to smooth the images to improve signal-to-noise ratio.

The images were analyzed with SPM8 using the general linear model (GLM). For statistical analyses, the images were thresholded with voxel value 0.1 to include voxels consisting of only gray matter. An analysis mask was constructed using SPM8 toolbox WFU PickAtlas of the human brain (<http://fmri.wfubmc.edu/software/PickAtlas>) [33] to include the whole brain except for the medulla and cerebellum. The analyses were performed in the whole sample ( $n=55$ ) and dividing the groups separately ( $n=28$  for PD patients and  $n=27$  for controls). The potential confounding factors (gender, age, handedness, education and TIV in the whole sample; and UPDRS score in PD patients) were analyzed using single variable regression. The factors associated with

local gray matter volumes were added as nuisance covariates to subsequent multiple regression analyses. Of the tested demographic variables; sex, age, and TIV were associated with local gray matter volumes. However, there was a strong intercorrelation between sex and TIV. Therefore, only age and TIV were included as nuisance covariates to the voxel-wise multiple regression analyses. The variables of interest (intentional free recall, incidental free recall, wordlist learning, wordlist delayed recall and wordlist savings%) were analyzed using multiple regression analysis. The analyses were performed at height threshold of uncorrected  $P < 0.005$ . Family-wise error corrected (FWE) cluster-level  $P_{\text{fwe}} < 0.05$  was considered statistically significant. The peak coordinates are presented in MNI standard space.

## RESULTS

#### Demographic and clinical background measures

The groups did not differ regarding age, gender, education, MMSE scores or TIV. There were no significant group differences on the visual rating scores for white matter changes, hippocampal, or frontal atrophy scores. Visual scores ranged between 0 and 2 in both groups. Demographic, clinical, and MRI visual rating data are presented in Table 1.

#### Memory measures

The PD patients were significantly impaired on intentional free recall, incidental free recall, and wordlist learning. No significant group differences were found in wordlist delayed recall and wordlist savings%. The significance pattern did not change when the analyses were repeated controlling for age and education (ANCOVA). There were no significant group differences in executive or working memory performances. Neuropsychological between-group comparisons are presented in Table 2. Within the PD group, wordlist delayed recall was significantly related to executive ( $r_s = -.39$ ;  $p = .039$ ) and working memory ( $r_s = .50$ ;  $p = .007$ ) performance. Wordlist savings% was also related to working memory ( $r_s = .46$ ;  $p = .013$ ) in the PD group. In controls, only wordlist learning was significantly related to the executive measure ( $r_s = -.51$ ;  $p = .005$ ). The intentional and incidental free recall tasks were not related to executive or working memory performance in either of the two groups. None of the memory tasks were related to UPDRS-III score or LEDD in the PD group.

Table 2  
Neuropsychological comparisons between PD patients and controls

	PD ( <i>n</i> = 28)	Controls ( <i>n</i> = 28)	<i>P</i> -value	Cohen's <i>d</i>
<i>Memory tasks<sup>a</sup></i>				
Incidental free recall <sup>b</sup>	8.3 (3.1)	10.6 (2.9)	.005	-.77
Intentional free recall <sup>c</sup>	12.5 (2.5)	14.4 (1.6)	.001	-.91
Wordlist learning <sup>d</sup>	20.4 (3.3)	22.9 (3.1)	.005	-.78
Wordlist delayed recall	6.2 (2.2)	7.1 (1.9)	.097	-.44
Wordlist savings% <sup>e</sup>	79.4 (23.4)	81.4 (19.2)	.733	-.09
<i>Executive control tasks<sup>f</sup></i>				
Executive cost sum score <sup>g</sup>	97.9 (46.9)	84.8 (28.7)	.566	.34
Working memory sum score <sup>h</sup>	10.1 (1.8)	10.2 (1.4)	.558	-.06
<i>Visuospatial control tasks<sup>i</sup></i>				
Cerad Figure copy total score	9.9 (1.3)	10.8 (0.6)	.002	-.87
WAIS-III Block design total score	34.2 (9.8)	43.1 (10.4)	.002	-.88

<sup>a</sup>Univariate ANOVA; <sup>b</sup>Memo-BNT immediate free recall; <sup>c</sup>20 Objects test immediate free recall; <sup>d</sup>Sum of three trials; <sup>e</sup>[(delayed recall score/third trial score) × 100]; <sup>f</sup>Mann-Whitney U test; <sup>g</sup>Sum of executive costs in seconds (set-shifting: Trail Making test B – A + inhibition: Stroop interference naming – color naming). Higher values indicate worse performance; <sup>h</sup>Sum of verbal and visual backward spans (number of entities) of the Wechsler Memory Scale-III; <sup>i</sup>Post-hoc analysis.

#### VBM group analysis and correlations with memory performances

There was no statistically significant difference between the groups in local gray matter volumes (the largest non-significant cluster with reduced gray matter volume in PD patients was observed in right parietal cortex;  $k = 1253$ ,  $P_{fwe} = 0.33$ ,  $xyz = 57 - 55 27$ ). In the whole study group, lower score on the incidental memory task was associated with smaller local gray matter volume in right parietal cortex [ $k = 4972$ ,  $P_{fwe} = 0.002$ ,  $xyz = 52 - 22 46$  (Fig. 1A)]. When separating the groups, lower incidental memory scores were associated with smaller right parietal gray matter volume in PD patients [ $k = 3718$ ,  $P_{fwe} = 0.005$ ,  $48 - 25 40$  (Fig. 1B)], but not in control subjects [ $P_{fwe} > 0.99$ ]. The main associated coordinate regions were right post-central gyrus and inferior parietal lobule, including Brodmann areas 2 and 40. There were no associations between local gray matter volumes and any of the other memory variables in the whole sample or in the groups separately.

Due to the association between right parietal volume reduction and the incidental memory task in the PD group, post-hoc analyses (ANOVA) were conducted for the two visual memory tasks in order to clarify their possible association with visuospatial functioning. Although the PD patients performed significantly worse than controls on both a simple figure copying task (CERAD) and the complex block design task of WAIS-III (Table 2), a partial correlation analysis accounting for age and education did not yield significant associations between visuospatial performance and performance on the two visual memory tasks. This

suggests that the correlation between right parietal volume reduction and incidental memory performance in the PD group was most likely not due to or modulated by visuospatial processing deficits.

#### DISCUSSION

We studied brain gray matter volume using VBM in relation to different aspects of visual and verbal memory in early stage, medicated, non-demented PD. Four conventional memory tasks and one novel incidental memory task were used. Measures of immediate free recall, verbal learning, delayed verbal recall, and relative verbal savings percentage were examined. Very few PD studies have examined volumetric relationships with single memory measures or memory tasks including both verbal and visual content. There are no previous reports on gray matter correlates of incidental memory in PD.

Our main finding was a significant relationship between right parietal gray matter volume reduction and worse performance on an incidental memory task. The relationship was significant over the collapsed group. This effect was also seen in the PD group alone, but not in control subjects, indicating the finding to be related to PD pathology. There were no significant relationships between gray matter volume and any of the other memory tasks in either of the groups, or over the collapsed sample. On the behavioral level, PD patients performed worse than controls on the visual immediate free recall tasks (one intentional and one incidental) and on the wordlist learning task. They were not impaired on delayed wordlist recall or

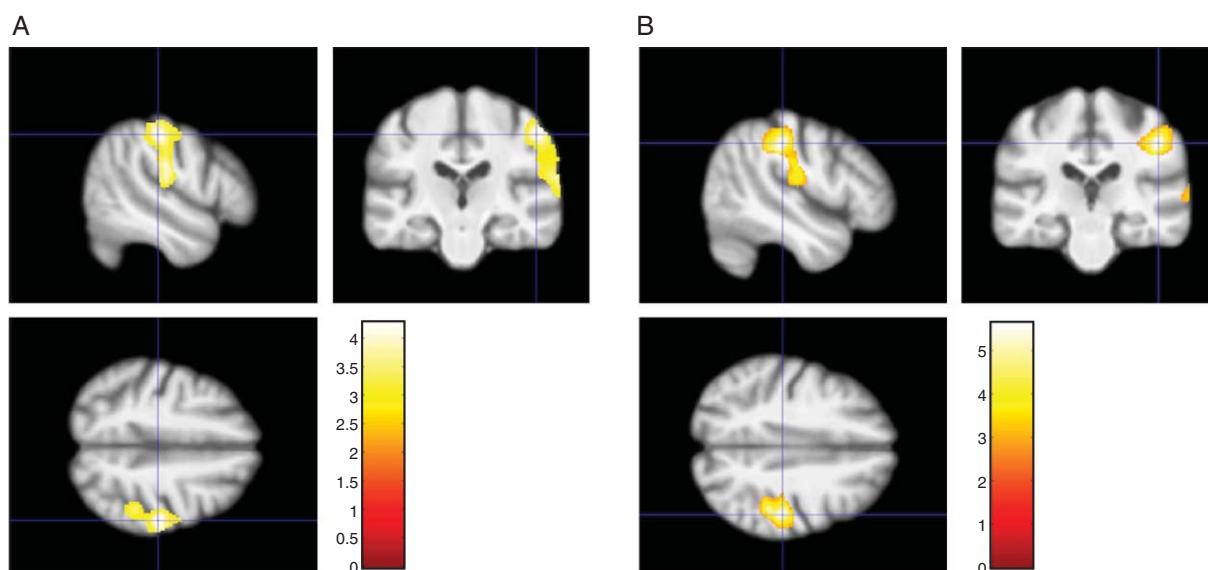


Fig. 1. Association between parietal gray matter volume and incidental memory (A) in the whole study group ( $n=55$ ,  $P_{fwe}=0.002$ ) and (B) in PD patients ( $n=28$ ,  $P_{fwe}=0.005$ ) overlaid on the average normalized T1-weighted image of the study subjects. The color bar represents T-values.

relative wordlist savings%. Wordlist learning, wordlist delayed recall and savings% were related to executive and working memory functioning predominantly in the PD group, while none of the visual free recall memory tasks were related to executive functioning or working memory in either of the groups.

Our results are in line with previous VBM studies in PD, which have demonstrated significant regional gray matter atrophy in more advanced patients with cognitive impairment, but not in patients at early stages. We found no significant regional gray matter volume differences, although trend-level parietal regional gray matter volume reduction was present in PD patients. In the earliest disease stages and in cognitively intact patients, several studies have found either no global or regional gray matter volume loss [1, 11, 34] or they reported scant changes [35, 36]. In relation to memory tasks, VBM findings have been absent in untreated patients [10, 11] and restricted to the hippocampus when reported in cognitively intact PD patients [1]. The PD patients in the present study were not impaired on delayed memory measures or memory consolidation, which is consistent with findings drug-naïve patients [13] and the fact that we did not find significant medial temporal lobe changes. Structures within the medial temporal lobe are essential for declarative, intentional memory [37]. The absence of volumetric changes and the intact memory consolidation performances in the present sample of PD patients is consistent with the

fact that they were at early stage of the disease with no significant cognitive impairment.

The observed association between right parietal gray matter volume reduction and worse performance on the incidental memory task only, was unexpected and warrants discussion. The most prominent difference between the incidental task and the other memory tasks in the present study was the absence of an explicit instruction to memorize items. Thus, no external cues to focus attention on the visual items were available during encoding, in opposite to the other tasks in which explicit instructions to memorize as much as possible were given. The incidental task was also more difficult than the other tasks, in the sense that it contained somewhat more items (31) than the other, highly similar visual free recall task (20 items), and the verbal learning task (10 items). It is important to note, that most previous structural imaging studies in PD have used verbal memory tasks such as the California Verbal Learning test or Rey Auditory Verbal Learning test. In these tasks, an explicit instruction to memorize is given, which automatically creates an intentional condition. Explicit instructions may, however, cause episodic information to be acquired and retained by semantic memory systems, instead of engaging episodic memory [17].

The lateralization of our main finding to right parietal regions was unexpected. Interestingly, right hemisphere cortical thinning in parietal regions has

previously been found in cognitively intact [5] and non-demented PD patients [36]. In PD patients with longer disease durations, gray matter reductions in bilateral parietal areas (BA 40) have been found to correspond with performance on visual form discrimination [38]. Lesion studies and functional imaging studies in healthy humans have shown that the right hemisphere is dominant for aspects of attention [39], and that the right parietal cortex is related to interactions between different attentional processes [40]. Parietal regions are believed to track the intention to remember by directing attention to memory contents [39], as well as maintaining qualitative content, such as mental images [41]. Activation studies have shown that the parietal lobe is one of the most frequently activated areas also during episodic memory retrieval [42], and that dorsal and ventral parietal cortex have distinct functions within episodic memory, as well as overlapping activity for memory and perception [43, 44]. One functional MRI study [45] using a verbal incidental memory task in healthy individuals, found that activity in the right inferior parietal and prefrontal networks was modulated by the level of attention during initial encoding. Although the functional role of the parietal cortex is complex and still debated [46, 47], it is possible that our incidental memory task put more demand on retrieval after spontaneous 'on-line processing', and thus tapped parietal-driven attentive and mnemonic functions. The visual nature of the task items could also explain some of the right hemispheric lateralization. Functional imaging evidence has shown right lateralization effects for visual items [48]. Within working-memory paradigms, right inferior parietal activity has been associated with memory for object location [49] and visuo-spatial imagery strategies to maintain information in short-term memory [50]. Although none of our visual free recall measures were directly associated with working memory performance, the visual content in the incidental memory task may have required subjects to rely more on visual imagery strategies instead of lexical-semantic search in order to access content from memory during free recall. Visuo-perceptual aspects of the incidental memory task could also contribute to the present parietal finding in PD patients. However, this seems less likely as the other very similar visual memory task was not related to gray matter volume and neither of the visual memory tasks were directly associated with visuospatial performances.

Due to the fixed setting in our study, it is not possible to definitively untangle whether the observed gray matter association was related to encoding or to retrieval. However, the fact that gray matter volume in

PD patients was associated only with free recall following incidental encoding suggests that the finding was related to differences in the encoding conditions, and that different memory tasks may be differently reflected in gray matter volume. The lack of association between hippocampal gray matter volume and any of our memory measures suggests a non-dominant role of the hippocampal circuit in the free recall deficit seen in early PD. However, early stage functional disruptions of the hippocampus cannot be excluded by structural imaging, and VBM might not be an optimal method for analyzing small subcortical structures like hippocampus. It has been suggested, that surface-based neuroanatomical approaches such as cortical folding and cortical thickness may be more sensitive methods than VBM to identify subtle changes [36]. Functional brain imaging studies on free recall could contribute to the understanding of memory in PD from early stages and prior to overt symptoms of hippocampal atrophy.

We are aware of some limitations of the study. First, the study sample was rather small, which may affect the generalizability of the findings. Second, there were some differences between the incidental and intentional free recall tasks used, which warrants further studies in counterbalanced experimental settings for establishing the effects of intentionality. Third, we did not perform a subgrouping of PD patients according to cognitive status. Instead, we restricted the sample to early stage, short disease duration PD already at the inclusion phase of the study. A majority of studies reporting anatomical correlates of memory in PD have included older ( $\geq 65$  years) PD patients with longer disease durations ( $\geq 5$  years) [1, 4, 5, 9, 16]. Studies including younger patients at initial disease stages may therefore contribute to the understanding of the neural changes associated with memory at different stages of PD.

In conclusion, we found that smaller right parietal gray matter volume in early stage PD was related to worse free recall on an incidental visual memory task, but we found no associations between gray matter volume and conventional visual and verbal memory tasks. While both cortical and subcortical neural networks are thought to be involved in both intentional and incidental memory in healthy humans, further studies are needed to establish the role of brain volumetric degeneration in free recall deficits in early PD.

#### ACKNOWLEDGMENTS

This work was supported by funds from the Waldemar von Frenckell Foundation, the Jan-Magnus

Jansson Foundation for Geriatric and Elderly Care Research, the Abo Akademi Foundation, the Medical Society of Finland, the Finnish Parkinson Foundation, the Finnish National Doctoral Programme of Psychology (U. Ellfolk), Clinical Grants (EVO) of Turku University Hospital, and the Sigrid Juselius Foundation (J.O. Rinne). We would like to thank the patients and healthy volunteers who participated in this study, and the staff at the Finnish Parkinson Association, and MD Harri Hirvonen for assistance in patient recruitment.

### CONFLICT OF INTEREST

The authors have no conflict of interest to report.

### REFERENCES

- [1] Weintraub D, Doshi J, Koka D, Davatzikos C, Siderow AD, Duda JE, Wolk DA, Moberg PJ, Xie SX, & Clark CM (2011) Neurodegeneration across stages of cognitive decline in Parkinson disease. *Arch Neurol*, **68**, 1562-1568.
- [2] Song SK, Lee JE, Park H-J, Sohn YH, Lee JD, & Lee PH (2011) The pattern of cortical atrophy in patients with Parkinson's disease according to cognitive status. *Mov Disord*, **26**, 289-296.
- [3] Summerfield C, Junqué C, Tolosa E, Salgado-Pineda P, Gómez-Ansón B, Martí MJ, Pastor P, Ramirez-Ruiz B, & Mercader J (2005) Structural brain changes in Parkinson disease with dementia: A voxel-based morphometry study. *Arch Neurol*, **62**, 281-285.
- [4] Nishio Y, Hirayama K, Takeda A, Hosokai Y, Ishioka T, Suzuki K, Itoyama Y, Takahashi S, & Mori E (2010) Corticolimbic gray matter loss in Parkinson's disease without dementia. *Eur J Neurol*, **17**, 1090-1097.
- [5] Pagonabarraga J, Corcuera-Solano I, Vives-Gilbert Y, Llebaria G, García-Sánchez C, Pascual-Sedano B, Delfino N, Kulisevsky J, & Gómez-Ansón B (2013) Pattern of regional cortical thinning associated with cognitive deterioration in Parkinson's disease. *PLoS One* **8**, e54980. doi: 10.1371/journal.pone.0054980
- [6] Brück A, Kurki T, Kaasinen V, Vahlberg T, & Rinne JO (2004) Hippocampal and prefrontal atrophy in patients with early non-demented Parkinson's disease is related to cognitive impairment. *J Neurol Neurosurg Psychiatry*, **75**, 1467-1469.
- [7] Jokinen P, Brück A, Aalto S, Forsback S, Parkkola R, & Rinne JO (2009) Impaired cognitive performance in Parkinson's disease is related to caudate dopaminergic hypofunction and hippocampal atrophy. *Parkinsonism Relat Disord*, **15**, 88-93.
- [8] Ibarretxe-Bilbao N, Ramírez-Ruiz B, Tolosa E, Martí MJ, Valldeoriola F, Bargalló N, Junqué (2008) Hippocampal head atrophy predominance in Parkinson's disease with hallucinations and with dementia. *J Neurol*, **255**, 1324-1331.
- [9] Filoteo JV, Reed JD, Litvan I, & Harrington DL (2013) Volumetric correlates of cognitive functioning in nondemented patients with Parkinson's disease. *Mov Disord*. doi: 10.1002/mds.25633
- [10] Martin WRW, Wieler M, Gee M, & Camicioli R (2009) Temporal lobe changes in early, untreated Parkinson's disease. *Mov Disord*, **24**, 1949-1954.
- [11] Dalaker TO, Zivadinov R, Larsen JP, Beyer MK, Cox JL, Alves G, Bronnick K, Tysnes O-B, Antulov R, Dwyer MG, & Aarsland D (2010) Gray matter correlations of cognition in incident Parkinson's disease. *Mov Disord*, **25**, 629-633.
- [12] Tinaz S, Courtney MG, & Stern CE (2011) Focal cortical and subcortical atrophy in early Parkinson's disease. *Mov Disord*, **26**, 436-441.
- [13] Brønnick K, Alves G, Aarsland D, Tysnes O-B, & Larsen (2011) Verbal memory in drug-naive, newly diagnosed Parkinson's disease. The retrieval deficit hypothesis revisited. *Neuropsychology*, **25**, 114-124.
- [14] Muslimovic D, Post B, Speelman JD, & Schmand B (2005) Cognitive profile of patients with newly diagnosed Parkinson disease. *Neurology*, **65**, 1239-1245.
- [15] Elgh E, Domellöf M, Linder J, Edström M, Stenlund H, & Forsgren L (2009) Cognitive function in early Parkinson's disease: A population-based study. *Eur J Neurol*, **16**, 1278-1284.
- [16] Beyer MK, Bronnick KS, Hwang KS, Bergsland N, Tysnes OB, Larsen JP, Thompson PM, Somme JH, & Apostolova LG (2013) Verbal memory is associated with structural hippocampal changes in newly diagnosed Parkinson's disease. *J Neurol Neurosurg Psychiatry*, **84**, 23-28.
- [17] Pause BM, Zlomuzica A, Kinugawa K, Mariani J, Pietrowsky R, & Dere E (2013) Perspectives on episodic-like and episodic memory. *Front Behav Neurosci* **7**, 33. doi: 10.3389/fnbeh.2013.00033
- [18] Tomlinson CL, Stowe R, Patel S, Rick C, Gray R, & Clarke CE (2010) Systematic review of levodopa dose equivalency reporting in Parkinson's disease. *Mov Disord*, **25**, 2649-2653.
- [19] Emre M, Aarsland D, Brown R, Burn DJ, Duyckaerts C, Mizuno Y, Broe GA, Cummings J, Dickson DW, Gauthier S, Goldman J, Goetz C, Kerczyn A, Lees A, Levy R, Litvan I, McKeith I, Olanow W, Poewe W, Quinn N, Sampaio C, Tolosa E, & Dubois B (2007) Clinical diagnostic criteria for dementia associated with Parkinson's disease. *Mov Disord*, **22**, 1689-1707.
- [20] Portin R, Saarijärvi S, Joukamaa M, & Salokangas RK (1995) Education, gender and cognitive performance in a 62-year-old normal population: Results from the Turva Project. *Psychol Med*, **25**, 1295-1298.
- [21] Karrasch M, Myllyniemi A, Latvasalo L, Söderholm C, Ellfolk U, & Laine M (2010) The diagnostic accuracy of an incidental memory modification of the Boston Naming Test (memo-BNT) in differentiating between normal aging and mild Alzheimer's disease. *Clin Neuropsychol*, **24**, 1355-1364.
- [22] Laine M, Koivuselkä-Sallinen P, Hänninen R, & Niemi J (1997) *Bostonin Nimeämistesti. Suomenkielinen versio [Boston Naming Test. Finnish version]*, Psykologien Kustannus Oy, Helsinki.
- [23] Welsh KA, Butters N, Mohs RC, Beekly D, Edland S, & Fillenbaum G, et al, The Consortium to Establish a Registry for Alzheimer's Disease (CERAD) (1994) Part V. A normative study of the neuropsychological battery. *Neurology*, **44**, 609-614.
- [24] Hänninen T, Pulliainen V, Sotaniemi M, Hokkanen L, Salo J, Hietanen M, Pirttilä T, Pöyhönen M, Juva K, Remes A, & Erkinjuntti T (2010) [Early detection of cognitive changes in memory diseases: New cut-off scores for the Finnish version of CERAD neuropsychological battery]. *Duodecim*, **126**, 2013-2021.
- [25] Kudlicka A, Clare L, & Hindle JV (2011) Executive functions in Parkinson's disease: Systematic review and meta-analysis. *Mov Disord*, **26**, 2305-2315.
- [26] Lewis SJG, Slabosz A, Robbins TW, Barker RA, & Owen AM (2005) Dopaminergic basis for deficits in working memory but not attentional set-shifting in Parkinson's disease. *Neuropsychologia*, **43**, 823-832.



- [27] Higginson CI, King DS, Levine D, Wheelock VL, Khamphay NO, & Sigvardt KA (2003) The relationship between executive function and verbal memory in Parkinson's disease. *Brain Cogn*, **52**, 343-352.
- [28] Wahlund LO, Barkhof F, Fazekas F, Bronge L, Augustin M, Sjogren M, Wallin A, Ader H, Leys D, Pantoni L, Pasquier F, Erkinjuntti T, & Scheltens P, European Task Force on Age-related White Matter, Changes (2001) A New Rating Scale for Age-Related White Matter Changes Applicable to MRI and CT. *Stroke*, **32**, 1318-1322.
- [29] Scheltens P, Leys D, Barkhof F, Huglo D, Weinstein HC, Vermersch P, Kuiper M, Steinling M, Wolters EC, & Valk J (1992) Atrophy of medial temporal lobes on MRI in "probable" Alzheimer's disease and normal ageing: Diagnostic value and neuropsychological correlates. *J Neurol Neurosurg Psychiatry*, **55**, 967-972.
- [30] Ashburner J, & Friston KJ (2005) Unified segmentation. *Neuroimage*, **26**, 839-851.
- [31] Ashburner J (2007) A fast diffeomorphic image registration algorithm. *Neuroimage*, **38**, 95-113.
- [32] Ashburner J, & Friston KJ (2000) Voxel-based morphometry—the methods. *Neuroimage*, **11**, 805-821.
- [33] Maldjian JA, Laurienti PJ, Kraft RA, & Burdette JH (2003) An automated method for neuroanatomic and cytoarchitectonic atlas-based interrogation of fMRI data sets. *Neuroimage*, **19**, 1233-1239.
- [34] Melzer TR, Watts R, MacAskill MR, Pitcher TL, Livingston L, Keenan RJ, Dalrymple-Alford JC, & Anderson TJ (2012) Grey matter atrophy in cognitively impaired Parkinson's disease. *J Neurol Neurosurg Psychiatry*, **83**, 188-194.
- [35] Agosta F, Canu E, Stojković T, Pievani M, Tomić A, Sarro L, Dragašević N, Copetti M, Comi G, Kostić VS, & Filippi M (2012) The topography of brain damage at different stages of Parkinson's disease. *Hum Brain Mapp*. doi: 10.1002/hbm.22101
- [36] Pereira JB, Ibarretxe-Bilbao N, Marti M-J, Compta Y, Junqué C, Bargallo N, & Tolosa E (2012) Assessment of cortical degeneration in patients with Parkinson's disease by voxel-based morphometry, cortical folding, and cortical thickness. *Hum Brain Mapp*, **33**, 2521-2534.
- [37] Squire LR, Stark CEL, & Clark RE (2004) The medial temporal lobe. *Annu Rev Neurosci*, **27**, 279-306.
- [38] Pereira JB, Junqué C, Martí M-J, Ramirez-Ruiz B, Bargallo N, & Tolosa E (2009) Neuroanatomical substrate of visuospatial and visuo-perceptual impairment in Parkinson's disease. *Mov Disord*, **24**, 1193-1199.
- [39] Corbetta M, & Shulman GL (2002) Control of goal-directed and stimulus-driven attention in the brain. *Nat Rev Neurosci*, **3**, 201-215.
- [40] Cabeza R, & Nyberg L (2000) Imaging cognition II: An empirical review of 275 PET and fMRI studies. *J Cogn Neurosci*, **12**, 1-47.
- [41] Cabeza R, Ciaramelli E, Olson IR, & Moscovitch M (2008) The parietal cortex and episodic memory: An attentional account. *Nat Rev Neurosci*, **9**, 613-625.
- [42] Wagner AD, Shannon BJ, Kahn I, & Buckner RL (2005) Parietal lobe contributions to episodic memory retrieval. *Trends Cogn Sci*, **9**, 445-453.
- [43] Cabeza R, Mazuz YS, Stokes J, Kragel JE, Woldorff MG, Ciaramelli E, Olson IR, & Moscovitch M (2011) Overlapping parietal activity in memory and perception: Evidence for the attention to memory model. *J Cogn Neurosci*, **23**, 3209-3217.
- [44] Cabeza R, Ciaramelli E, & Moscovitch M (2012) Cognitive contributions of the ventral parietal cortex: An integrative theoretical account. *Trends Cogn Sci*, **16**, 338-352.
- [45] Christensen TA, Almryde KR, Fidler LJ, Lockwood JL, Antonucci SM, & Plante E (2012) Modulating the focus of attention for spoken words at encoding affects frontoparietal activation for incidental verbal memory. *Int J Biomed Imaging* **2012**, 579786. doi: 10.1155/2012-579786
- [46] Singh-Curry V, & Husain M (2009) The functional role of the inferior parietal lobe in the dorsal and ventral stream dichotomy. *Neuropsychologia*, **47**, 1434-1448.
- [47] Levy DA (2012) Towards an understanding of parietal mnemonic processes: Some conceptual guideposts. *Front Integr Neurosci* **6**, 41. doi: 10.3389/fnint.2012.00041.
- [48] Nagel BJ, Herting MM, Maxwell EC, Bruno R, & Fair D (2013) Hemispheric lateralization of verbal and spatial working memory during adolescence. *Brain Cogn*, **82**, 58-68.
- [49] Rottschy C, Langner R, Dogan I, Reetz K, Laird AR, Schulz JB, Fox PT, & Eickhoff SB (2012) Modelling neural correlates of working memory: A coordinate-based meta-analysis. *Neuroimage*, **60**, 830-846.
- [50] Salmon E, Van der Linden M, Collette F, Delfiore G, Maquet P, Degueldre C, Luxen A, & Franck G (1996) Regional brain activity during working memory tasks. *Brain*, **119**(Pt 5), 1617-1625.